

Catheter Ablation of Atrial Fibrillation

Thomas D. Callahan IV, MD^a, Luigi Di Biase, MD^{a,b},
Rodney Horton, MD^c, Javier Sanchez, MD^c,
Joseph G. Gallinghouse, MD^c, Andrea Natale, MD, FACC, FHRS^{c,d,e,f,*}

KEYWORDS

- Catheter ablation • Atrial fibrillation
- Pulmonary veins • Atrioventricular node ablation
- Antiarrhythmic drugs • Rate control • Rhythm control

Atrial fibrillation is a common arrhythmia associated with significant morbidity, including angina, heart failure, and stroke. Medical therapy remains suboptimal, with significant side effects and toxicities, and a high recurrence rate. Catheter ablation or modification of the atrioventricular node with pacemaker implantation provides rate-control, but exposes patients to the hazards associated with implantable devices and does nothing to reduce the risk for stroke. Pulmonary vein antrum isolation offers a nonpharmacologic means of restoring sinus rhythm, thereby eliminating the morbidity of atrial fibrillation and the need for antiarrhythmic drugs.

Atrial fibrillation is a common arrhythmia associated with significant morbidity. It is the most common sustained arrhythmia and affects millions of Americans. The lifetime risk for development of atrial fibrillation is estimated at one in four for persons older than 40 years.¹ Atrial fibrillation contributes to the development of angina, heart failure, and stroke, with an estimated stroke risk of 3% to 5% per year in untreated individuals.^{2,3} Furthermore, analysis of Framingham data suggests the mortality rate in patients who have atrial fibrillation is increased 1.5- to 2-fold compared with the general population.^{4,5} Medical therapy for atrial fibrillation remains suboptimal and plagued by significant toxicities and frequent side effects and

intolerance. Recurrence rates with medical therapy are estimated to occur in 50% of patients at 6 to 36 months.⁶

Whether or not restoration of sinus rhythm should be a goal of therapy is a matter of debate in the literature. Several trials, including the Atrial Fibrillation Follow-Up Investigation of Rhythm Management (AFFIRM) trial, report no benefit of rhythm control over rate control in the treatment of atrial fibrillation.^{7,8} These trials, however, examined pharmacologic rhythm control strategies. Further analysis of the AFFIRM data showed that the presence of atrial fibrillation was associated with a 47% increased mortality compared with sinus rhythm. Use of an antiarrhythmic medication was associated with a 49% increased mortality, suggesting that any mortality benefit from maintenance of sinus rhythm was offset by increased mortality from currently available antiarrhythmics.⁹ Catheter ablation for atrial fibrillation offers a nonpharmacologic means of restoring sinus rhythm and improves mortality and quality of life compared with antiarrhythmic drugs.^{10,11}

FUNDAMENTALS OF RADIOFREQUENCY CATHETER ABLATION

In 1979, Vedel and coauthors¹² reported complete heart block after multiple attempts at direct current

A version of this article originally appeared in the *Medical Clinics of North America*, volume 92, issue 1.

^a Cardiac Pacing and Electrophysiology, Cleveland Clinic Cleveland, OH, USA

^b Department of Cardiology, University of Foggia, Foggia, Italy

^c Texas Cardiac Arrhythmia Institute at St. David's Medical Center, Austin, TX; USA

^d Case Western Reserve University, Cleveland, OH, USA

^e Division of Cardiology, Stanford University, Stanford, CA, USA

^f California Pacific Medical Center Atrial Fibrillation and Arrhythmia Program, San Francisco, CA, USA

* Corresponding author. 1015 East 32 Street, Suite 516, Austin, TX 78705, USA.

E-mail address: dr.natale@gmail.com (A. Natale).

Cardiol Clin 27 (2009) 163–178

doi:10.1016/j.ccl.2008.09.004

0733-8651/08/\$ – see front matter © 2009 Elsevier Inc. All rights reserved.

cardioversion while a recording catheter was positioned at the bundle of His. The investigators hypothesized that current shunting through the recording catheter injured the conduction system, leading to heart block. Subsequently, percutaneous catheter ablation for treatment of cardiac arrhythmias was developed and, in the infancy of this technique, atrial fibrillation was among the first arrhythmias treated. Patients who had atrial fibrillation and rapid ventricular rates refractory to medical therapy were offered ablation of the atrioventricular (AV) node using high-energy direct current delivered to the region of the AV junction.^{13,14} Although effective, this technique was associated with a high rate of life-threatening complications.¹⁵

Use of radiofrequency energy in catheter ablation was found to improve efficacy of ablation and the safety profile, and quickly supplanted direct current catheter ablation.^{16–18} Radiofrequency catheter ablation delivers an alternating current, typically at frequencies of approximately 500 kHz, which generates myocardial lesions through thermal injury. Current disperses radially from the delivery electrode to a dispersive electrode placed on the skin, with impedance, voltage drop, and power dissipation greatest at the interface of the electrode and tissue. Heating of the tissue in close contact to the delivery electrode is caused by resistance as current passes through, and is referred to as *direct heating*. Thermal energy from this area is transferred back to the delivery electrode and the surrounding tissue through conduction. Conductive or indirect heating accounts for a larger volume of thermal injury in the radiofrequency ablation lesion than does resistive or direct heating. Temperature rise is rapid in the zone of resistive heating and immediately adjacent areas; however, temperature rise is slower as the distance from this area increases, and can continue to rise at remote sites even after delivery of current has ceased.¹⁹

Lesion size is influenced by several factors. Increasing the length or diameter of the delivery electrode, the contact area, and the source power all result in a larger radius of direct heating and, thus larger lesion size. Circulating blood results in convective cooling. Although convective cooling within the tissue limits lesion size, cooling of the catheter tip through convection allows improved power delivery, which increases lesion size and allows for more rapid lesion formation. Although lesion size is proportional to the peak temperature achieved, at temperatures of 100°C and above, char and coagulum form and can increase impedance dramatically.¹⁹ Within the tissue, temperatures in excess of 100°C cause the sudden

production of steam, which can lead to an explosive venting to the endocardial or epicardial surface, called a *pop*.

Convective cooling of the tissue–catheter interfaces caused by circulating blood and, when used, with irrigation of the catheter tip may cause temperatures at this interface to be lower than peak tissue temperatures achieved within the tissue. As a result, thermal sensors in the catheter tip often underestimate peak in-lesion temperatures. The authors have found that with nonirrigated catheter tips, measured temperature is not reliable and instead microbubble monitoring with intracardiac echocardiography is a more effective strategy for regulation of energy delivery.²⁰ Because microbubble monitoring is not feasible with open-tip irrigated catheters, tissue disruption is minimized with careful limitation of the maximum temperature and power and monitoring of the impedance.

ATRIOVENTRICULAR NODE ABLATION

Overview

Like medical therapy for atrial fibrillation, catheter ablation for atrial fibrillation can be divided into two general strategies: rate control and rhythm control. Within the field of catheter ablation, rate can be controlled through modifying the AV node or ablating the node and implanting a permanent pacemaker. Curative catheter ablation achieves rhythm control through targeting the triggers of atrial fibrillation, restoring sinus rhythm, and preventing future recurrences.

The technique of AV node ablation predated the development of curative ablation techniques for atrial fibrillation. AV node modification targets the slow pathway, resulting in increased AV node refractoriness and slower ventricular rates without causing AV block. This technique is used rarely, because complete heart block is common and malignant ventricular arrhythmias can be seen after the procedure. AV node ablation does not cure atrial fibrillation and requires placement of a permanent pacemaker to ensure adequate ventricular rates. Ideally, the most proximal portion of the AV node is targeted, leaving the distal portion intact, resulting in complete heart block. Although this is the desired result of the procedure, it maximizes the likelihood of leaving patients with an escape rhythm, which is desirable if a pacemaker malfunction occurs. Because of its many limitations, including the requirement of a permanent pacemaker and the failure to address the long-term risk for stroke, and given the possible benefits of restoring sinus rhythm, AV node ablation is restricted primarily to patients refractory to

medical therapy and who have contraindications to curative atrial fibrillation ablation, such as significant comorbidities and poor life expectancy.

Techniques

Before AV node ablation, pacing of the ventricle should be ensured. This function can be achieved through implanting a permanent pacemaker before AV node ablation or placing a temporary transvenous pacemaker before ablation and then implanting a permanent pacemaker immediately after the procedure. The first strategy has the advantage of allowing any possible postimplantation device malfunctions to be addressed before AV node ablation. Placing a dual-chamber pacemaker with mode switching capabilities allows for AV synchrony during sinus rhythm or atrial pacing.

Ablation of the AV node usually is performed through the right side of the heart, with radiofrequency ablation most often used. However, in approximately 5% to 10% of cases, the AV node can be ablated only through the left side of the heart, necessitating arterial access and a retrograde approach to apply lesions below the aortic valve.²¹ Use of cryoablation is described but does not seem to offer benefit over radiofrequency ablation.²² Typically, the His bundle is identified, and the ablation catheter is then withdrawn toward the right atrium to a site that shows an atrial-to-ventricular electrogram ratio of 1:1 to 1:2 and a small His signal (**Fig. 1**). Care should be taken to map adequately and ensure catheter stability, because ineffective lesions may result in edema without successful ablation. This complication may make successful ablation more difficult

through obscuring electrograms and increasing the distance to the target tissue. Effective lesions at an appropriate target site often induce an accelerated junctional rhythm early in the radiofrequency application, which subsequently resolves to a slower junctional or ventricular escape as radiofrequency application continues.

Outcomes and Limitations

Success rates for AV node ablation are near 100%.^{23–27} The procedure improves quality of life and may improve left ventricular ejection fraction modestly, probably from improved rate control.^{23,24,28–30} In addition to these benefits, AV node ablation usually can be performed quickly, which may be advantageous for patients unable to endure more protracted ablation procedures. Additionally, the procedure typically can be performed entirely from the right side of the heart, and thus does not require systemic intraoperative anticoagulation and essentially eliminates the risk for thromboembolic complications. After AV node ablation, a high risk for malignant ventricular arrhythmias is present. This risk is eliminated by programming a lower rate of at least 80 to 90 beats per minute for the first 4 to 8 weeks postprocedure.^{29,31}

AV node ablation for the treatment of atrial fibrillation has several key limitations. Patients who do not have contraindications must continue on anticoagulation therapy to minimize risk for the cardioembolic complications of atrial fibrillation. Furthermore, patients may continue to have symptoms from atrial fibrillation, such as shortness of breath, despite regularization of the ventricular rhythm with pacing. In addition, patients are

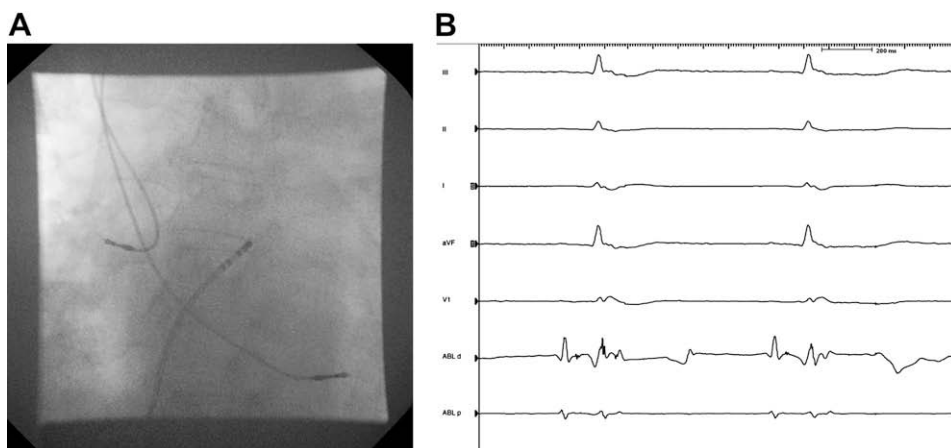


Fig. 1. Fluoroscopy (A) and intracardiac electrograms (B) showing satisfactory catheter position for AV node ablation. The ablation catheter (ABL) is positioned in the region of the slow pathway with approximately equal A and V amplitudes on the distal ablation channel (ABLd) of the intracardiac electrogram. Pacemaker leads are seen in the right atrium (RA) and right ventricle (RV).

exposed to the associated risks for an indwelling cardiac device, including the risk for infection and chronic right ventricular pacing.³² Patients who have a history of congestive heart failure benefit from biventricular pacing after AV node ablation. No evidence, however, suggests that chronic biventricular pacing in the general population is equivalent to native conduction through the His–Purkinje system.³³ In fact, preliminary results from a randomized study³⁴ showed better improvement in symptoms, quality of life, and ejection fraction among patients who had congestive heart failure who underwent atrial fibrillation ablation than in those treated with AV node ablation and cardiac resynchronization therapy devices.

CURATIVE CATHETER ABLATION FOR ATRIAL FIBRILLATION

Background and Overview

Catheter ablation techniques aimed at curing atrial fibrillation rather than simply controlling the ventricular response target the triggers and substrate of atrial fibrillation. Curative catheter ablation techniques initially attempted to mimic the lesions created by the surgical Maze procedure.^{35–37} In 1998, Haissaguerre and colleagues³⁸ described focal firing as an important source of ectopic beats, which could lead to atrial fibrillation, and reported that these foci respond to ablation. Experts believe that as many as 94% of these triggers originate from the pulmonary veins.³⁹ This finding led to focal ablation within the pulmonary veins to eliminate these triggers.

Further studies propelled the evolution of the technique to the circumferential isolation of the pulmonary veins, which has since become the cornerstone of curative atrial fibrillation ablation. Patients who have paroxysmal atrial fibrillation and a structurally normal heart may expect a high rate of cure from isolation of the pulmonary veins alone. This outcome represents, however, a small number of patients who have atrial fibrillation presenting for ablation. Most patients, especially those who have dilated or scarred atria and chronic atrial fibrillation, do not have the same rate of cure with simple isolation of the pulmonary veins.⁴⁰

Areas of focal firing outside the pulmonary veins in the left and right atria also initiate atrial fibrillation.⁴¹ Ablation of additional triggers outside the pulmonary veins and addition of lesions to interrupt the maintenance of atrial fibrillation may be required to improve long-term success in these substrate modification populations. These adjunctive lesion sets have

become an integral component of curative atrial fibrillation ablation for most patients.

More recently, ablation targeting complex fragmented atrial electrograms (CFAEs) has been shown to result in sinus rhythm maintenance in approximately 80% of patients who had paroxysmal and persistent atrial fibrillation. However, these results originated from a single center and have not been replicated by other investigators.⁴²

Current techniques for curative atrial fibrillation ablation can be categorized broadly as anatomic ablation or electrogram-guided isolation. Anatomic ablation currently relies on electroanatomic mapping systems to create a three-dimensional representation of the left atrium and pulmonary veins. The position of the ablation catheter can be visualized within this representation, and the location of ablation points marked with respect to the anatomy. Ablation lesions are placed circumferentially around the pulmonary veins, individually or often encircling two ipsilateral pulmonary veins simultaneously. Local electrograms can be measured from the ablation catheter and can help determine the duration of each lesion. Careful inspection for gaps allowing persistent conduction between the left atrium and the pulmonary veins is not performed, however. Persistent conduction between the pulmonary veins and left atrium can be shown in up to 60% of the pulmonary veins after anatomic ablation.^{43,44}

In contrast to this technique, electrogram-guided isolation relies on a second mapping catheter with a ring-shaped array of electrodes. This array is placed at the ostium of each pulmonary vein during isolation. In the authors' approach, lesions are delivered circumferentially around the antrum of each individual pulmonary vein, and the ring catheter is used to interrogate the circumference of the pulmonary vein antra to find gaps that can be closed (**Fig. 2**). Electrogram guidance of pulmonary vein antrum isolation (PVAI) improves long-term success compared with a purely anatomic approach.^{43,45}

Patient Selection

As with any invasive procedure, patient selection is critical to optimizing the safety and success of PVAI. Although some data suggest increased mortality associated with atrial fibrillation and antiarrhythmic medications, much more study is required to elucidate the magnitude of these risks and the impact PVAI might have on them. Therefore, the diagnosis of atrial fibrillation alone is not sufficient to warrant PVAI. Furthermore, PVAI, like all invasive procedures, carries inherent risks that may be increased by patient age and

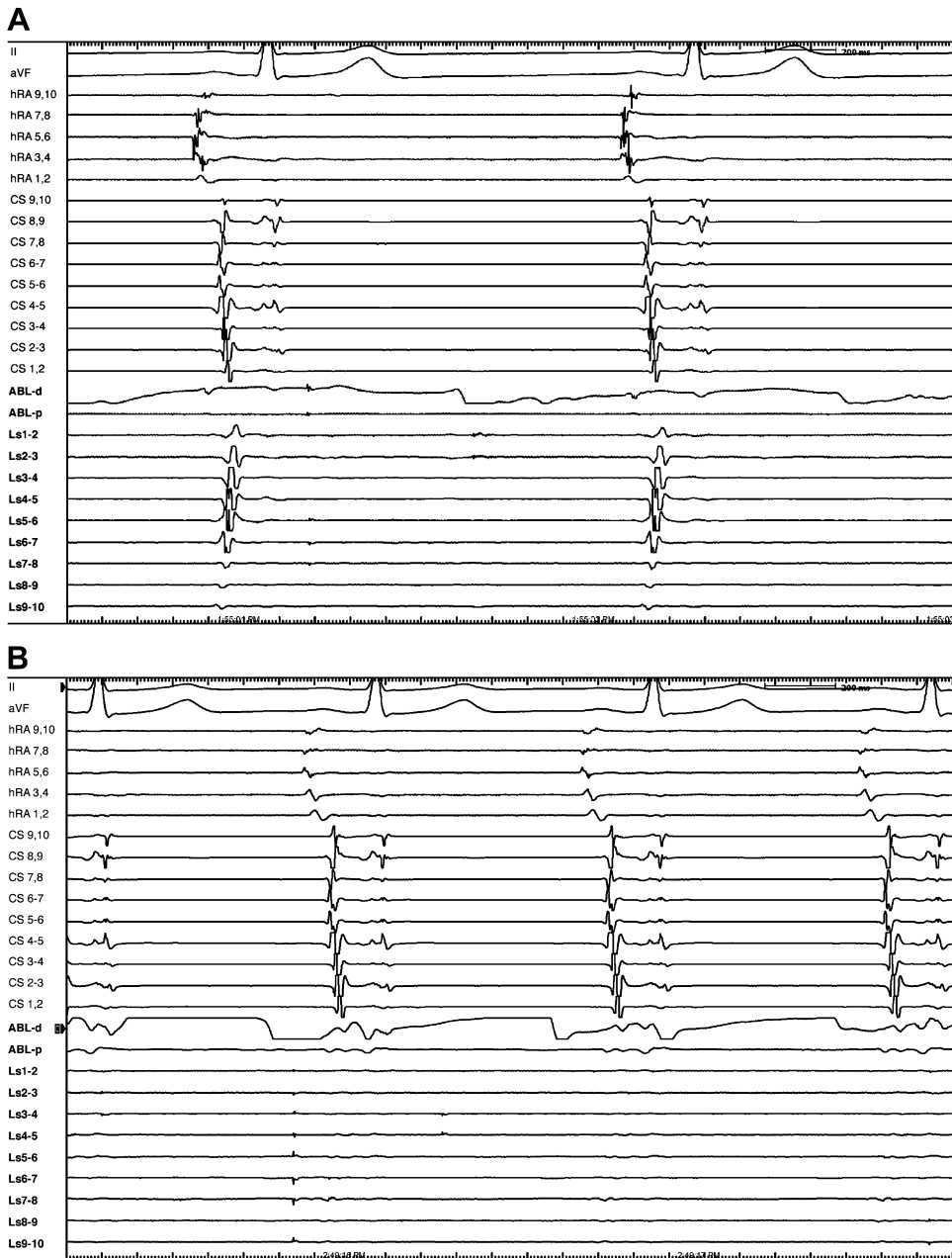


Fig. 2. Intracardiac electrograms showing potentials within the right inferior pulmonary vein preisolation (A) and absence of potentials on the mapping ring catheter (LS 1–10) postisolation (B).

comorbidities. Finally, patient features have been shown to impact the likelihood of success. All of these factors play an important role in determining the appropriateness of PVAI.

Although some data suggest that PVAI may be superior to medical therapy for first-line therapy of atrial fibrillation, current guidelines recommend that, in most patients, treatment with at least one antiarrhythmic drug be tried and fail before atrial fibrillation ablation is considered.⁴⁶

Current indications include symptomatic atrial fibrillation refractory to or intolerant of medical therapy. Additionally, patients in whom anticoagulation is indicated secondary to atrial fibrillation, but who cannot tolerate or whose occupations or activities preclude long-term anticoagulation, may be considered candidates for PVAI regardless of the presence of symptoms. Finally, patients who desire not to take antiarrhythmics or long-term anticoagulation sometimes are considered for PVAI.

PVAI should not be considered for any patients who cannot reasonably be expected to tolerate the procedure. For instance, patients who have severe dementia or decompensated heart failure are unlikely to be able to endure a potentially long procedure that requires their cooperation and for them to remain supine. Because the procedure requires aggressive intraoperative anticoagulation, active bleeding or a history of a severe bleeding diathesis is a contraindication. Patients in persistent or permanent atrial fibrillation should not undergo PVAI if they would not be considered candidates for cardioversion. Adequate anticoagulation of sufficient duration should be ensured just as it would be before cardioversion. If patients have a history of prior ablations or open heart surgery, structural abnormalities such as pulmonary vein stenosis should be ruled out. Congenital heart defects, including repaired atrial septal defects, can add to the technical difficulty but they not absolute contraindications if the procedure is performed in centers where clinicians are experienced in the technique.⁴⁷

Certain patient features are found to be associated with increased or decreased likelihood of success and may help in patient selection and counseling. Patients who have atrial fibrillation that is shorter in duration and paroxysmal and those who have normal-sized atria are more likely to have their atrial fibrillation cured by PVAI. Conversely, patients who have long-standing, permanent atrial fibrillation and those who have dilated atria or known atrial scarring are less likely to experience complete cure after PVAI.^{48,49}

The preoperative assessment should include a careful history and physical examination. Patients who have allergies to intravenous contrast dye should be prepared according to standard procedures. Many operators obtain preoperative CT scan or MRI optimized for imaging of the pulmonary veins before PVAI; however, this is not absolutely necessary unless patients have a history of an ablation in the left heart. Antiarrhythmic medications can suppress spontaneous firing and fractionation of the electrograms used to guide ablation.

Therefore, antiarrhythmic medications should be discontinued with approximately a five half-life washout period before the procedure (a longer period around 6 months is required for amiodarone). Continued full anticoagulation with warfarin therapy could decrease the risk for periprocedure thromboembolic events and is not interrupted for PVAI.⁵⁰ Patients not previously on chronic anticoagulation are started on warfarin, with a goal international normalized ratio of two to three, at least 3 weeks before PVAI, and this is

continued for at least 3 to 6 months after the procedure. Patients must remain in a fasting state before the procedure and should be instructed to expect an overnight hospital admission for observation after the procedure.

Technical Aspects

Pulmonary veins are approached using a transeptal approach, necessitating multiple venous sheaths for the delivery of catheters. Transeptal catheters are delivered through sheaths typically placed in the right femoral vein. Additionally, an intracardiac echocardiogram (ICE) probe may be introduced through the left or right femoral vein. Placement of a coronary sinus catheter provides an additional fluoroscopic landmark to guide catheter positioning and is used as a reference point for certain electroanatomic mapping systems. Additionally, a coronary sinus catheter may help differentiate left- versus right-sided arrhythmogenic triggers.⁵¹ This device typically is placed through the right internal jugular vein or through the right subclavian vein.

Electrogram-guided ablation requires an ablation and a mapping catheter be placed into the left atrium; thus, two transeptal sheaths are needed. Fluoroscopic and ICE visualization of the transeptal needle and the anatomic landmarks should guide transeptal puncture. Care must be taken to ensure that punctures are performed through the inferior interatrial septum, where it is thinner and easier to cross than the more muscular superior septum. Additionally, placing transeptal puncture posteriorly places the catheters close to the posterior left atrium and the pulmonary veins, facilitating reach of the catheters to these targets (**Fig. 3**). Before the transeptal puncture, unfractionated heparin should be bolused and

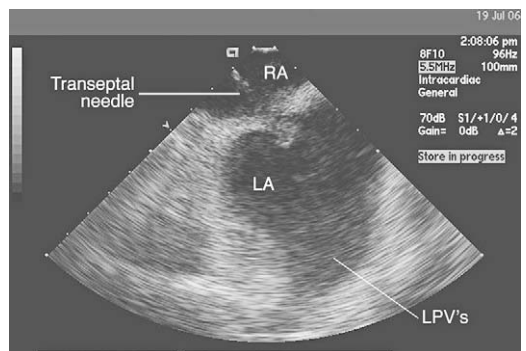


Fig. 3. ICE showing tenting of the intra-atrial septum with the transeptal needle at a satisfactory location on the septum across from the left pulmonary veins (LPV's). The right atrial (RA) and left atrial (LA) are shown.

a drip initiated. A target activated clotting time of 350 to 400 seconds is used at the authors' institution and decreases perioperative thromboembolic events compared with lower targets.⁵²

The muscular sleeves of the pulmonary veins are the most common site of triggers of atrial fibrillation.^{38,39} Although early approaches used focal lesions within individual pulmonary veins to ablate these foci, they were associated with an increased rate of pulmonary vein stenosis and higher rates of recurrence compared with circumferential isolation.^{53,54} Discrete electrical connections between the left atrium and the pulmonary veins often can be identified; however, a segmental approach that targets only these connections has a higher rate of recurrence than circumferential techniques.^{39,55–58}

Occasionally, individual pulmonary veins may be identified as the triggers of atrial fibrillation in a given patient. It may be tempting to isolate only the veins identified as harboring triggers in these cases. Failure to isolate all the pulmonary veins, however, yields a lower long-term success rate and, if attempted at all, probably should be reserved for younger patients.^{59–61} Purely anatomic ablation is associated with a high incidence of persistent conduction between the pulmonary veins and left atrium and is associated with rates of success inferior to electrogram-guided isolation.^{43–45} Thus, the authors believe that electrogram-guided isolation is preferred over anatomic techniques.

Although it is known that most triggers of atrial fibrillation arise from the muscular sleeves of the pulmonary veins, the junction of the pulmonary veins with the left atrium is not a discrete ostium. Instead, these junctions are conically shaped, and the triggers found within the pulmonary veins often exist proximally in this junction. This understanding has shaped the development of catheter ablation for atrial fibrillation from a distal ablation procedure isolating the pulmonary veins at the ostium, what is commonly known as pulmonary vein isolation (PVI), to a more proximal isolation of the entire pulmonary vein antrum, referred to as PVAI (Figs. 4 and 5). The pulmonary vein antra isolated with this technique encompass the pulmonary veins, the left atrial roof, the left atrial posterior wall, and a portion of the interatrial septum anterior to the right pulmonary veins (Fig. 6).^{62,63}

Adjunctive Curative Ablation Techniques

In addition to isolation of the pulmonary veins, adjunctive targets often are ablated in an attempt to prevent short- and long-term recurrences of atrial fibrillation and the development of other atrial arrhythmias. The left atrial posterior wall, interatrial septum, and ligament of Marshall are

identified as sites of ectopic beats initiating atrial fibrillation.⁶⁴ Ablation in these areas may improve overall success, especially in patients who have permanent atrial fibrillation. Initiation of atrial flutter, left-sided atrial flutter, atrial tachycardia, and microreentrant atrial flutter may complicate atrial fibrillation ablation.

Ablation lines placed on the posterior wall and roof of the left atrium, typically connecting the left superior pulmonary vein to the right superior pulmonary vein, decrease the risk for developing left atrial arrhythmias, decrease inducibility of atrial fibrillation, and improve long-term success after atrial fibrillation ablation.^{65,66} In addition, mitral valve isthmus lines decrease the likelihood of recurrent atrial fibrillation in patients who have permanent atrial fibrillation. This may be secondary to compartmentalization of the left atrium or substrate modification in the region of the ligament of Marshall and around the coronary sinus.⁶⁷ In addition to these sites, areas of complex fractionated electrograms are implicated in the development of atrial fibrillation. These areas are found most commonly in the pulmonary veins, on the interatrial septum and left atrial roof, and at the coronary sinus ostium. Limited data suggest that ablation at the sites of complex fractionated electrograms as a stand-alone strategy may be associated with a high rate of success in eliminating atrial fibrillation,^{42,68} Finally, some investigators advocate ablation to target autonomic innervation of the left atrium and pulmonary veins. In patients showing autonomic effect while ablation occurs around one or more of the pulmonary veins, denervation of the pulmonary veins, as demonstrated by abolition of the evoked vagal reflex, may improve freedom from atrial fibrillation recurrence.^{69,70}

Additional ablation sites within the right atrium may improve the efficacy of PVAI in certain populations. The superior vena cava (SVC) is a common site of atrial fibrillation triggers. Isolation of the SVC through creating a circumferential ablation line at the junction of the right atrium and SVC may improve the success of atrial fibrillation ablation, especially in patients who have permanent atrial fibrillation (Fig. 7).^{64,71–73} The crista terminalis and the coronary sinus ostium are identified as sites of ectopic beats triggering atrial fibrillation.⁶⁴ Empiric ablation of the coronary sinus, however, does not seem to improve the overall success of PVAI.⁷⁴

The authors' opinion is that inclusion of adjunctive lesions has been an important component of the PVAI technique for some time. Early experience prompted experts to incorporate isolation of the SVC, and the antrum approach includes isolation of the posterior wall, left atrial roof, and interatrial

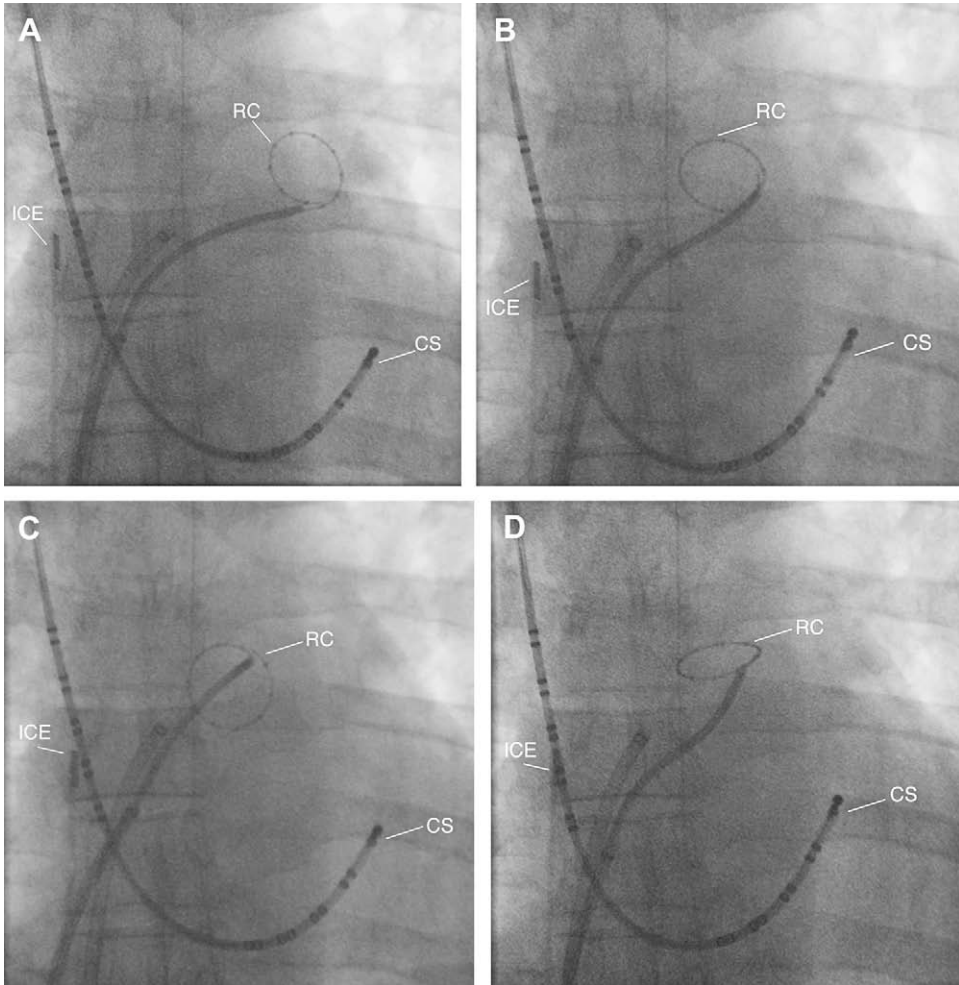


Fig. 4. Fluoroscopic images illustrating movement of the ring mapping catheter (RC) in the antrum of the left superior pulmonary vein, including the os (A), superoposterior antrum (B), inferoposterior antrum (C), and roof (D). The coronary sinus catheter (CS) and ICE probe are seen.

septum and extends anterior to the right pulmonary veins. Additionally, in patients who have permanent atrial fibrillation, the left atrium is interrogated routinely for areas of complex fractionated electrograms, and the septal ablation is extended to include the mitral valve annulus. Challenge with high doses of isoproterenol or adenosine is considered to uncover additional triggers, especially in nonparoxysmal atrial fibrillation.

End Points

The procedural end point depends on the strategy used for ablation, including entry block around the ostium or antrum of the pulmonary veins for electrogram-guided atrial fibrillation ablation. A ring or circular mapping catheter with tightly spaced electrodes is used to detect any electrical gaps within the encircling lesions, and confirms

block of atrial signal into the pulmonary veins. Confirmation of exit block from the pulmonary veins is documented through pacing within the pulmonary veins, or when independent firing in the pulmonary veins is found.²³ During circumferential anatomic ablation, the end point is abolition of local electrograms detected by the ablation catheter. Electrical isolation of the pulmonary veins is not required or achieved in most pulmonary veins. Limited and contradictory data associate termination of atrial fibrillation during ablation and the inability to induce atrial fibrillation further with improved long-term success.⁷⁵⁻⁷⁷

Outcomes and Limitations

Curative catheter ablation for atrial fibrillation has evolved to produce a high overall success rate and low incidence of complications. Studies examining

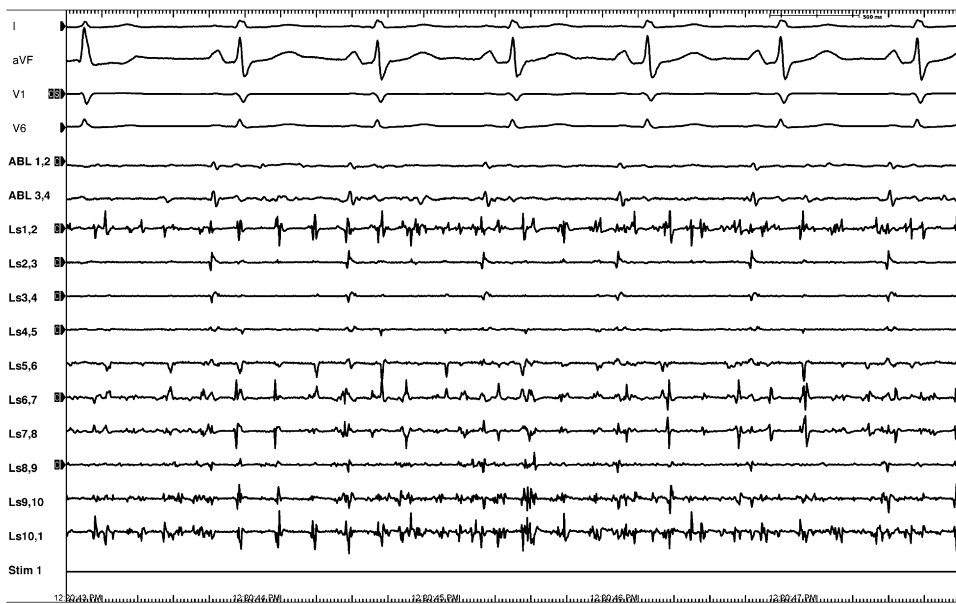


Fig. 5. Intracardiac electrogram obtained after isolation of the right superior pulmonary vein showing fibrillation within the vein recorded by the ring catheter (LS 1–10), whereas the atria remain in sinus rhythm as recorded on the surface leads (I, aVF, V1, and V6).

the cost-effectiveness of atrial fibrillation ablation suggest that cost-equivalency of curative atrial fibrillation ablation to medical management is reached after approximately 5 years.⁷⁸

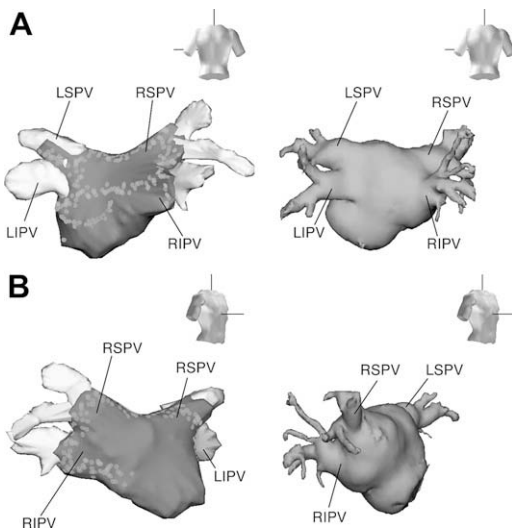


Fig. 6. Electroanatomic images of the left atrium with (A) and without (B) PVAI lesions as seen from PA and RAO perspectives. The antrum included the entire posterior wall and extended anterior to the right PVs along the left septum. Entrance block is the end point of the procedure. Further ablation of the superior vena cava (SVC) along the ostium is also performed if mapping shows PV-like potentials around this region and when high output pacing does not capture the phrenic nerve.

Success rates are highest when treating patients who have paroxysmal atrial fibrillation. In this population, a success rate of 80% to 85% is reasonable.^{45,65,79} When recurrences occur, they often are related to focal areas of recovery, leading to conduction gaps across previous ablation lines.^{80–83} A second procedure to reisolate the pulmonary veins often provides cure in these patients. Success rates in patients who have permanent atrial fibrillation generally are reported closer to 50% to 60% with a single procedure.^{71,75,84,85} Repeat ablation for those experiencing recurrence improves overall success rates to 75% to 90%.^{71,85}

As with most technical procedures, experience is an important factor in attaining optimal outcomes, and centers with higher volumes have higher rates of cure.⁸⁶ Assessment of recurrences varies in the literature, with some investigators relying solely on symptoms, and others routinely performing ambulatory rhythm monitoring to capture asymptomatic recurrences.

Some data suggest that asymptomatic recurrences after atrial fibrillation ablation are uncommon, occurring only in approximately 2% of the population.⁸⁷ Others report higher rates of asymptomatic recurrences. In general, studies with higher reported rates included patients who were continued long term on antiarrhythmic drugs, which may mask symptoms of recurrences. The authors' practice is to discontinue all antiarrhythmic drugs 4 weeks after ablation and not to use

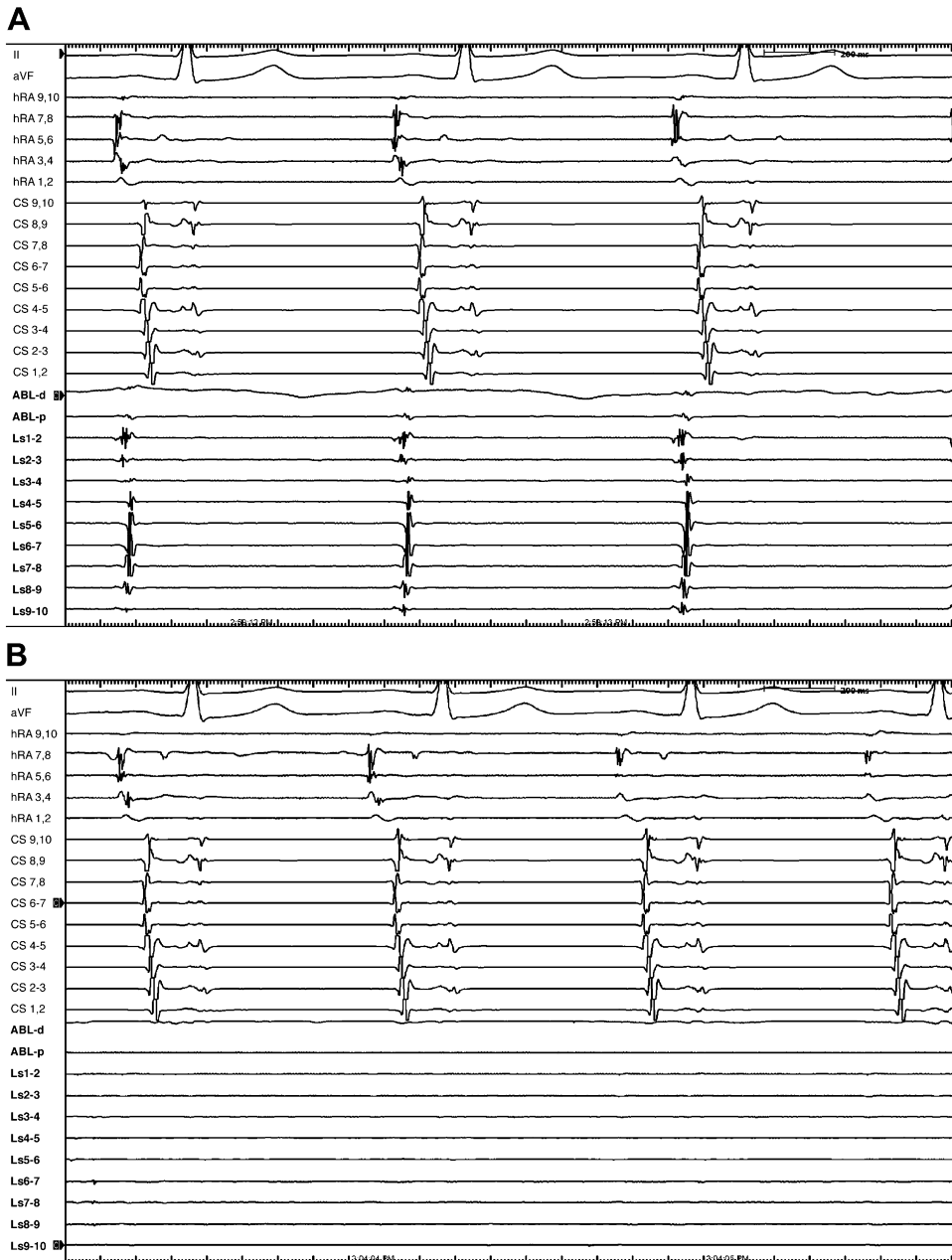


Fig. 7. Intracardiac electrograms showing potentials at the junction of the right atrium and SVC preisolation (A) and absence of potentials on the mapping catheter channels (LS 1–10) post isolation (B).

amiodarone after the procedure. Although success, defined as freedom from atrial fibrillation, may not occur in all patients, those who experience atrial fibrillation recurrence still may benefit from an improvement in symptoms through a reduction in the frequency of episodes or from an improved response to previously ineffective antiarrhythmic medications.

Perhaps the greatest challenge associated with PVAI is the technical difficulty of creating

circumferential isolation using multiple discrete ablation points. Electroanatomic mapping systems may help overcome this challenge to some extent, but operator skill and experience are essential for success.

Other challenges associated with PVAI could arise from the transeptal puncture or problems with patient cooperation. Placement of transeptal punctures posteriorly on the interatrial septum is critical to optimizing the reach of the catheters to

the veins on the posterior wall of the left atrium. Occasionally, the septum may be thickened or fibrous, making it extremely resistant to puncture. ICE is invaluable to visualizing the septum and left atrial structures, thus improving optimal placement of the transseptal punctures.

Ability of patients to cooperate also may pose important challenges during atrial fibrillation ablation. Deep respirations can diminish catheter stability severely, often drawing catheters from an ostial location into the pulmonary veins. Careful titration of sedation to optimize patient comfort while permitting cooperation, especially during critical stages of the procedure, can minimize this difficulty.

In addition to these challenges, radiation exposure is an important consideration for patients and operators during atrial fibrillation ablation. Duration of fluoroscopy can vary widely depending on patient characteristics, technique used, and operator experience. Fluoroscopy times of 60 to 70 minutes are not uncommon. Electroanatomic mapping systems reduce fluoroscopic times.^{88–92} Common practices should be used to reduce radiation dose, including decreasing frame rates, reducing magnification, and reducing the field with shutters. The development of atrial arrhythmias, such as atrial flutter, also may also be a challenge to performing a successful PVI. Depending on the ablation approach, 3% to 30% of patients are reported to develop small-loop atrial reentry, which can be difficult to map.^{93,94}

The overall rate of major complications associated with ostial PVI is reported at 4% to 6%.^{85,86,95} Perforation leading to tamponade may occur in approximately 1% of cases.⁸⁶ This complication often is amenable to treatment with a percutaneous pericardial drain, but may rarely require thoracotomy and pericardial window. Posterior perforation and formation of a left atrial-esophageal fistula are reported. Power titration using detection of microbubbles on ICE is reported to prevent this complication. In addition, use of a radio-opaque esophageal temperature probe allows visualization of the esophageal course and monitoring of esophageal temperatures during ablation.

Radiofrequency current delivery should be terminated when the esophageal temperature increases, and not resumed in that location until temperatures return to baseline. No cases of left atrial-esophageal fistula formation have been reported when this technique is used. Other experts use ingested barium paste to localize the esophagus and help avoid this complication.

Phrenic nerve injury leading to diaphragmatic paralysis or gastric emptying syndrome is reported

at a rate of 0.1% to 0.48%. This complication commonly is associated with ablation in the regions of the right superior pulmonary vein, left atrial appendage, and SVC. Recovery is seen in approximately 66% of cases.^{86,96,97} Fluoroscopic visualization of the diaphragm while ablating in these areas may show diaphragmatic stimulation during radiofrequency ablation and allow energy delivery to be terminated before permanent injury to the phrenic nerve occurs. Before radiofrequency current is delivered over the lateral aspects of the SVC–right atrial junction, pacing at high output may reveal phrenic nerve stimulation, evidenced by diaphragmatic stimulation, indicating that ablation in that region is unsafe.

Cerebrovascular accidents and transient ischemic attacks are feared complications of any left-sided ablation procedure, including PVAI. Rates are reported at approximately 0.5% to 2.5%.^{86,98,99} Targeting an activated clotting time of 350 to 400 seconds compared with lower activated clotting time targets significantly reduces the risk for thromboembolic events during PVAI, with a reported event rate of less than 0.5%.⁵²

Severe symptomatic pulmonary vein stenosis may complicate PVI but has become rare, because the technique has moved from ablating distally within the pulmonary veins to a more proximal approach of isolating the pulmonary vein antra. Mild to moderate pulmonary stenosis does not limit flow significantly and is not associated with symptoms. Severe stenosis is reported in 15% to 20% of patients undergoing ablation within the pulmonary veins.¹⁰⁰ Isolation at the pulmonary vein ostium rather than focal ablation within the pulmonary veins is associated with pulmonary vein stenosis rates of 1% to 2%.^{54,86,100–102} Using ICE to visualize the pulmonary veins and isolating even more proximally in the pulmonary vein antra further reduces the risk for pulmonary vein stenosis (**Fig. 8**).^{20,100} Even when severe, pulmonary

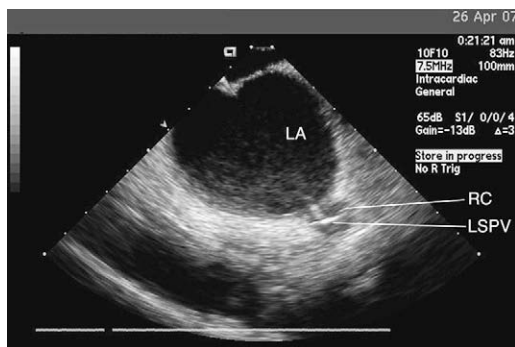


Fig. 8. ICE showing left atrium (LA) and the ring catheter (RC) at the ostium of the left superior pulmonary vein (LSPV).

vein stenosis may be asymptomatic. However, early and repeated angioplasty and stenting have been shown to be an effective treatment option and only a fraction of patients continue to have chronic symptoms.^{54,86,103}

Follow-Up

Postablation follow-up should assess the efficacy of the procedure, screen for complications, and address postablation medical therapy for atrial fibrillation. Patients are discharged with a transtelephonic monitor and instructions to transmit rhythm strips whenever they feel symptoms consistent with a recurrence. Additionally, routine transmissions scheduled several times weekly screen for recurrence. Recurrences of atrial fibrillation and episodes of atrial tachycardia or atypical atrial flutter are common within the first few weeks after PVAI. These early recurrences often are related to inflammation from the ablation and resolve completely as inflammation subsides. As a result, recurrences within the first 6 to 8 weeks are not considered an indication that the procedure failed. For this same reason, antiarrhythmic medications typically are restarted immediately after PVAI and discontinued after 8 weeks. To further screen for asymptomatic recurrences, 24-hour holter monitoring is performed at 3 months' follow-up and every 3 months thereafter. Outpatient follow-up is routinely scheduled at 3 months after PVAI to evaluate for symptomatic recurrence and have a CT scan performed to assess for pulmonary vein stenosis/occlusion.⁵⁴ If even mild stenosis is detected, the CT scan is repeated at the next follow-up visit. Warfarin is continued perioperatively and at least until the 3- to 6-month follow-up visit. Discontinuation of warfarin after PVAI is under investigation. The decision to terminate anticoagulation after PVAI must be made on an individual basis after risk for recurrence is carefully assessed and discussed with the patient.

Future Advances

Much of the effort in advancing curative atrial fibrillation ablation is directed toward meeting the technical demands of isolating the pulmonary veins. Balloon catheters, alternative ablative energy sources, and remote catheter manipulation all strive to diminish these technical demands. Balloon catheters theoretically could assist operators in stabilizing a catheter in a pulmonary vein and allow circumferential delivery of ablative energy. These catheters, however, must be able to accommodate the widely variable anatomy found in the pulmonary veins. Additionally, they must ensure ablation energy is not delivered too

distally in to the pulmonary veins. High-intensity ultrasound, cryotherapy, and diode laser are potential alternatives to radiofrequency ablation, and could be combined with balloon catheter technology to create circumferential lesions with a few applications, further reducing the technical challenge of circumferential isolation and potentially reducing the time required for ablation. To be viable alternatives, these sources must be able to reliably produce lesions at a consistent depth and have a safety profile at least equal to that of radiofrequency energy.¹⁰⁴

Large magnets may be used to steer a soft-tipped catheter, allowing remote guidance of lesion delivery. Robotic catheter navigation systems also allow remote manipulation of catheters. Both strategies have the potential to dramatically reduce operators' radiation exposure and improve catheter stability and fine manipulation. When combined with electroanatomic mapping, these systems conceivably could automate much of the ablation procedure. To gain widespread use, however, these systems must meet demands of time-saving, ease of use, and cost-effectiveness.¹⁰⁵⁻¹⁰⁷

In addition, investigators have been focusing recently on two additional parameters that could be monitored when performing mapping and ablations in the cardiac chambers. New sensors have been introduced in catheter and long sheath that measure the force (in grams) applied by the catheter to the tissue and the phase angle the catheter forms on the cardiac surface when delivering energy. When better developed, this information will help improve the effectiveness of the lesions, and hence the success rate and safety of catheter ablation.^{108,109} The field of catheter ablation for atrial fibrillation has grown and evolved rapidly over recent years and is expected to continue.

REFERENCES

1. Lloyd-Jones DM, Wang TJ, Leip EP, et al. Lifetime risk for development of atrial fibrillation: the Framingham heart study. *Circulation* 2004;110(9):1042-6.
2. Risk factors for stroke and efficacy of antithrombotic therapy in atrial fibrillation. Analysis of pooled data from five randomized controlled trials. *Arch Intern Med* 1994;154(13):1449-57.
3. Wolf PA, Abbott RD, Kannel WB. Atrial fibrillation as an independent risk factor for stroke: the Framingham Study. *Stroke* 1991;22(8):983-8.
4. Benjamin EJ, Wolf PA, D'Agostino RB, et al. Impact of atrial fibrillation on the risk of death: the Framingham heart study. *Circulation* 1998;98(10):946-52.

5. Kannel WB, Wolf PA, Benjamin EJ, et al. Prevalence, incidence, prognosis, and predisposing conditions for atrial fibrillation: population-based estimates. *Am J Cardiol* 1998;82(8A):2N-9N.
6. Chung MK. Atrial fibrillation: rate control is as good as rhythm control for some, but not all. *Cleve Clin J Med* 2003;70(6):567-73.
7. Van Gelder IC, Hagens VE, Bosker HA, et al. A comparison of rate control and rhythm control in patients with recurrent persistent atrial fibrillation. *N Engl J Med* 2002;347(23):1834-40.
8. Wyse DG, Waldo AL, DiMarco JP, et al. A comparison of rate control and rhythm control in patients with atrial fibrillation. *N Engl J Med* 2002;347(23):1825-33.
9. Corley SD, Epstein AE, DiMarco JP, et al. Relationships between sinus rhythm, treatment, and survival in the atrial fibrillation follow-up investigation of rhythm management (AFFIRM) study. *Circulation* 2004;109(12):1509-13.
10. Wazni OM, Marrouche NF, Martin DO, et al. Radiofrequency ablation vs antiarrhythmic drugs as first-line treatment of symptomatic atrial fibrillation: a randomized trial. *J Am Med Assoc* 2005;293(21):2634-40.
11. Pappone C, Rosanio S, Augello G, et al. Mortality, morbidity, and quality of life after circumferential pulmonary vein ablation for atrial fibrillation: outcomes from a controlled nonrandomized long-term study. *J Am Coll Cardiol* 2003;42(2):185-97.
12. Vedel J, Frank R, Fontaine G, et al. [Permanent intra-hisian atrioventricular block induced during right intraventricular exploration]. *Arch Mal Coeur Vaiss* 1979;72(1):107-12 [in French].
13. Gallagher JJ, Svenson RH, Kasell JH, et al. Catheter technique for closed-chest ablation of the atrioventricular conduction system. *N Engl J Med* 1982;306(4):194-200.
14. Scheinman MM, Morady F, Hess DS, et al. Catheter-induced ablation of the atrioventricular junction to control refractory supraventricular arrhythmias. *J Am Med Assoc* 1982;248(7):851-5.
15. Evans GT, Scheinman MM, Scheinman MM, et al. The percutaneous cardiac mapping and ablation registry: final summary of results. *Pacing Clin Electrophysiol* 1988;11(11 Pt 1):1621-6.
16. Chen SA, Tsang WP, Hsia CP, et al. Catheter ablation of free wall accessory atrioventricular pathways in 89 patients with Wolff-Parkinson-White syndrome—comparison of direct current and radiofrequency ablation. *Eur Heart J* 1992;13(10):1329-38.
17. Morady F, Calkins H, Langberg JJ, et al. A prospective randomized comparison of direct current and radiofrequency ablation of the atrioventricular junction. *J Am Coll Cardiol* 1993;21(1):102-9.
18. Olgin JE, Scheinman MM. Comparison of high energy direct current and radiofrequency catheter ablation of the atrioventricular junction. *J Am Coll Cardiol* 1993;21(3):557-64.
19. Haines DE. The biophysics of radiofrequency catheter ablation in the heart: the importance of temperature monitoring. *Pacing Clin Electrophysiol*. 1993; 16(3 Pt 2):586-91.
20. Marrouche NF, Martin DO, Wazni O, et al. Phased-array intracardiac echocardiography monitoring during pulmonary vein isolation in patients with atrial fibrillation: impact on outcome and complications. *Circulation* 2003;107(21):2710-6.
21. Kalbfleisch SJ, Williamson B, Man KC, et al. A randomized comparison of the right- and left-sided approaches to ablation of the atrioventricular junction. *Am J Cardiol* 1993;72(18):1406-10.
22. Dubuc M, Khairy P, Rodriguez-Santiago A, et al. Catheter cryoablation of the atrioventricular node in patients with atrial fibrillation: a novel technology for ablation of cardiac arrhythmias. *J Cardiovasc Electrophysiol* 2001;12(4):439-44.
23. Weerasooriya R, Davis M, Powell A, et al. The Australian intervention randomized control of rate in atrial fibrillation trial (AIRCRAFT). *J Am Coll Cardiol*. 2003;41(10):1697-702.
24. Verma A, Newman D, Geist M, et al. Effects of rhythm regularization and rate control in improving left ventricular function in atrial fibrillation patients undergoing atrioventricular nodal ablation. *Can J Cardiol* 2001;17(4):437-45.
25. Wood MA, Kay GN, Ellenbogen KA. The North American experience with the ablate and pace trial (APT) for medically refractory atrial fibrillation. *Europace* 1999;1(1):22-5.
26. Brignole M, Menozzi C, Gianfranchi L, et al. Assessment of atrioventricular junction ablation and VVIR pacemaker versus pharmacological treatment in patients with heart failure and chronic atrial fibrillation: a randomized, controlled study. *Circulation* 1998;98(10):953-60.
27. Fitzpatrick AP, Kourouyan HD, Siu A, et al. Quality of life and outcomes after radiofrequency His-bundle catheter ablation and permanent pacemaker implantation: impact of treatment in paroxysmal and established atrial fibrillation. *Am Heart J* 1996;131(3):499-507.
28. Natale A, Zimerman L, Tomassoni G, et al. Impact on ventricular function and quality of life of transcatheter ablation of the atrioventricular junction in chronic atrial fibrillation with a normal ventricular response. *Am J Cardiol* 1996;78(12):1431-3.
29. Wood MA, Brown-Mahoney C, Kay GN, et al. Clinical outcomes after ablation and pacing therapy for atrial fibrillation: a meta-analysis. *Circulation* 2000; 101(10):1138-44.
30. Natale A, Zimerman L, Tomassoni G, et al. AV node ablation and pacemaker implantation after

- withdrawal of effective rate-control medications for chronic atrial fibrillation: effect on quality of life and exercise performance. *Pacing Clin Electrophysiol* 1999;22(11):1634–9.
31. Geelen P, Brugada J, Andries E, et al. Ventricular fibrillation and sudden death after radiofrequency catheter ablation of the atrioventricular junction. *Pacing Clin Electrophysiol* 1997;20(2 Pt 1):343–8.
 32. Wilkoff BL, Cook JR, Epstein AE, et al. Dual-chamber pacing or ventricular backup pacing in patients with an implantable defibrillator: the dual chamber and VVI implantable defibrillator (DAVID) trial. *J Am Med Assoc* 2002;288(24):3115–23.
 33. Doshi RN, Daoud EG, Fellows C, et al. Left ventricular-based cardiac stimulation post AV nodal ablation evaluation (the PAVE study). *J Cardiovasc Electrophysiol* 2005;16(11):1160–5.
 34. Khan M, Jais P, Cummings J, Di Biase L, et al. Results of randomized controlled trial of pulmonary vein antrum isolation vs. AV node ablation with Biventricular pacing for treatment of atrial fibrillation in patients with congestive heart failure (PABA CHF). *N Engl J Med*, in press.
 35. Cox JL, Canavan TE, Schuessler RB, et al. The surgical treatment of atrial fibrillation. II. Intraoperative electrophysiologic mapping and description of the electrophysiologic basis of atrial flutter and atrial fibrillation. *J Thorac Cardiovasc Surg* 1991;101(3):406–26.
 36. Padanilam BJ, Prystowsky EN. Should atrial fibrillation ablation be considered first-line therapy for some patients? Should ablation be first-line therapy and for whom? The antagonist position. *Circulation* 2005;112(8):1223–9 [discussion: 1230].
 37. Packer DL, Asirvatham S, Munger TM. Progress in non-pharmacologic therapy of atrial fibrillation. *J Cardiovasc Electrophysiol* 2003;14(Suppl 12):S296–309.
 38. Haissaguerre M, Jais P, Shah DC, et al. Spontaneous initiation of atrial fibrillation by ectopic beats originating in the pulmonary veins. *N Engl J Med* 1998;339(10):659–66.
 39. Chen SA, Hsieh MH, Tai CT, et al. Initiation of atrial fibrillation by ectopic beats originating from the pulmonary veins: electrophysiological characteristics, pharmacological responses, and effects of radiofrequency ablation. *Circulation* 1999;100(18):1879–86.
 40. Verma A, Wazni OM, Marrouche NF, et al. Pre-existent left atrial scarring in patients undergoing pulmonary vein antrum isolation: an independent predictor of procedural failure. *J Am Coll Cardiol* 2005;45(2):285–92.
 41. Natale A, Pisano E, Beheiry S, et al. Ablation of right and left atrial premature beats following cardioversion in patients with chronic atrial fibrillation refractory to antiarrhythmic drugs. *Am J Cardiol* 2000;85(11):1372–5.
 42. Nademanee K, McKenzie J, Kosar E, et al. A new approach for catheter ablation of atrial fibrillation: mapping of the electrophysiologic substrate. *J Am Coll Cardiol* 2004;43:2044–53.
 43. Kanagaratnam L, Tomassoni G, Schweikert R, et al. Empirical pulmonary vein isolation in patients with chronic atrial fibrillation using a three-dimensional nonfluoroscopic mapping system: long-term follow-up. *Pacing Clin Electrophysiol* 2001;24(12):1774–9.
 44. Hocini M, Sanders P, Jais P, et al. Prevalence of pulmonary vein disconnection after anatomical ablation for atrial fibrillation: consequences of wide atrial encircling of the pulmonary veins. *Eur Heart J* 2005;26(7):696–704.
 45. Mantovan R, Verlati R, Calzolari V, et al. Comparison between anatomical and integrated approaches to atrial fibrillation ablation: adjunctive role of electrical pulmonary vein disconnection. *J Cardiovasc Electrophysiol* 2005;16(12):1293–7.
 46. Fuster V, Reven LE, Cannom DS, et al. ACC/AHA/ESC 2006 Practice guidelines for the management of patients with atrial fibrillation. *J Am Coll Cardiol* 2006;48(4):e149–246.
 47. Lakkireddy D, Rangisetty U, Prasad S, et al. Intracardiac echo guided radiofrequency catheter ablation of atrial fibrillation in patients with atrial septal defect (ASD) or patent foramen ovale (PFO) repair: a feasibility, safety and Efficacy study. *J Cardiovasc Electrophysiol*, 2008 Jul 25. [Epub ahead of print].
 48. Kannel WB, Abbott RD, Savage DD, et al. Epidemiologic features of chronic atrial fibrillation: the Framingham study. *N Engl J Med* 1982;306(17):1018–22.
 49. Oral H, Knight BP, Tada H, et al. Pulmonary vein isolation for paroxysmal and persistent atrial fibrillation. *Circulation* 2002;105(9):1077–81.
 50. Wazni OM, Beheiry S, Fahmy T, et al. Atrial fibrillation ablation in patients with therapeutic international normalized ratio: comparison of strategies of anticoagulation management in the periprocedural period. *Circulation* 2007;116:2531–4.
 51. Ashar MS, Pennington J, Callans DJ, et al. Localization of arrhythmogenic triggers of atrial fibrillation. *J Cardiovasc Electrophysiol* 2000;11(12):1300–5.
 52. Wazni OM, Rossillo A, Marrouche NF, et al. Embolic events and char formation during pulmonary vein isolation in patients with atrial fibrillation: impact of different anticoagulation regimens and importance of intracardiac echo imaging. *J Cardiovasc Electrophysiol* 2005;16(6):576–81.
 53. Robbins IM, Colvin EV, Doyle TP, et al. Pulmonary vein stenosis after catheter ablation of atrial fibrillation. *Circulation* 1998;98(17):1769–75.
 54. Di Biase L, Fahmy TS, Wazni OM, et al. Pulmonary vein total occlusion following catheter ablation for atrial fibrillation: clinical implications after long-term follow-up. *J Am Coll Cardiol* 2006;48:2493–9.

55. Nilsson B, Chen X, Pehrson S, et al. Recurrence of pulmonary vein conduction and atrial fibrillation after pulmonary vein isolation for atrial fibrillation: a randomized trial of the ostial versus the extraostial ablation strategy. *Am Heart J* 2006; 152(3):e531–8.
56. Oral H, Scharf C, Chugh A, et al. Catheter ablation for paroxysmal atrial fibrillation: segmental pulmonary vein ostial ablation versus left atrial ablation. *Circulation* 2003;108(19):2355–60.
57. Hocini M, Haissaguerre M, Shah D, et al. Multiple sources initiating atrial fibrillation from a single pulmonary vein identified by a circumferential catheter. *Pacing Clin Electrophysiol* 2000;23(11 Pt 2):1828–31.
58. Haissaguerre M, Shah DC, Jais P, et al. Electrophysiological breakthroughs from the left atrium to the pulmonary veins. *Circulation* 2000;102(20):2463–5.
59. Oral H, Chugh A, Good E, et al. A tailored approach to catheter ablation of paroxysmal atrial fibrillation. *Circulation* 2006;113(15):1824–31.
60. Katritsis DG, Ellenbogen KA, Panagiotakos DB, et al. Ablation of superior pulmonary veins compared to ablation of all four pulmonary veins. *J Cardiovasc Electrophysiol* 2004;15(6):641–5.
61. Gerstenfeld EP, Callans DJ, Dixit S, et al. Incidence and location of focal atrial fibrillation triggers in patients undergoing repeat pulmonary vein isolation: implications for ablation strategies. *J Cardiovasc Electrophysiol* 2003;14(7):685–90.
62. Kanj M, Wazni O, Natale A. Pulmonary vein antrum isolation. *Heart Rhythm* 2007;4(Suppl 3):S73–9.
63. Kanj MH, Wazni OM, Natale A. How to do circular mapping catheter-guided pulmonary vein antrum isolation: the Cleveland clinic approach. *Heart Rhythm* 2006;3(7):866–9.
64. Lin WS, Tai CT, Hsieh MH, et al. Catheter ablation of paroxysmal atrial fibrillation initiated by non-pulmonary vein ectopy. *Circulation* 2003;107(25):3176–83.
65. Hocini M, Jais P, Sanders P, et al. Techniques, evaluation, and consequences of linear block at the left atrial roof in paroxysmal atrial fibrillation: a prospective randomized study. *Circulation* 2005;112(24):3688–96.
66. Pappone C, Manguso F, Vicedomini G, et al. Prevention of iatrogenic atrial tachycardia after ablation of atrial fibrillation: a prospective randomized study comparing circumferential pulmonary vein ablation with a modified approach. *Circulation* 2004;110(19):3036–42.
67. Fassini G, Riva S, Chioldelli R, et al. Left mitral isthmus ablation associated with PV Isolation: long-term results of a prospective randomized study. *J Cardiovasc Electrophysiol* 2005;16(11):1150–6.
68. Rostock T, Rotter M, Sanders P, et al. High-density activation mapping of fractionated electrograms in the atria of patients with paroxysmal atrial fibrillation. *Heart Rhythm* 2006;3(1):27–34.
69. Bauer A, Deisenhofer I, Schneider R, et al. Effects of circumferential or segmental pulmonary vein ablation for paroxysmal atrial fibrillation on cardiac autonomic function. *Heart Rhythm* 2006;3(12):1428–35.
70. Pappone C, Santinelli V, Manguso F, et al. Pulmonary vein denervation enhances long-term benefit after circumferential ablation for paroxysmal atrial fibrillation. *Circulation* 2004;109(3):327–34.
71. Calo L, Lamberti F, Loricchio ML, et al. Left atrial ablation versus biatrial ablation for persistent and permanent atrial fibrillation: a prospective and randomized study. *J Am Coll Cardiol* 2006;47(12):2504–12.
72. Goya M, Ouyang F, Ernst S, et al. Electroanatomic mapping and catheter ablation of breakthroughs from the right atrium to the superior vena cava in patients with atrial fibrillation. *Circulation* 2002;106(11):1317–20.
73. Tsai CF, Tai CT, Hsieh MH, et al. Initiation of atrial fibrillation by ectopic beats originating from the superior vena cava: electrophysiological characteristics and results of radiofrequency ablation. *Circulation* 2000;102(1):67–74.
74. Kanj M, Muelet J, Phillips K, Barrett C, et al. Empiric coronary sinus ablation during pulmonary venous isolation does not improve the success of AF ablation. *Heart Rhythm* 2007;4(Suppl):5–22.
75. Richter B, Gwechenberger M, Filzmoser P, et al. Is inducibility of atrial fibrillation after radio frequency ablation really a relevant prognostic factor? *Eur Heart J* 2006;27(21):2553–9.
76. Oral H, Chugh A, Lemola K, et al. Noninducibility of atrial fibrillation as an end point of left atrial circumferential ablation for paroxysmal atrial fibrillation: a randomized study. *Circulation* 2004;110(18):2797–801.
77. Haissaguerre M, Sanders P, Hocini M, et al. Changes in atrial fibrillation cycle length and inducibility during catheter ablation and their relation to outcome. *Circulation* 2004;109(24):3007–13.
78. Khaykin Y. Cost-effectiveness of catheter ablation for atrial fibrillation. *Curr Opin Cardiol* 2007;22(1):11–7.
79. Liu X, Long D, Dong J, et al. Is circumferential pulmonary vein isolation preferable to stepwise segmental pulmonary vein isolation for patients with paroxysmal atrial fibrillation? *Circ J* 2006;70(11):1392–7.
80. Mesas CE, Augello G, Lang CC, et al. Electroanatomic remodeling of the left atrium in patients undergoing repeat pulmonary vein ablation: mechanistic insights and implications for ablation. *J Cardiovasc Electrophysiol* 2006;17(12):1279–85.
81. Rostock T, O'Neill MD, Sanders P, et al. Characterization of conduction recovery across left atrial linear lesions in patients with paroxysmal and persistent atrial fibrillation. *J Cardiovasc Electrophysiol* 2006;17(10):1106–11.
82. Ouyang F, Antz M, Ernst S, et al. Recovered pulmonary vein conduction as a dominant factor for recurrent atrial tachyarrhythmias after complete

- circular isolation of the pulmonary veins: lessons from double Lasso technique. *Circulation* 2005; 111(2):127–35.
83. Cappato R, Negroni S, Pecora D, et al. Prospective assessment of late conduction recurrence across radiofrequency lesions producing electrical disconnection at the pulmonary vein ostium in patients with atrial fibrillation. *Circulation* 2003;108(13):1599–604.
 84. Oral H, Pappone C, Chugh A, et al. Circumferential pulmonary-vein ablation for chronic atrial fibrillation. *N Engl J Med* 2006;354(9):934–41.
 85. Cheema A, Dong J, Dalal D, et al. Long-term safety and efficacy of circumferential ablation with pulmonary vein isolation. *J Cardiovasc Electrophysiol* 2006;17(10):1080–5.
 86. Cappato R, Calkins H, Chen SA, et al. Worldwide survey on the methods, efficacy, and safety of catheter ablation for human atrial fibrillation. *Circulation* 2005;111(9):1100–5.
 87. Oral H, Veerareddy S, Good E, et al. Prevalence of asymptomatic recurrences of atrial fibrillation after successful radiofrequency catheter ablation. *J Cardiovasc Electrophysiol* 2004;15(8):920–4.
 88. Estner HL, Deisenhofer I, Luik A, et al. Electrical isolation of pulmonary veins in patients with atrial fibrillation: reduction of fluoroscopy exposure and procedure duration by the use of a non-fluoroscopic navigation system (NavX). *Europace* 2006;8(8):583–7.
 89. Tondo C, Mantica M, Russo G, et al. A new nonfluoroscopic navigation system to guide pulmonary vein isolation. *Pacing Clin Electrophysiol* 2005;28(Suppl 1):S102–5.
 90. Karch MR, Zrenner B, Deisenhofer I, et al. Freedom from atrial tachyarrhythmias after catheter ablation of atrial fibrillation: a randomized comparison between 2 current ablation strategies. *Circulation* 2005;111(22):2875–80.
 91. Wood MA, Christman PJ, Shepard RK, et al. Use of a non-fluoroscopic catheter navigation system for pulmonary vein isolation. *J Interv Card Electrophysiol* 2004;10(2):165–70.
 92. Macle L, Jais P, Scavee C, et al. Pulmonary vein disconnection using the LocaLisa three-dimensional nonfluoroscopic catheter imaging system. *J Cardiovasc Electrophysiol* 2003;14(7):693–7.
 93. Cummings JE, Schweikert R, Saliba W, et al. Left atrial flutter following pulmonary vein antrum isolation with radiofrequency energy: linear lesions or repeat isolation. *J Cardiovasc Electrophysiol* 2005;16(3):293–7.
 94. Deisenhofer I, Estner H, Zrenner B, et al. Left atrial tachycardia after circumferential pulmonary vein ablation for atrial fibrillation: incidence, electrophysiological characteristics, and results of radiofrequency ablation. *Europace* 2006;8(8):573–82.
 95. Stabile G, Bertaglia E, Senatore G, et al. Feasibility of pulmonary vein ostia radiofrequency ablation in patients with atrial fibrillation: a multicenter study (CACAF pilot study). *Pacing Clin Electrophysiol* 2003;26(1 Pt 2):284–7.
 96. Sacher F, Monahan KH, Thomas SP, et al. Phrenic nerve injury after atrial fibrillation catheter ablation: characterization and outcome in a multicenter study. *J Am Coll Cardiol* 2006;47(12):2498–503.
 97. Bai R, Patel MD, Di Biase L, et al. Phrenic nerve injury after catheter ablation: should we worry about this complication? *J Cardiovasc Electrophysiol* 2006;17:944–8.
 98. Mansour M, Ruskin J, Keane D. Efficacy and safety of segmental ostial versus circumferential extra-ostial pulmonary vein isolation for atrial fibrillation. *J Cardiovasc Electrophysiol* 2004;15(5):532–7.
 99. Zhou L, Keane D, Reed G, et al. Thromboembolic complications of cardiac radiofrequency catheter ablation: a review of the reported incidence, pathogenesis and current research directions. *J Cardiovasc Electrophysiol* 1999;10(4):611–20.
 100. Saad EB, Rossillo A, Saad CP, et al. Pulmonary vein stenosis after radiofrequency ablation of atrial fibrillation: functional characterization, evolution, and influence of the ablation strategy. *Circulation* 2003;108(25):3102–7.
 101. Purerfellner H, Cihal R, Aichinger J, et al. Pulmonary vein stenosis by ostial irrigated-tip ablation: incidence, time course, and prediction. *J Cardiovasc Electrophysiol* 2003;14(2):158–64.
 102. Kato R, Lickfett L, Meininger G, et al. Pulmonary vein anatomy in patients undergoing catheter ablation of atrial fibrillation: lessons learned by use of magnetic resonance imaging. *Circulation* 2003;107(15):2004–10.
 103. Saad EB, Marrouche NF, Saad CP, et al. Pulmonary vein stenosis after catheter ablation of atrial fibrillation: emergence of a new clinical syndrome. *Ann Intern Med* 2003;138(8):634–8.
 104. Barrett C, Natale A. Towards balloon based technologies—all that glitters is not gold. *J Cardiovasc Electrophysiol* 2008 Jun 12 [Epub ahead of print].
 105. Di Biase L, Fahmy TS, Patel D, et al. Remote magnetic navigation: human experience in pulmonary vein ablation. *J Am Coll Cardiol* 2007;50:868–74.
 106. Pappone C, Vicedomini G, Manguso F, et al. Robotic magnetic navigation for atrial fibrillation ablation. *J Am Coll Cardiol* 2006;47(7):1390–400.
 107. Saliba WI, Reddy VK, Oussama W, et al. Atrial fibrillation ablation using a robotic catheter remote control system: initial human experience and long-term follow-up results. *J Am Coll Cardiol* 2008;51:2407–11.
 108. Di Biase L, Arruda M, Armaganijan L, et al. Real Time Monitoring of Tip Electrode-Tissue Orientation and Contact Force: Optimizing Accuracy and Safety of Mapping and Ablation Procedures. *J Am Coll Cardiol* 2008;51(10 Suppl. 1):811–3 [A 26, abstract oral presentation].
 109. Di Biase L, Cummings JE, Barrett C, et al. Relationship between Catheter force, popping and char formation: experience with robotic navigation. *J Am Coll Cardiol* 2008;51(10 Suppl. 1):1036–302 [A 376, ABSTRACTS - Best Poster Award Competition].