

150 Practice ECGs: Interpretation and Review

Third Edition

Part I: How to Interpret ECGs

Chapter 1: Baseline Data

Chapter 2: Morphologic Changes in P, QRS, ST, and T

Part II: 150 Practice ECGs

Part III: Interpretation and Comments

For Marilyn

150 Practice ECGs: Interpretation and Review

Third Edition

George J. Taylor, MD

Professor of Medicine
The Medical University of South Carolina
The Ralph H. Johnson VA Medical Center
Charleston, South Carolina, USA



Blackwell
Publishing

© 2006 George J. Taylor

Published by Blackwell Publishing Ltd

Blackwell Publishing, Inc., 350 Main Street, Malden, Massachusetts 02148-5020, USA

Blackwell Publishing Ltd, 9600 Garsington Road, Oxford OX4 2DQ, UK

Blackwell Publishing Asia Pty Ltd, 550 Swanston Street, Carlton, Victoria 3053, Australia

The right of the Author to be identified as the Author of this Work has been asserted in accordance with the Copyright, Designs and Patents Act 1988.

All rights reserved. No part of this publication may be reproduced, stored in a retrieval system, or transmitted, in any form or by any means, electronic, mechanical, photocopying, recording or otherwise, except as permitted by the UK Copyright, Designs and Patents Act 1988, without the prior permission of the publisher.

First published 1997

Second edition 2002

Third edition 2006

Library of Congress Cataloging-in-Publication Data

Taylor, George Jesse.

150 practice ECGs : interpretation and review / George J. Taylor.—3rd ed.

p. ; cm.

Includes index.

ISBN-13: 978-1-4051-0483-8 (pbk. : alk. paper)

ISBN-10: 1-4051-0483-X (pbk. : alk. paper)

1. Electrocardiography—Problems, exercises, etc. I. Title. II. Title: One hundred fifty practice ECGs.

[DNLM: 1. Electrocardiography—Examination Questions. WG 18.2

T241z 2006]

RC683.5.E5T34 2006

616.1'207547—dc22

2005017378

ISBN-13: 978-1-4051-0483-8

ISBN-10: 1-4051-0483-X

A catalogue record for this title is available from the British Library

Set in 10 on 13 pt Meriden by SNP Best-set Typesetter Ltd., Hong Kong

Printed and bound by Edwards Brothers Inc., USA

Commissioning Editor: Gina Almond

Development Editor: Vicki Donald

Production Controller: Kate Charman

For further information on Blackwell Publishing, visit our website:

www.blackwellcardiology.com

Notice: The indications and dosages of all drugs in this book have been recommended in the medical literature and conform to the practices of the general community. The medications described do not necessarily have specific approval by the Food and Drug Administration for use in the diseases and dosages for which they are recommended. The package insert for each drug should be consulted for use and dosage as approved by the FDA. Because standards for usage change, it is advisable to keep abreast of revised recommendations, particularly those concerning new drugs.

The publisher's policy is to use permanent paper from mills that operate a sustainable forestry policy, and which has been manufactured from pulp processed using acid-free and elementary chlorine-free practices. Furthermore, the publisher ensures that the text paper and cover board used have met acceptable environmental accreditation standards.

Contents

Preface, vi

PART I: How to Interpret ECGs, 1

Normal Intervals, 1

Chapter 1: Baseline Data, 3

A Protocol for Reading ECGs, 3

How to Use This Book, 3

The ECG Is a Voltmeter, 4

Measuring Heart Rate, 6

Intervals, 7

PR Interval, 7

QRS Duration, 8

T Wave and the QT Interval, 9

Rhythm, 11

Sinus Rhythm and Sinus Arrhythmia, 11

Heart Block, 12

Atrial Arrhythmias, 18

Ventricular Arrhythmias, 28

Electrical Axis, 33

QRS Axis, 33

T Wave Axis, 35

Chapter 2: Morphologic Changes in P, QRS, ST, and T, 37

Atrial (P Wave) Abnormalities, 37

Left Atrial Abnormality, 37

Right Atrial Abnormality, 38

Intraventricular Conduction

Abnormalities, 38

Right Bundle Branch Block, 38

*Incomplete Right Bundle Branch
Block, 41*

Left Bundle Branch Block, 41

*Left Anterior and Posterior Fascicular
Block, 43*

Bifascicular Block, 43

Ventricular Hypertrophy, QRS Amplitude,
and R Wave Progression, 44

Left Ventricular Hypertrophy, 45

Right Ventricular Hypertrophy, 46

*Delayed, or Poor, R Wave Progression in
Precordial Leads, 47*

Low QRS Voltage, 48

Patterns of Ischemia and Infarction, 49

ST Segment Depression, 49

T Wave Inversion, 53

ST Segment Elevation, 55

*Q Waves and Evolution of Myocardial
Infarction, 58*

PART II: 150 Practice ECGs, 63

PART III: Interpretation and Comments, 215

Index, 253

Notes, 265

Preface

Your problem as a student of electrocardiography is that you may not get enough practice to become good at it. The best way to get experience is to read ECGs from the hospital's daily accumulation, *commit your interpretation to paper*, then look over the shoulder of the experienced person who is reading those ECGs for the record.

Unfortunately, most students and residents do not have that opportunity. Training programs are placing an ever-increasing clinical load on their faculties. One-on-one teaching experiences are hard to program. It is the rare institution that provides *most* of its students and residents headed for primary care practice with an adequate ECG reading experience.

This book is intended as an ECG curriculum that emphasizes practice. My goal is to have you reading ECGs as quickly as possible. The introductory chapters are shorter than those found in the usual beginner's manual, but there is plenty there to get you started. Where you want additional depth, refer to an encyclopedic text in the library.

The practice ECGs include clinical data and questions that are designed to make teaching points. My brief discussion emphasizes daily issues in clinical medicine, as well as material that you may encounter on Board exams (Internal Medicine, Family Practice, Flex, and National Boards). Spend five evenings with these practice ECGs, and you will be far more comfortable than the average house officer with this basic part of the clinical examination.

Credit for the high quality of ECG reproduction in this book goes to Gordon Grindy and his colleagues at Marquette Electronics, Inc. My partner, Wes Moses, proofread the text and ECG interpretations, and I am also grateful to Dr. Hans Traberg who made useful suggestions for the 3rd edition. I again acknowledge that Marilyn Taylor is a patient woman, and I appreciate her forbearance during this writing adventure.

G.J.T.

How to Interpret ECGs

Normal Intervals

Heart Rate 60–99 beats/min

bradycardia <60 beats/min

tachycardia >100 beats/min

PR 0.12–0.21 sec

PR prolongation ≥ 0.22 sec

QRS < 0.12

QRS axis -30° to $+105^\circ$

QTc the corrected QT interval (calculated as $QT \div \sqrt{RR}$ interval).

It varies with age and gender, but is roughly <0.45 sec.

How to Interpret ECGs

Normal Intervals

Heart Rate 60–99 beats/min

bradycardia <60 beats/min

tachycardia >100 beats/min

PR 0.12–0.21 sec

PR prolongation ≥ 0.22 sec

QRS < 0.12

QRS axis -30° to $+105^\circ$

QTc the corrected QT interval (calculated as $QT \div \sqrt{RR}$ interval).

It varies with age and gender, but is roughly <0.45 sec.

Baseline Data

A Protocol for Reading ECGs

The protocol that you should follow when reading ECGs is outlined in Table 1.1. It is the approach cardiologists have taught generations of students, and it works. After reading ECGs for decades—and for a living—I still use it. With experience, I am good at pattern recognition. I glance at an ECG and promptly recognize major abnormalities. As you gain experience, you will develop this ability, and you will be tempted to focus immediately on the gross abnormalities that seem to jump out of the page. Resist that temptation! Do what the pros do, and make yourself follow the steps outlined in Table 1.1. Regardless of your ability and experience, if you do not focus on the rate, rhythm, intervals, and axis, you will miss subtle and important abnormalities. This is one of those areas of clinical medicine where you should not cut corners. Not addressing intervals, for example, would be like omitting the family history from a history and physical exam.

That analogy is a good one. The beauty of the history and physical examination format is that it allows you to collect meaningful data, even when the patient has an illness that you do not understand. Collecting basic data from the ECG serves a similar purpose for the novice.

How to Use This Book

First, read the introductory chapters that explain ECG findings and provide diagnostic criteria. Although useful, this exercise will not teach you how to read ECGs. You will take that step when you work through the practice tracings in Part II of this book.

When reading the unknown ECGs in Part II, *write* your interpretation. First, record rate, rhythm, intervals, and QRS axis. Then, analyze QRS and ST-T wave morphologies, and record your impression beginning with “ECG abnormal due to. . .” *If you do not commit yourself on paper, it does not count!* Finally, check your interpretation with mine, which is in Part III. Read five to ten tracings, or more, before checking answers. You will get into a kind of rhythm when you read ECGs without interruption.

Table 1.1 ECG Reading Protocol

The basics	Morphologic changes, interpretation
Rate	Conduction abnormality
Rhythm	Atrial abnormality
Intervals	Ventricular hypertrophy
QRS axis	ST segment—T wave changes
	Patterns of ischemia and infarction

Basic clinical data are provided with the ECGs, and I ask questions about management and diagnosis that go beyond the formal ECG report. Reading ECGs is a great opportunity to think (and teach) about heart disease, and I will not miss that opportunity here.

The remainder of this and the next chapter deal with each item on the ECG reading protocol (see Table 1.1). This book is for the near-beginner; most of you have had some introduction to the ECG. I will avoid lengthy description of technical areas such as the origin of lead systems. My goal is to provide brief yet clear explanations, and to get you through the introductory material as quickly as possible. Then it's on to the practice ECGs.

The ECG is a Voltmeter

It measures the small amount of voltage generated by depolarization of heart muscle. The vertical, or *y* axis, on the ECG is *voltage*, with each millimeter (mm) of paper equal to 0.1 millivolt (mV) (Fig 1.1). For practical purposes, we often refer to the amplitude, or height, of an ECG complex in millimeters of paper rather than in millivolts. At the beginning or end of the ECG, you may see a square wave, machine induced, that is 10mm tall; this is a 1-mV current entered by the machine for calibration. The gain can be changed so that high-voltage complexes fit on the paper, or so that low-voltage complexes are magnified. Changing the gain is uncommon, but it would be apparent from the calibration marker.

Voltage may have either a negative or a positive value. This is because voltage is a *vector* force with *direction* as well as amplitude. All the rules of vector analysis apply.

Note that the wave of depolarization moves through the heart in three dimensions, but that each ECG lead records it in just one dimension, between two poles. Having 12 leads grouped in frontal and horizontal planes allows us to reconstruct electrical events in three dimensions (Fig 1.2). The vectorcardiogram, popular 40 years ago and seldom used now, displayed the wave of depolarization in three dimensions, using *x*, *y*, and *z* axes.

On the ECG, when the wave of depolarization moves toward the positive pole of an individual lead the deflection is upright, or positive. For example, if depolarization progresses from the right side of the heart to the left, the net voltage is positive in lead I (Fig 1.2). Downward deflections are negative. The general direction of the wave of depolarization, the orientation of its vector in space, is referred to as the *electrical axis*. Depolarization of the atria progresses from the upper right toward the lower left, so the

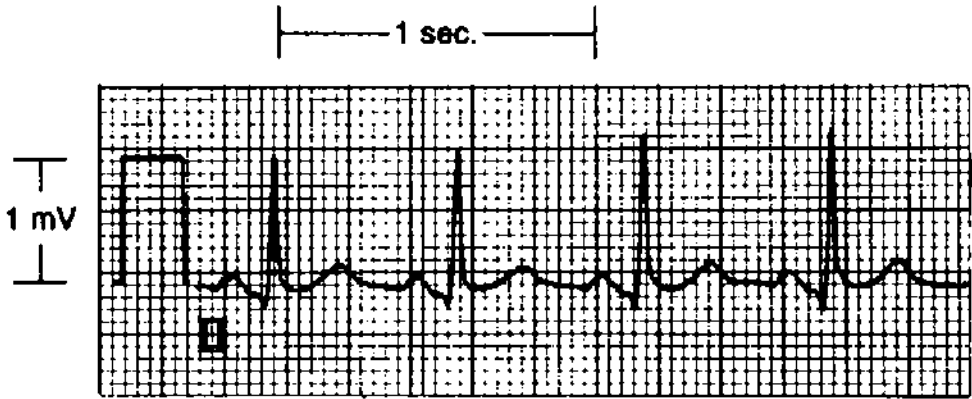


FIGURE 1.1 The square wave at the beginning is a 1-mV calibration marker. At full standard, 10 mm of paper = 1 mV of current. The ECG paper runs at 25 mm/sec. Thus, each millimeter = 0.04 second, and each large square (5 mm) = 0.2 second. The time between two positive deflections, or R waves, is the *RR interval*. If that is 1 second, the heart rate is 60 beats/min. This patient's heart rate is 100 beats/min (60 seconds per minute \div 0.6 second per beat).

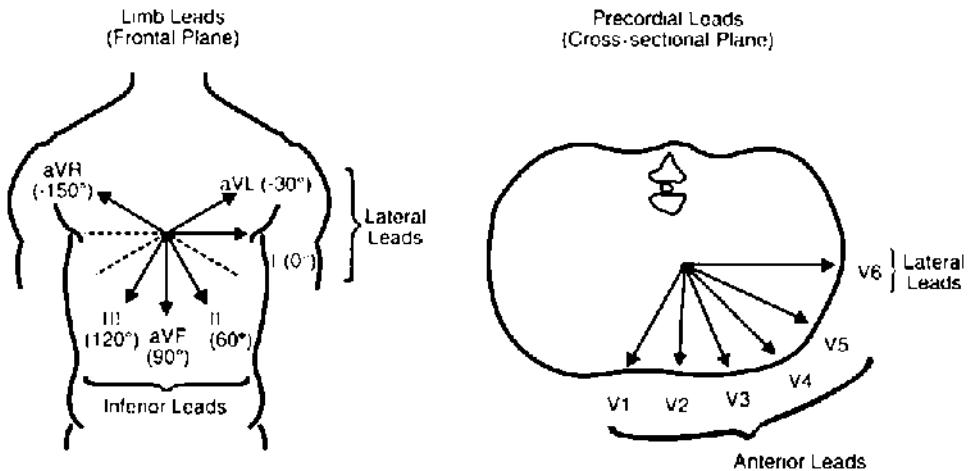


FIGURE 1.2 Spatial orientation of the 12 ECG leads. Each of the ECG leads functions as a voltmeter and has spatial orientation (as voltage is a vector force). Leads that have an inferior orientation are best at detecting changes from the inferior surface of the heart. Anterior precordial leads are most sensitive in detecting anterior wall changes, and the lateral leads, lateral wall abnormalities.

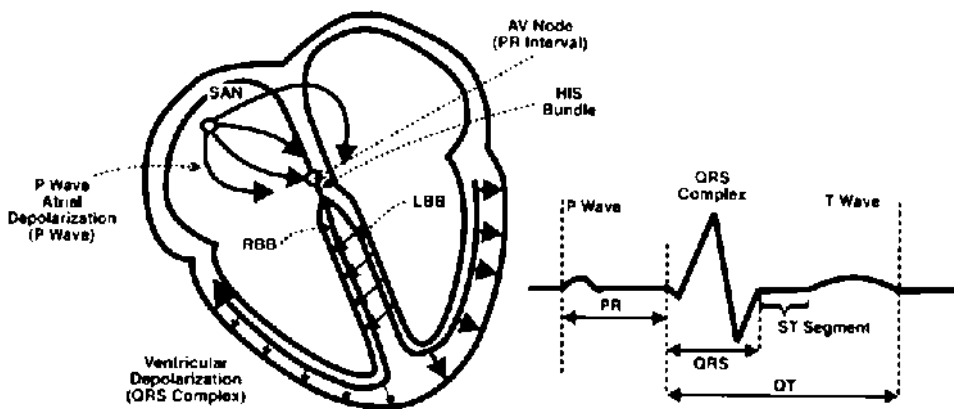


FIGURE 1.3 Sequence of cardiac activation. The sinoatrial (SA) node, located in the high right atrium, is the cardiac *pacemaker*. It fires at a rate of 60 to 100 beats/min, and the rate is influenced by both sympathetic and parasympathetic tone. Atrial muscle depolarization produces enough current to cause a deflection on the surface ECG, the P wave. The wave of depolarization is funneled into the atrioventricular (AV) node, located near the junction of the atrial and ventricular septa. Current is delayed in the AV node, producing the PR interval. This delay allows time for atrial contraction (which completes ventricular filling). Current exits the AV node into the bundle of His, which then divides into the left and right bundle branches. Initial depolarization of the interventricular septum takes place from the left to the right side. Current then moves simultaneously through the left and right bundle branches into the ventricular myocardium, producing the QRS complex. The left ventricle (LV) is much thicker than the right and thus generates more voltage. LV depolarization dominates the QRS complex. The ventricles are then repolarized, producing the T wave on the ECG. Normally, no voltage is apparent between the end of the QRS and the T wave. This ST segment may shift up or down with myocardial ischemia.

normal P wave axis is about 60° . Measurement of the QRS axis is discussed at the end of this chapter.

The ECG records the voltage generated by depolarization of the different regions of the heart *through time*. Following discharge of the sinoatrial (SA) node, the atria are depolarized (the P wave, Fig 1.3). Current then passes through the atrioventricular (AV) node, where there is delay (the PR interval). When the *wave of depolarization* exits the AV node, it passes through the His bundle, then the bundle branches, and on to the ventricles. Discharge of the muscular ventricles produces the QRS complex. This is followed by repolarization of the ventricles (T wave).

Measuring Heart Rate

On older ECG machines, the paper moved at an arbitrarily set speed of 25 mm/sec. On current machines the paper is stationary and the stylus moves at 25 mm/sec, yet we customarily refer to “paper speed.” At this speed, each millimeter of ECG paper is equal to $1/25$, or 0.04 second (see Fig 1.1). ECG paper is boldly ruled at 5-mm, or 0.2-second, intervals. And 5 of these large (5-mm) squares equals 1 second—straightforward arithmetic. Using this, there are a couple of fast ways to calculate heart rate when the rhythm is regular.

1. Check the distance (that is to say, the time) between two R waves. (The R wave is the dominant and easily identified positive (upright) wave or *deflection* in the QRS complex [see Fig 1.1].) That is the time for one cardiac cycle, or one heartbeat, and it is called the **RR interval**. If the RR interval is 5 large squares, or 1 second, then one heartbeat takes 1 second, and the rate is 60 beats/min. If the RR interval is 4 squares, or 0.8sec/beat, then the heart rate is 60sec/min divided by 0.8sec/beat, which equals 75 beats/min. Three squares: $60 \div 0.6 = 100$ beats/min.
2. A simpler way to do the arithmetic, and the way I determine rate quickly, is to measure the number of large squares between R waves, then divide that into 300: for 2 large squares, rate = 150 beats/min; 3 squares, rate = 100 beats/min; 4 squares, rate = 75/min; 5 squares, rate = 60/min; 6 squares, rate = 50/min; 5.5 squares, rate = between 50 and 60/min. When the rhythm is regular, I select an easily identifiable R wave that falls on, or near, a boldly scored line, then count the number of large squares to the next R wave. It is a crude but fast way to measure rate, but it does not work when the rhythm is grossly irregular. In most cases, it allows you to determine quickly whether the patient has a normal rate, **bradycardia** (less than 60 beats/min), or **tachycardia** (more than 100 beats/min).

Intervals

After emphasizing the importance of following the reading protocol (see Table 1.1), I am already violating it by considering intervals before rhythm. This is useful, however, because the intervals are at times necessary to determine rhythm. First, let us review events of the normal cardiac cycle and the basic ECG nomenclature.

Depolarization of the SA node normally initiates the cardiac cycle (see Fig 1.3). This neural structure is small, and its depolarization generates a small amount of current that cannot be seen on the surface ECG (e.g., the 12-lead ECG measured from the surface of the body). The wave of depolarization spreads through both left and right atria, producing the P wave (see Fig 1.3).

Although the atria and ventricles have a broad area of surface contact, they are effectively insulated from each other by connective tissue. The wave of depolarization from the atrium is funneled through what I think of as a hole in the insulation, but it is actually specialized conducting tissue called the atrioventricular (AV) node. Current moves rapidly along nerves and fairly quickly through heart muscle. But the AV node puts the brakes on the wave of depolarization. This slowing creates a delay between atrial depolarization and ventricular depolarization. A pause in the AV node gives the atria time to contract, providing the final increment of ventricular filling. According to Dr. Starling, that is important; he discovered that greater ventricular volume—or individual muscle fiber length—at the beginning of ventricular contraction produces stronger contraction.

PR Interval

The interval that includes a measure of the AV node conduction delay is the PR interval (see Fig 1.3). It is often easier to identify the beginning of the P wave than its end,

and by convention, this interval is measured from the start of the P wave. The interval thus includes the time of atrial depolarization, the P wave itself, and the delay during AV node conduction (roughly the time from the end of the P wave until the beginning of the QRS complex). However, when the PR interval is prolonged, it is usually a result of delayed AV node conduction; I know of no condition that lengthens the P wave enough to cause prolongation of the PR interval.

A common question is *which ECG lead to use* for measuring the PR or other intervals. What you are trying to measure with the PR interval is the time from initiation of atrial depolarization until the beginning of ventricular depolarization. There are slight variations in the sensitivities of particular ECG leads for recording the onset of the P wave, and which lead is most sensitive will vary from patient to patient. It makes sense to use the lead that records atrial depolarization earliest and ventricular depolarization earliest.

Do you get the feeling that these are rough measurements, despite the fact that we are dealing with milliseconds and microvolts? The truth is that they are, and that the surface ECG is a crude tool. As a practical matter, measure intervals from a lead where the onset of the waves—P and QRS—is well defined, and where the interval seems longest. This general rule applies to the measurement of all intervals.

The normal PR interval ranges from 0.12 to 0.22 second (see page 1). First-degree atrioventricular block (1° AV block) is defined as a PR interval of 0.22 second or more.

QRS Duration

Ventricular depolarization produces the QRS complex, the largest deflection on the ECG (Fig. 1.4, and see Fig 1.3). As a rule, the voltage generated is proportional to the amount of muscle depolarized, and the ventricles contain the bulk of cardiac muscle.

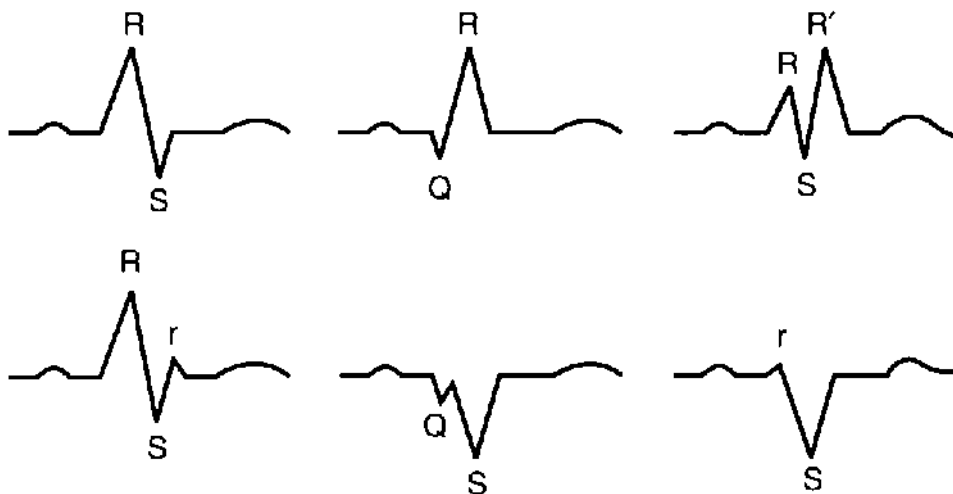


FIGURE 1.4 QRS nomenclature. Any positive deflection is an R wave. An initial negative deflection is a Q wave. A negative deflection following an R wave is an S wave. Small, low-voltage deflections may be designated with lowercase letters. When there are two R waves separated by an S wave, the second may be referred to as R' (R prime).

QRS nomenclature may seem confusing at first, but it follows quite simple conventions (Fig 1.4).

The *QRS duration*, or interval, is a measure of the time it takes to depolarize the two ventricles. Look again at Figure 1.3. Current exits the AV node and the His bundle and moves *simultaneously* through the infranodal bundle branches. Normally, the ventricles are activated *at the same time*, and the time of ventricular depolarization is roughly the duration of the QRS.

On the surface ECG, measure the QRS duration where it seems longest and where the beginning and end of the QRS are obvious. The normal duration is less than 0.12 second (3 mm). There are no illnesses that cause pathologic shortening of the QRS complex.

T Wave and the QT Interval

Repolarization, or the return of muscle to its resting state, spontaneously follows depolarization in heart muscle. Repolarization of the thin-walled atrium produces no apparent deflection on the surface ECG. Repolarization of the ventricles produces the *T wave*. This usually has the same axis as the QRS complex; that is to say, in ECG leads where the QRS complex is positive, the T wave is positive as well.

The QT interval is measured from the *beginning* of the QRS complex to the end of the T wave (see Fig 1.3). Why measure from the beginning of the QRS, apart from convention? It is probably because the beginning of the QRS often is easier to identify than the end, and the QRS complex is short relative to the duration of the QT interval. Measure the QT interval using the lead where it seems longest.

The normal duration of the QT interval varies with heart rate. The corrected QT (QTc) is calculated using Dr. Bazett's formula:

$$QTc = QT \div \sqrt{RR \text{ interval}}$$

The RR interval, or the duration of one cardiac cycle, is a measure of heart rate. Therefore, when the heart rate is 60 beats/min, and the RR interval is 1 second, the QTc equals the measured QT. When the heart rate is greater than 60 beats/min and the RR interval is less than 1 second, the QTc will be greater than the measured QT. Most ECG manuals provide tables that give the top-normal QT (measured) for a given heart rate, and these tables are based on Bazett's formula with a top normal QTc that is roughly 0.45 sec. The normal range varies with age and gender.

There is a quick and easy method for determining whether the QT interval is normal, and it is the method I use when plowing through a stack of ECGs. If the measured QT is less than half the RR interval, then it is probably normal. If it is clearly longer, then it is probably abnormal. Using this shortcut, my ECG interpretation usually reads "QT normal for the rate" or "QT prolonged for the rate." In borderline situations I calculate the QTc. The QTc provided by the ECG computer is occasionally inaccurate. Particularly with rapid heart rates, there is a tendency to overdiagnose QT prolongation, even with careful measurement.

The T wave may contain a second hump, or even a separate wave, which is called

the U wave, and this is a part of the ventricular repolarization process. It may be a normal finding. There is general agreement that it should be considered a part of the T wave when thinking of QT, or QTU, prolongation. Hypokalemia, especially in combination with hypomagnesemia, causes an increase in U wave amplitude and prolongation of the QTU interval.

QT interval prolongation is important. You will miss it unless you look for it on every ECG you read. One place you will see it is on Board exams. Conditions and drugs that prolong the QT interval are summarized in Table 1.2.

Table 1.2 Conditions and Drugs Affecting ECG Intervals

Interval	Condition	Drugs/metabolic abnormality
PR	1° AV block	Digoxin, β-adrenergic blockers, calcium channel blockers, intravenous adenosine
QRS	Ventricular conduction abnormalities, including bundle branch block; pre-excitation	Quinidine, flecainide, propafenone and other antiarrhythmics; extreme hyperkalemia
QT/QTU	Myocardial ischemia, hypothermia, intracranial bleeding, long QT syndrome	Quinidine, procainamide, disopyramide, sotalol, amiodarone, phenothiazine and phenothiazine derivatives, erythromycin; hypokalemia, hypomagnesemia, hypocalcemia

PATHOPHYSIOLOGY

Recall the shape of the action potential of isolated nerve or muscle cells. Repolarization (the return of the cell membrane to resting potential after depolarization) is a brief event, a sharp downward deflection. However, the repolarization wave on the surface ECG is broad. That is because the T wave is generated by repolarization of the large population of cardiac cells, some of which repolarize early and others much later. Doesn't the T wave look like a bell-shaped curve? In a sense it is, with the average cell repolarizing at the peak of the T wave. A broader T wave indicates greater heterogeneity of the repolarization process among cardiac muscle cells so that it takes longer (electrophysiologists call this temporal dispersion of refractoriness).

This is clinically important because increased heterogeneity of repolarization is the substrate for reentry, which is the mechanism of most ventricular tachyarrhythmias. A long *QT interval* (a measure of the duration of repolarization) may identify the patient at risk for ventricular arrhythmias and sudden death (Table 1.2).

The QT prolongation of hypocalcemia is an exception, with somewhat less risk. That is probably because the heterogeneity of ventricular repolarization is less affected. This is the only cause of QT prolongation where the duration of the T wave is not prolonged—a normal T wave just occurs later.

Rhythm

My purpose is to help the student read through a stack of ECGs in the heart station (and look good to the attending). I will review *selected rhythms* common in this setting, but I will not attempt a comprehensive discussion of the rhythm abnormalities that you will encounter in telemetry units.

Sinus Rhythm and Sinus Arrhythmia

Normal sinus rhythm is a regular rhythm between 60 and 100 beats/min, with a P wave before each QRS complex and a QRS after each P wave. A faster rate defines *tachycardia* and a slower rate, *bradycardia*. The term *sinus* indicates that the rhythm originates in the sinoatrial (SA) node, that there is atrial depolarization (a P wave before each QRS), and that atrial contraction precedes ventricular contraction.

CLINICAL INSIGHT

When you are excited, or when you walk up stairs and are short winded and your pulse is 120 beats/min, you have *sinus tachycardia*. This usually is a benign rhythm, but not always. It is a normal response of healthy people to exercise. But sinus tachycardia in a patient who is at rest and pain free the day after an MI may indicate severe left ventricular dysfunction. Cardiac output = stroke volume \times heart rate. A depressed left ventricle generates less stroke volume, and increasing the rate is the first compensatory response to maintain output. Although a heart rate >90 beats/minute does not require specific treatment, it is a marker of decompensation and poor prognosis in patients who have had an MI and in those with congestive heart failure. Do not overlook other illnesses that may cause sinus tachycardia, such as thyrotoxicosis, anemia, and fever. It may also be caused by drugs, such as thyroid hormone, catecholamines, caffeine, and amphetamines.

Sinus bradycardia is a common finding. In the absence of conduction abnormalities, when all the intervals are normal, bradycardia at rest is a normal variant. It usually indicates good cardiovascular fitness, and it is common in trained athletes. It can be a drug effect (digitalis, β -adrenergic blockers, or the calcium channel blockers diltiazem and verapamil). A variety of illnesses can cause sinus slowing, including the sick sinus syndrome, hypothyroidism, sleep apnea, and other conditions that cause hypoxemia. Vasovagal attacks may include profound sinus bradycardia, sinus pauses, and syncope.

Sinus Arrhythmia

During the respiratory cycle, the vagus nerve is intermittently activated, producing a beat-to-beat variation in heart rate. On the 12-lead ECG (which is a relatively short rhythm strip), this is seen as a variable RR interval. When pronounced, it may affect your quick and easy calculation of heart rate using the technique just described. Be aware of this, but do not worry as long as the rate is within the normal limits.

Sinus arrhythmia usually indicates good cardiovascular health. It disappears when the heart is sick, as in the case of heart failure. The autonomic nervous system

CLINICAL INSIGHT

In addition to heart disease, *autonomic dysfunction* may also reduce heart rate variability, but with no increased risk of ventricular arrhythmias. This generally occurs in illnesses that cause peripheral (sensory) neuropathy, including alcoholism, diabetes, uremia, and Guillain-Barré syndrome. Dysfunction of medullary centers that control autonomic function may also reduce heart rate variability, such as cerebral hypoxia. It is a minor criterion for determining brain death.

compensates for low cardiac output by suppressing the parasympathetic nervous system as well as increasing sympathetic tone. Resting heart rate increases. In addition, the vagus nerve is not activated during the respiratory cycle, so there is little if any variation in RR intervals. The rhythm becomes perceptibly more regular.

Precise quantification of sinus arrhythmia, or *heart rate variability (HRV)*, has emerged as a noninvasive test for increased risk of ventricular arrhythmias. It is not that vagal activity prevents dangerous ventricular arrhythmias. Rather, an active vagus nerve indicates good left ventricular function and therefore a low risk of arrhythmias. Those with low HRV (reduced vagal tone) usually have poor left ventricular function and an increased risk of ventricular arrhythmias and sudden cardiac death. HRV may be measured by calculating the mean and standard deviation of a large number of RR intervals; the standard deviation serves as a measure of the variability.

Heart Block

Block can be a confusing term in cardiovascular medicine. Blocked arteries, blocked valves, and blocked nerve conduction are different illnesses, and they may be confused by patients (and medical students). The term *heart block* usually refers to interruption of nerve conduction. It is an electrical problem, not one of fuel lines or valves (although these conditions may coexist).

Nerve conduction can be interrupted, or blocked, at any level of the cardiac nervous system (Fig 1.3). Block is uncommon within the SA node or in the body of the atrium. But it is quite common in the AV node and in the nerves below the AV node (Fig 1.3). These infranodal nerves include the His bundle, the bundle branches and their major divisions, and the small terminal Purkinje fibers. The infranodal nerves may be referred to as the *His-Purkinje system*.

Blocked conduction may alter intervals and may cause bradycardia. When block is complete, there is no transmission to structures distal to the block, but the heart rarely stops. Instead, an *auxiliary* pacemaker just below the level of block takes over. The intrinsic rate (the rate of spontaneous depolarization) of the takeover pacemaker is progressively slower the farther it is from the SA node. Control of heart rate reminds me of the children's game, King of the Mountain. Pacers highest on the mountain, nearest the SA node, get the first chance to rule. When they fail, those just below take over. As you go lower down the mountain, the pacers are slower.

For example, when complete block occurs in the AV node, a pacemaker in the His bundle, just below the AV node, takes over with an intrinsic rate of 30 to 45 beats/

CLINICAL INSIGHT

In addition to a slower intrinsic rate, takeover pacemakers from within the body of the ventricle are less responsive to the autonomic nervous system. A pacemaker in the AV node, or just below it, usually responds to catecholamine infusion with an increase in rate. But deeper, ventricular pacemakers are unresponsive to sympathetic stimulation, and heart rate does not increase. Furthermore, drugs that suppress premature ventricular contractions, such as lidocaine, may also suppress a takeover pacemaker originating from ventricular muscle. I recall an inexperienced colleague treating “slow ventricular tachycardia” with lidocaine, and the patient developed asystole.

min. It would be hard to exercise with a heart rate that slow, but syncope is uncommon. If complete block occurs farther down, within the septum and beyond the division of the two bundle branches (see Fig 1.3), the takeover pacemaker is in the body of the ventricles. These deeper pacers have a much slower intrinsic rate, occasionally as slow as 10 to 20 beats/min. In this case, syncope and even sudden death are more likely.

From this outline of general principles, you begin to see that the level of block determines prognosis, and identification of this level is critical. Now we turn to specific ECG findings and clinical situations.

First-Degree AV Block

First-degree AV block is defined as a PR interval of 0.22 second or more, and without variation (Fig 1.5). It is caused by a delay in conduction in the AV node. Increased vagal tone, hyperkalemia, digitalis, calcium blockers (particularly diltiazem and verapamil), and β -adrenergic blockers all may slow AV node conduction. It is common in elderly patients, who may have degeneration of the AV node in the absence of ischemic heart disease. In other patients, ischemia may injure the AV node and either delay or block conduction. The right coronary artery usually supplies the AV node as well as the inferior wall of the heart, and AV nodal block is common with inferior myocardial infarction (MI).

CLINICAL INSIGHT

An underappreciated physical finding that accompanies PR interval prolongation is a soft first heart sound (S_1). Because of delayed conduction between atria and ventricles, contraction of the ventricle is much later than usual. During this delay, atrial contraction finishes, and the mitral and tricuspid valves drift toward the closed position. When the ventricles finally contract the valves do not have as far to travel, so the closure sound is softer. This is one of the few causes of a soft S_1 .

Second-Degree Heart Block, Mobitz I and II Block

With second-degree AV block, some beats pass through the AV node to the ventricles but others do not. This follows a pattern: when every other P wave captures the




FIGURE 1.5 First-degree AV block. The PR interval is longer than 0.22 second, and it does not vary.

ventricle (producing a QRS complex), the patient is said to have 2:1 block. When every third P wave is conducted through the AV node, it is 3:1 block; and when two of three P waves are conducted, it is 3:2 block.

Second-degree heart block is further classified into two types: **Mobitz I and II**. This is a source of confusion. I find it easier to remember without the Mobitz designations, instead thinking anatomically of where the conduction system block occurs.

Mobitz I block occurs within the AV node (exceptions are rare.) Injury to the node causes it to tire with each succeeding beat until it is so tired that a P wave is completely blocked. On the ECG, we observe the *Wenckebach phenomenon*: progressive

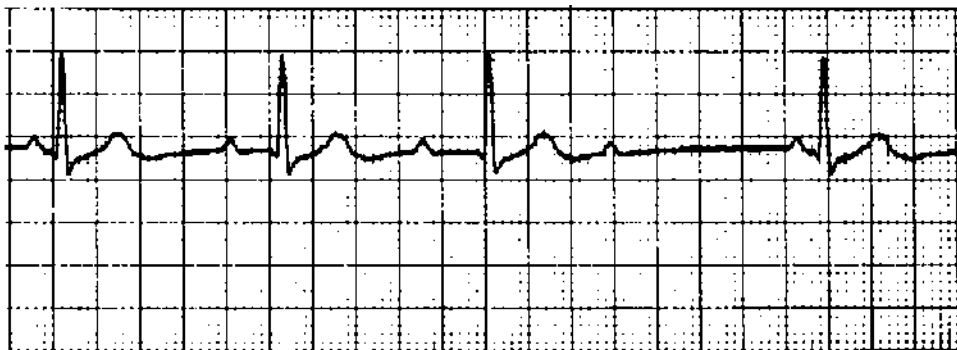


FIGURE 1.6 Second-degree AV block, Mobitz type I (or Wenckebach). The level of block is the AV node. There is progressive lengthening of the PR interval until the P wave is not conducted. After the dropped beat, the PR interval is short (the AV node has had time to recuperate). An additional feature, not mentioned in the text, is progressive shortening of the RR interval before the dropped beat. Note that the QRS complex is narrow, more evidence that the level of block is the AV node.

CLINICAL INSIGHT

Think of Mobitz I or Wenckebach when you see group beating (groups of QRS complexes regularly separated by pauses). Then look for progressive prolongation of the PR, then a P wave not followed by a QRS, and then a shorter PR interval following the blocked beat. The diagnosis is supported by a narrow QRS complex, since the level of block is the AV node.




FIGURE 1.7 Second-degree AV block, Mobitz type II. The patient initially drops a single beat, and this dropped beat is an example of Mobitz II block. He then goes into complete heart block. The last beat is a ventricular escape beat. The PR interval of conducted beats is fixed; there is no evidence of the Wenckebach phenomenon. In addition, the QRS complex is wide; the 12-lead ECG showed bifascicular block (Chapter 2). A wide QRS, indicating abnormal intraventricular conduction, is invariably seen in patients with infranodal heart block.

prolongation of the PR interval until there is a P wave that is blocked and not followed by a QRS (Fig 1.6). Notice that the PR interval of the beat following the blocked beat, or pause, is shorter. The AV node apparently recuperates during the pause. Often this short PR is the best evidence of Wenckebach, and can be used to make the diagnosis even when progressive PR prolongation is subtle and not certain.

Mobitz I block occurs at the level of the AV node, and the conduction system below the node may be normal. In fact, a *normal QRS duration* excludes block below the AV node. On the other hand, a wide QRS does not define block as infranodal. It is possible for a patient with a preexisting intraventricular conduction abnormality (and wide QRS) to develop AV nodal disease.

Mobitz II block, also a form of second-degree block, is caused by block *below the AV node*. The AV node may be healthy. With Mobitz II there is no progressive prolongation of the PR interval in the beats preceding the blocked beat (Fig 1.7). Because the infranodal conduction system is diseased, the QRS is wide, usually meeting criteria for bundle branch block. A narrow QRS excludes infranodal heart block. Mobitz II block often precedes symptomatic, complete heart block (see Fig 1.7) and is an indicator for pacemaker therapy.

2:1 AV Block—Is It Mobitz I or II?

Mobitz I second-degree AV block can be severe enough that every other beat is blocked (e.g., 2:1 AV block). This would eliminate the variable PR interval as a diagnostic marker. In fact, 2:1 AV block is a common rhythm with digitalis toxicity; it is Mobitz I, as the level of block is the AV node. How do you know whether 2:1 block is Mobitz I or Mobitz II? One way is to get a long rhythm strip: with Mobitz I block, there may be brief sections where block will be less severe, with 3:2 or 4:3 conduction and typical PR interval findings of the Wenckebach phenomenon.

Another way to tell is to focus on the QRS duration. I repeat this because it is important (it will be the key to answering a Board question). When block occurs at the level of the AV node, the infranodal conduction system usually is healthy, the ventricles are activated in the normal sequence—that is, simultaneously—so the QRS duration is normal. When block occurs below the AV node (Mobitz II), the patient invariably has an intraventricular conduction abnormality such as bundle branch block, and the QRS duration is long.

PATHOPHYSIOLOGY

Here is how the electrophysiology laboratory assesses heart block. As noted, an elderly person with infranodal disease—bundle branch block—may develop a sick AV node and Mobitz I block. Whether it is really Mobitz I or II block can be sorted out in the electrophysiology lab, especially when there is uncertainty about a need for pacemaker therapy.

Depolarization of the proximal bundle of His, adjacent to the AV node, generates a small current that is not apparent on the surface ECG. This “H spike” can be measured with an electrode that is near it, using an electrode catheter positioned in the lower right atrium next to the tricuspid valve. The H wave allows partition of the PR interval into its nodal, and infranodal, or infra-His spike segments (Fig 1.8). Block in the node causes A-H interval prolongation, and block below the node—below the proximal His—causes H-V interval prolongation. Infranodal block identified by a long H-V interval is an indication for a pacemaker.

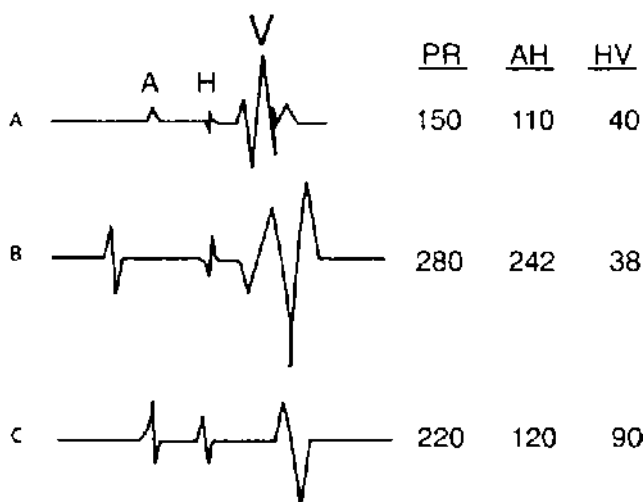

FIGURE 1.8 His bundle recordings from three patients. The goal of EPS when evaluating heart block is to determine the anatomic level of conduction delay. The His (H) spike is generated by depolarization of the His bundle, just below and adjacent to the AV node, and is recorded with a bipolar catheter positioned next to the tricuspid valve. The H spike essentially divides the PR interval into its AV nodal (the AH interval) and infranodal (HV) portions. Patient **A**: the PR interval is normal as is the HV interval (<55 msec). Patient **B**: A patient with first-degree AV block (long PR). Marked prolongation of the AH interval indicates that the level of block is the AV node. Infranodal conduction (the HV interval) is normal. Patient **C**: Another with first-degree AV block. The AH interval is normal, so there is no delay in conduction in the AV node. The prolonged HV interval indicates infranodal conduction delay. With infranodal disease there is a higher risk of developing symptomatic heart block. (Reproduced with permission from Taylor GJ. *Primary care management of heart disease*. St. Louis, MO: Mosby, 2000.)

Third-Degree, Complete Heart Block

Complete atrioventricular block is just that; nothing gets through to the ventricles. There are P waves and QRS complexes, but they are unrelated; this is called *AV dissociation* (Fig 1.9). The term is used when P waves are not followed by QRS complexes; the atria and ventricles operate independently. Complete heart block is just one of the conditions where this occurs, and you will encounter other examples in Chapter 2.

How do you know whether block occurs within the AV node itself, or in the infranodal conduction system? The issues are those discussed above with 2:1 AV block. When block is at the level of the AV node, the takeover pacemaker is just below the node, within the His bundle and before the division into the bundle branches (see Fig 1.3). The sequence of ventricular activation is therefore normal, and the QRS duration is normal (unless there is coexisting bundle branch block). Furthermore, the takeover pacemaker is relatively high in the conduction system and has an intrinsic rate ranging from 35 to 45 beats/min. The rate would probably increase with catecholamine infusion or administration of atropine.

When complete block develops in the infranodal conduction system, the takeover pacer is in the body of the ventricle, the QRS is wide, and the rate is low. This may be called an *idioventricular rhythm*, but it should not be mistaken as a ventricular

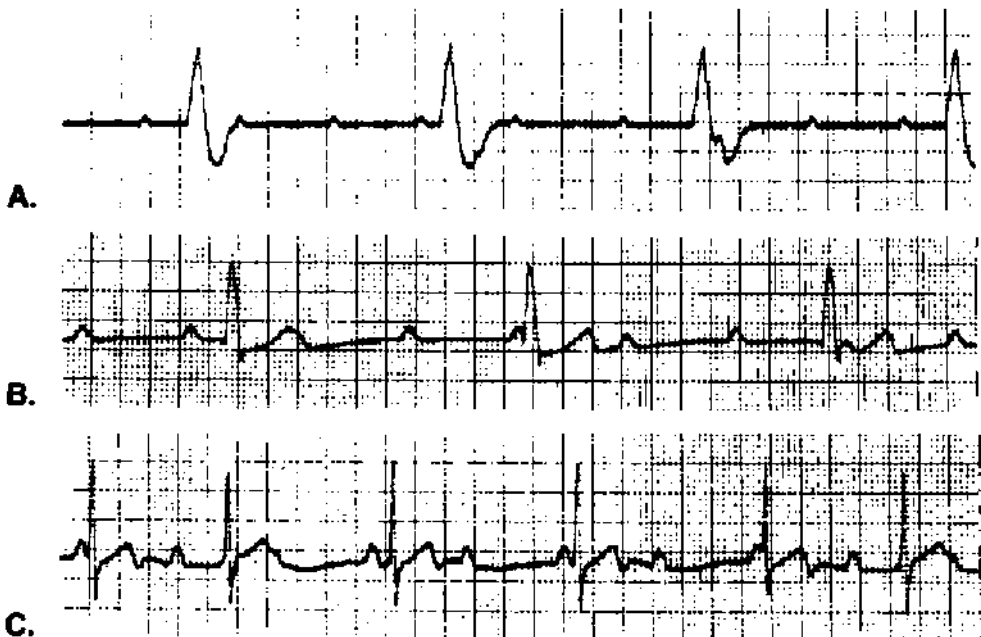


FIGURE 1.9 Three patients with complete heart block. The atria are being discharged at a regular rate (P waves) and the ventricles at a regular rate (QRS complexes). The two rhythms appear unrelated; there is *AV dissociation*. You may be tempted to say that P waves coming before QRS complexes could be conducted, but these do not alter the regularity of the ventricular escape rhythm. Patients **A** and **B** have wide QRS complexes and slow ventricular rates; they probably have block below the AV node, with a takeover pacemaker in the body of the ventricle. Patient **C** has a more rapid escape rate (55 beats/min), and the QRS complex is narrow; the level of block is the AV node.

PATHOPHYSIOLOGY

Infranodal complete heart block is common among elderly patients, and it usually causes syncope. It may also present as increased fatigue or heart failure. When I ask students about the cause of the arrhythmia the usual response is coronary artery disease (the default response when in doubt). But infranodal heart block in the elderly is rarely a complication of ischemic heart disease. In this age group, the cause is fibrotic degeneration of the infranodal nerves (“frayed wires”). The coronary arteries are often normal. A review of old ECGs usually shows evidence of infranodal conduction disease, with bundle branch block (Chapter 2). Infranodal complete heart block is an indication for pacemaker therapy.

arrhythmia. Suppressing it with an antiarrhythmic agent could lead to asystole and death. The idioventricular pacing rate does not increase following treatment with atropine or catecholamines.

Complete heart block may develop at the level of the AV node, but is uncommon. The usual situation is congenital heart block that is detected on a routine ECG in an asymptomatic young person (Fig 1.9C). The patient usually has a history of slow pulse, as the takeover pacemaker in the upper His system has a rate in the mid-40s. The heart rate may increase with exercise, although the response is subnormal. The QRS duration is normal. Pacemaker therapy is not required in the absence of symptoms.

Heart Block with Acute Myocardial Infarction

Heart block is a common complication of inferior MI, and it is uncommon with anterior MI (Fig 1.10). It helps to remember how the location of block determines the severity of the arrhythmia and prognosis. Heart block with *inferior MI* probably has dual causation. First, patients with inferior MI have high vagal tone, possibly related to the Bezold-Jarisch reflex. Second, there may be ischemia of the AV node, as the AV node is supplied by the same artery that feeds the inferior wall. You may expect the usual features of AV nodal block: PR interval prolongation and Mobitz I patterns are common, the QRS is narrow, and the takeover pacer is fairly rapid if block is complete. In addition, the AV node usually has collateral blood flow from other arteries, so permanent injury is uncommon and recovery of normal conduction is the rule. Permanent pacemaker therapy is rarely needed, although temporary pacing is indicated for symptomatic bradycardia. The heart rate usually increases with atropine therapy.

Anterior MI may injure the interventricular septum below the AV node, so the pattern of heart block is infranodal: Mobitz II block is the rule, the QRS is wide, and, when block is complete, the escape rhythm is slow. An anterior infarction large enough to cause infranodal block is usually huge, spontaneous recovery from the heart block is rare, and the prognosis is terrible. These patients need pacemakers, but despite pacing they do poorly because of the degree of LV injury.

Atrial Arrhythmias

Atrial arrhythmias may be chronic or acute. They are common, and you will see them almost daily when reading routine ECGs.








Location of Heart Block	Classification and ECG Appearance	QRS Duration	Origin of Escape Rhythm with Complete Heart Block	Prognosis	MI Location
 <p>● SAN BLOCK AVN AV Node Block</p>	<p>1 First degree AV Block PR > 0.22 sec</p>  <p>2 Wenckebach, Mobitz I Block</p>  <p>3 Complete heart block</p> 	Normal (< 0.12 sec) rarely has associated bundle branch block	AV Node Heart rate: 40 beats/min	Good (Usually spontaneous recovery)	Inferior MI (Right coronary artery supplies the AV node in 85%) Common
 <p>● SAN BLOCK AVN Infranodal Block</p>	<p>1 Mobitz II</p>  <p>2 Complete Heart Block</p> 	Wide (> 0.12 sec)	Ventricular Conduction System Usually Heart rate < 20 beats/min	Poor (Large MI, heart failure)	Anterior MI (Septal ischemia) Rare

FIGURE 1.10 Heart block after MI. It is important to distinguish between block at the level of the AV node and block below the AV node. The takeover pacemaker with AV nodal block has an adequate intrinsic rate and responds to atropine. Deep ventricular pacemakers that take over after infranodal block are less responsive and are too slow.

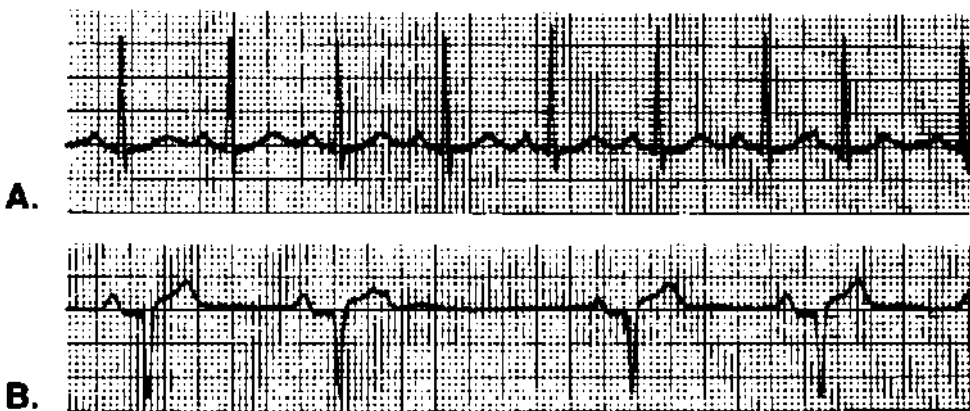


FIGURE 1.11 Two patients with premature atrial contractions. **A:** An ectopic P wave is seen before the premature QRS. **B:** Blocked PAC, causing a pause. The ectopic wave is seen as a distortion of the preceding T wave. This is a common cause of pauses. In most cases, the ectopic P wave is harder to see; look for subtle changes in the preceding T wave.

Premature Atrial Contractions

Usually premature atrial contractions (PACs), also called PABs (beats) or APBs, are easy to recognize. The premature beat has a narrow QRS, and the QRS is identical to normal beats. A misshapen, ectopic P wave may precede it (Fig 1.11).

A *blocked PAC* may be the cause of a pause on the ECG or rhythm strip, a pause that may be felt by the patient (see Fig 1.11). This happens when the PAC is early enough that the AV node is refractory and will not conduct it. The P wave that is blocked may be buried in the T wave of the preceding complex, making it hard to see. Look for subtle alteration in the T wave just before the pause. This is a favorite board question.

PACs are common in young, healthy people and do not indicate heart disease.

Paroxysmal Supraventricular Tachycardia

Paroxysmal supraventricular tachycardia (PSVT) is a rapid, regular rhythm with a rate of 120 to 200 beats/min. Most cases are caused by reentry within the AV node.

Reentry: Before going further with PSVT, we should discuss **reentry** as a mechanism of premature beats and tachyarrhythmias. The concept is one that is often misunderstood, but is actually quite simple (Fig 1.12). The reentrant “focus” is an island of cardiac tissue that is protected, or insulated, from surrounding tissue. Current enters one end of the focus and exits the other (conduction is unidirectional). Within the focus, conduction is much slower than conduction through the surrounding tissue. By the time current exits the focus, the surrounding tissue has depolarized and has had

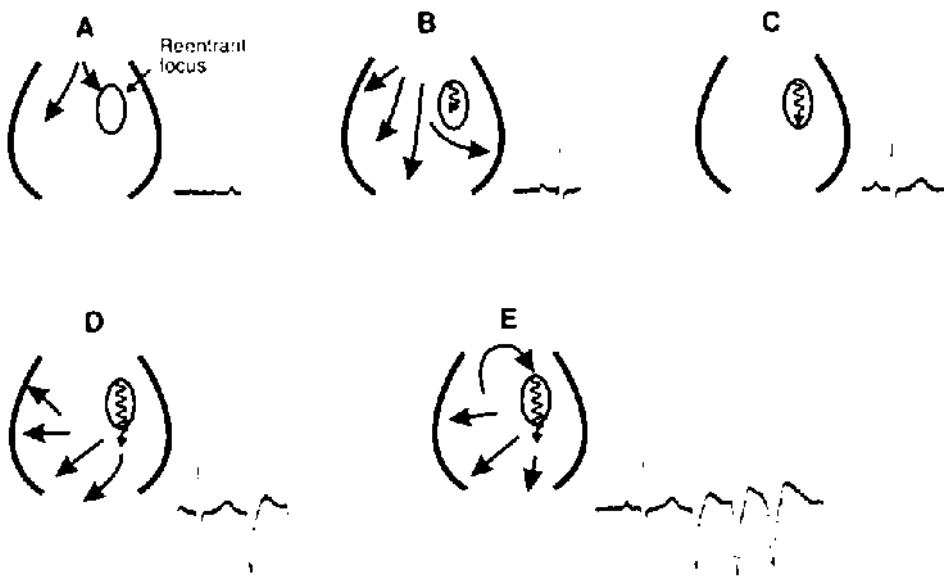


FIGURE 1.12 Reentry. Follow the sequence of events. **A:** The wave of depolarization comes from above (the atrium in the case of atrial arrhythmias, the ventricle in this case of ventricular reentry). **B:** As current moves through the myocardium, it also enters the reentrant focus, a region that is insulated from the surrounding tissue. **C:** Depolarization of the surrounding myocardium happens quickly, but conduction through the reentrant focus is slow. **D:** By the time current exits the reentrant focus, the surrounding tissue has been repolarized and is *vulnerable*. That is to say, it can be stimulated. This produces the *ectopic beat*. **E:** If the timing is perfect, current from the ectopic beat reenters the protected focus, travels through it, and again finds the surrounding tissue vulnerable when it exits. A circuit is established and the result is repetitive beats.

Characteristics of the reentrant focus that make this possible are as follows: (1) insulation from surrounding tissue, (2) unidirectional conduction, and (3) slow conduction.

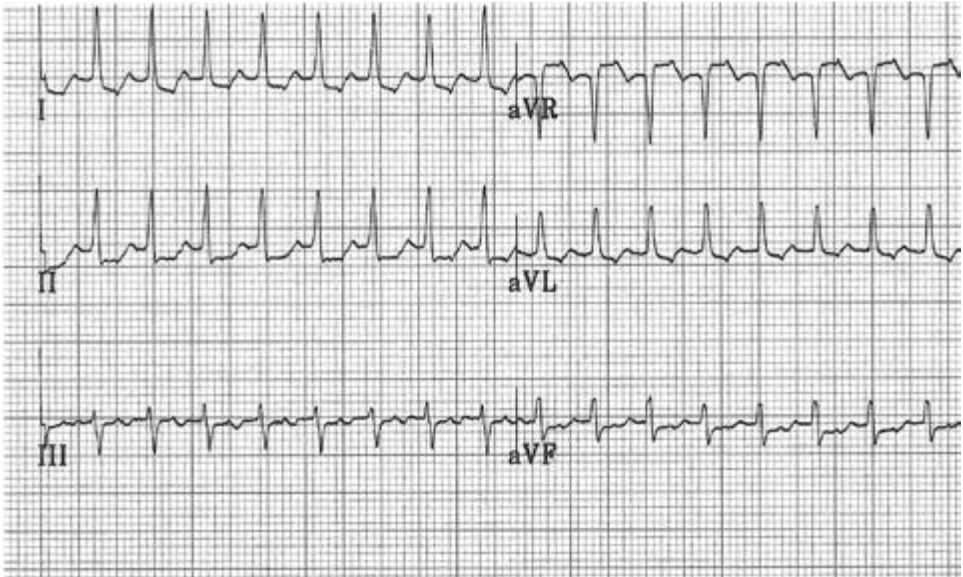


FIGURE 1.13 Paroxysmal supraventricular tachycardia, a recording of limb leads. The rate is 200 beats/min. The T waves appear distorted, and these distortions may be the ectopic P waves. This episode lasted 45 minutes, plenty of time to get an ECG.

time to repolarize as well. Thus, the current exiting the focus finds the surrounding tissue vulnerable, ready to be stimulated, and that is just what happens: a premature beat is generated. This seems to be the mechanism of many atrial and ventricular premature beats. A reentrant focus in the atrium would cause a PAC, and a focus in the body of the ventricle, a premature ventricular contraction (PVC).

If the timing is perfect, the premature beat may slip back into the entrance of the reentrant focus, leading to another or even to a series of ectopic beats. A circuit is created (see Fig 1.12E).

Now back to PSVT. In most cases, the reentrant focus is near or within the body of the AV node. Current exiting the reentrant focus is coming from the AV node and passes normally through the His bundle. The QRS complex is therefore narrow (unless there is coexisting bundle branch block). PSVT is thus a *narrow complex tachycardia* (Fig 1.13).

PSVT is a common and occasionally recurrent arrhythmia in otherwise healthy young people. It is not dangerous or fatal, but it can be bothersome, causing palpitations, dizziness, and near-syncope. It is uncommon for patients to lose consciousness. The arrhythmia may be interrupted with maneuvers that increase vagal tone, such as the Valsalva maneuver or carotid sinus massage. Adenosine blocks AV nodal conduction and is the treatment of choice in the emergency room. When symptoms are frequent or are not easily controlled by medical therapy, *ablation of the reentrant focus* within the AV node is possible using catheter techniques. This is a cure (we do not do much of that in cardiology), and many patients prefer this to life-long drug therapy.

CLINICAL INSIGHT

PSVT is a benign rhythm and rarely necessitates DC cardioversion. However, it is not benign when it causes severe hypotension or angina pectoris. Hemodynamic compromise or unstable, persistent angina is an indication for immediate cardioversion of any tachyarrhythmia, be it atrial or ventricular. It is a medical emergency. There is no time to wait for the cardiology consultant. If you delay, the patient may well need CPR before long. Set the defibrillator to “synchronize” and start with 50 joules, as low-voltage cardioversion may work for atrial arrhythmias.

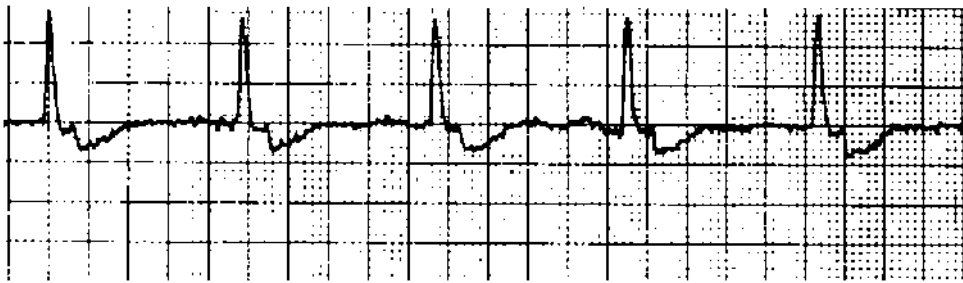


FIGURE 1.14 Nodal (or junctional) rhythm. The retrograde P wave distorting the T wave is prominent in this example. Usually it is more subtle, and it may be absent. Even without retrograde P waves, the diagnosis of junctional rhythm may be made when the rate is regular, is less than 100 beats/min, and there are no P waves. The QRS is usually narrow.

Nodal (or Junctional) Rhythm

Nodal (or junctional) rhythm is recognized by the absence of P waves before the QRS, and the rhythm is regular. Although tachycardia (rate ≥ 100) is possible, the heart rate usually is within the normal range. As stimulation of the ventricle comes from the AV node, the QRS is narrow. There may be retrograde activation of the atria, and inverted (*retrograde*) P waves may be seen distorting the T waves (Fig 1.14).

Atrial Fibrillation

It is a rare day that I read ECGs and do not see a few cases of atrial fibrillation (AF). A grossly irregular rhythm without P waves indicates the diagnosis (Fig 1.15). The rate is usually less than 120, as most patients with chronic AF have already had the ventricular rate, or *response*, controlled with drugs that slow AV nodal conduction (e.g., digoxin, β -adrenergic blockers, or the calcium blockers verapamil and diltiazem). Students often are fooled by more rapid rates in which the irregular irregularities may be subtle (see Fig 1.15). AF is not an example of AV dissociation. The atria may be beating (or fibrillating) at rates as high as 600 beats/min, but the ventricle is stimulated (captured) by atrial beats that traverse the AV node. Fibrillation waves may be low voltage and invisible, but often they are coarse enough to distort the baseline (Fig 1.15).

Atrial Flutter

Atrial flutter is a regular rhythm. The atrial rate is typically 300 beats/min. A patient with a ventricular rate of 150/min has 2:1 AV block; 3:1 AV block produces a

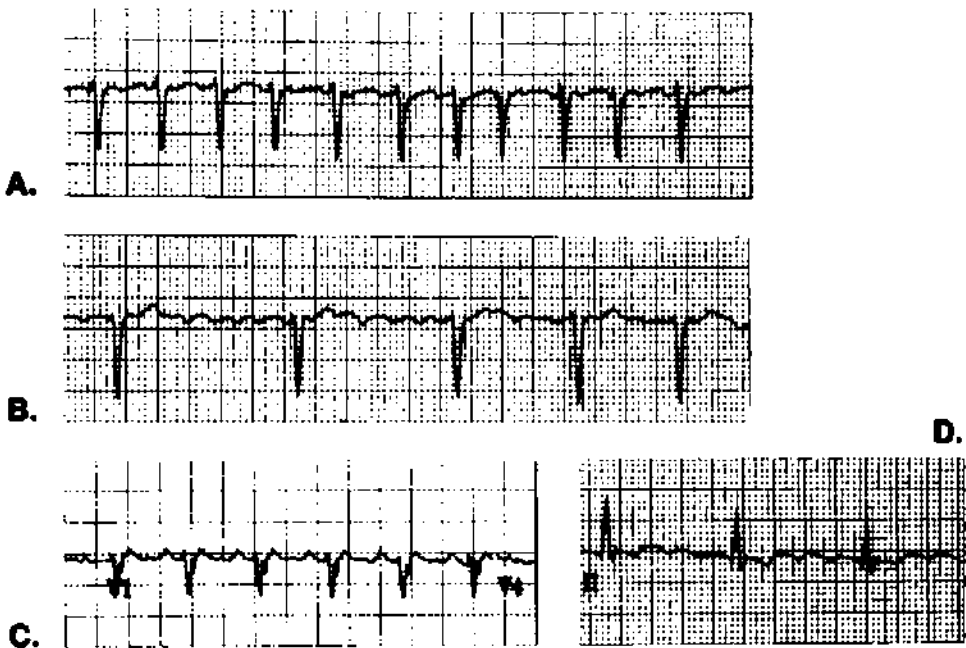


FIGURE 1.15 Four patients with supraventricular tachyarrhythmia. **A:** Atrial fibrillation (AF) with rapid ventricular response; at higher rates, the variation in the RR interval seen with AF may be subtle. **B:** AF with a controlled ventricular response; with drug therapy to slow AV node conduction, the ventricular rate is kept between 80 and 100/min. In this case, you can see the fibrillation waves as coarse undulation in the baseline. **C:** Atrial flutter with 2:1 block; note the saw-tooth pattern in the baseline. **D:** Atrial flutter with 4:1 block; the flutter waves are more obvious.

ventricular rate of 100/min. Flutter waves with a saw tooth appearance are usually apparent in at least one ECG lead (see Fig 1.15). When you see a regular rate of 150/min on a telemetry rhythm strip, think of atrial flutter and order a 12-lead ECG to look for flutter waves.

At times, flutter waves (which are P waves) cannot be seen on the surface ECG, and it is not possible to tell whether the patient has atrial flutter or PSVT because both are narrow QRS complex tachyarrhythmias. If the rate is 140/min or 160/min, it probably is not flutter. But at a rate of 150/min it could be either. Placing an ECG lead closer to the heart, using an esophageal or right atrial electrode, allows detection of P waves. In fact, the P waves are larger than QRS complexes when measured from the right atrium and easy to see. With PSVT, there is one P wave with each QRS, and with flutter there are two or more for each QRS. You will not see flutter with 1:1 conduction and a ventricular rate of 300/min. If and when that occurred, a heart rate of 300 beats/min would be too rapid to allow diastolic filling and would lead to hemodynamic collapse.

Atrial flutter, like AF, is not an example of AV dissociation. There is a definite relationship between atria and ventricles, with P waves intermittently getting through the AV node and stimulating the ventricles.

CLINICAL INSIGHT

New atrial flutter in an elderly, bedridden patient with minimal symptoms may be an early sign of pulmonary embolus which has caused right atrial overload. One of my teachers suggested thinking of flutter as a rhythm indicating right atrial disease and AF as a left atrial arrhythmia. I realize that this is a bit simplistic, and that patients with left heart failure can have atrial flutter. Nevertheless, it is interesting how often flutter complicates pulmonary problems such as obstructive lung disease or pulmonary embolus. AF, on the other hand, is a common complication of hypertension, a left-heart problem. Furthermore, atrial flutter is ablated by creating a burn in the right atrium. The mild burn works like insulation, interrupting the arrhythmia's circuit. AF ablation involves creating a burn line around the origin of the pulmonary veins in the left atrium.

Pre-excitation and the Wolff-Parkinson-White Syndrome

The reentrant tachyarrhythmias caused by the preexcitation syndrome are common, and this topic is a favorite of board examiners. I like it as a Board question because understanding it indicates a feeling for reentry.

Normally, there is a layer of connective tissue separating the atria and ventricles that serves as insulation, preventing free passage of electrical impulses between the upper and lower chambers (Fig 1.16). The AV node is the normal passage through this layer of insulation. Pre-excitation of the ventricle occurs because of an additional defect in the insulation between atria and ventricles. This defect is called a *bypass tract*, or *accessory pathway*. Bypass tracts have been identified at multiple locations within this region of surface contact between atria and ventricles. Wolff-Parkinson-White (WPW) syndrome refers to the most common of these bypass tract locations, and *pre-excitation* is the more generic term for any syndrome involving a bypass tract between atria and ventricles (WPW syndrome is thus a subset of pre-excitation).

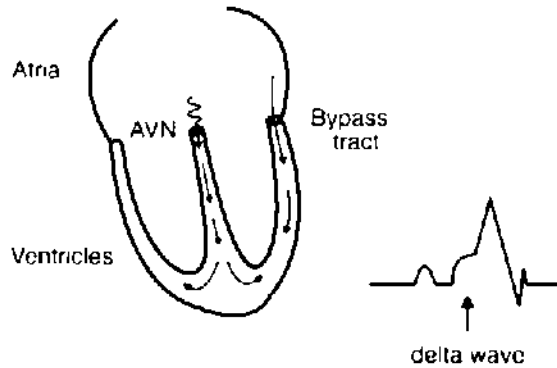
As the wave of depolarization passes through the atria, it leaks through the bypass tract as well as into the AV node (see Fig 1.16). Conduction through the bypass tract is usually faster than AV nodal conduction. As current exits the bypass tract, it stimulates ventricular depolarization; the ventricle is *pre-excited*, which is a catchy way of saying that a segment of the ventricle is stimulated early. An instant later, current exits the AV node and also stimulates the ventricle. The ventricular complex thus originates from two sites and may be considered a *fusion beat*.

The QRS is wider than normal and starts earlier after the P wave, so the PR interval is short. (Note that this does not reflect more rapid conduction through the AV node.) The initial, slurred tract is the *delta wave* (see Fig 1.16).

Diagnosis of pre-excitation: PR interval < 0.12 second, plus a delta wave (Fig 1.17)

Bypass tracts may conduct either antegrade or retrograde. A premature atrial contraction that finds the accessory pathway refractory may pass through the AV node, capture the ventricle, conduct retrograde through the bypass tract, and establish a *reentrant circuit* with repetitive firing of the ventricles. Unlike other cases of reentry, there is

Preexcitation of the left ventricle through a bypass tract



Two patterns of supraventricular tachycardia

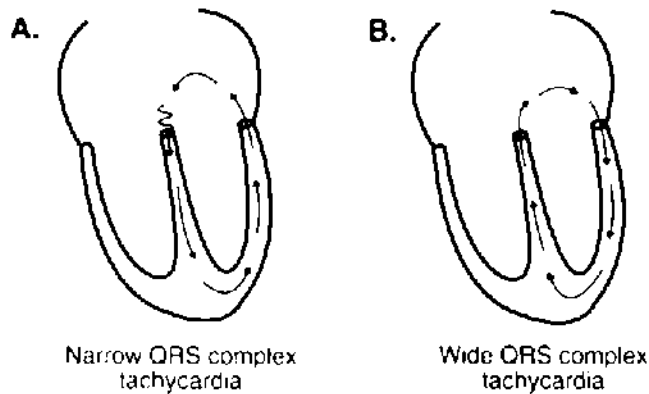


FIGURE 1.16 Pre-excitation (or Wolff-Parkinson-White syndrome). This cartoon illustrates the changes caused by a bypass tract between the atria and ventricles. The tract is located on the LV side and near the mitral valve in this particular patient, but bypass tracts may be located at any site where atria and ventricles come into contact. Simultaneous activation of the ventricles via the bypass tract and the AV node produces a fusion beat. Conduction through the bypass tract is faster than through the AV node. Early activation of the ventricle produces the delta wave and makes the PR interval appear short.

A reentrant circuit can develop between the bypass tract and the AV node, resulting in supraventricular tachycardia. There are two possibilities. **A:** The reentrant circuit moves antegrade through the AV node, retrograde through the bypass tract. The sequence of ventricular activation is therefore normal, and the QRS is narrow. **B:** The reentrant circuit is directed retrograde through the AV node and antegrade through the bypass tract. Because activation of the ventricles originates from the lateral wall of the LV, the QRS complex is wide.

no protected, small reentrant focus (as in Fig 1.12). Rather, the circuit includes the AV node, the atrium, the bypass tract, and some portion of the ventricle.

When antegrade conduction and stimulation of the ventricles is through the AV node, the reentrant arrhythmia looks like PSVT with a narrow QRS complex (and, in fact, it is PSVT). A reentrant circuit in the opposite direction (see Fig 1.16), retrograde through the AV node and antegrade through the bypass tract, has a wide QRS complex

PATHOPHYSIOLOGY

Most of the time a wide QRS indicates infranodal conduction disease. As you will see in the next chapter, initial depolarization of the ventricle is normal, and the region of the ventricle supplied by the blocked nerve is activated late. Thus, with left bundle branch block, the left side is depolarized late. The result is slurring of the tail end of the QRS complex. The wide QRS of preexcitation is different. It is the initial phase of depolarization that is affected, so the front end of the QRS is slurred.

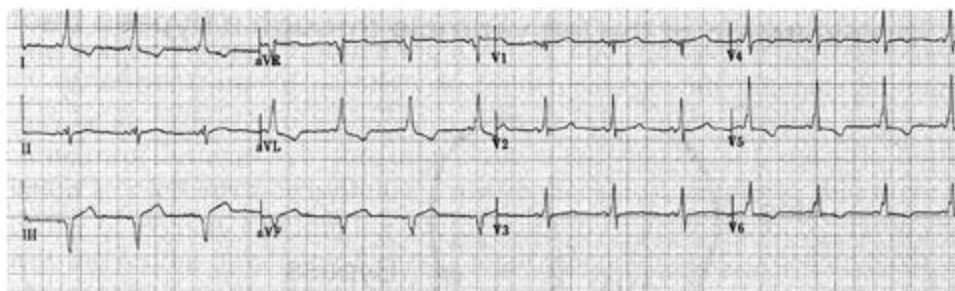


FIGURE 1.17 Pre-excitation (Wolff-Parkinson-White syndrome). The PR interval is short, and the QRS is slightly widened. Slurring of the upstroke of the QRS is apparent in multiple leads (I, aVL, the V leads); this is the *delta* wave.

because the sequence of ventricular activation is abnormal. It may look like ventricular tachycardia (VT).

How can you tell whether this *wide QRS tachycardia* is ventricular or supraventricular? At times you cannot. The clinical setting helps. A young patient with a history of PSVT, no other heart disease, wide-complex tachycardia, and no alteration of consciousness is likely to have PSVT with bypass tract reentry. An older patient with a history of heart failure or MI, and who has had syncope or near-syncope, should be treated assuming a diagnosis of VT. When in doubt, it is hard to go wrong treating the arrhythmia as probable VT. Direct current (DC) cardioversion is appropriate if the patient is unstable.

It is important to identify PSVT that is caused by pre-excitation because the drug treatment is different. Digoxin, beta blockers, verapamil, and intravenous adenosine should be avoided because they slow AV nodal conduction, but not conduction through the bypass tract. If the patient develops AF or atrial flutter, drugs that slow AV node conduction favor conduction through the bypass tract. Bypass tracts conduct more rapidly than the AV node, so there could be a big increase in ventricular rate. Membrane-active agents, on the other hand, slow accessory pathway conduction; intravenous procainamide is a good choice for a patient with WPW syndrome who is having PSVT.

Procainamide has been used for long-term management of pre-excitation. A newer and more effective therapy is *catheter ablation* of the bypass tract, and it is usually a

cure. A catheter electrode is positioned next to the bypass tract, radiofrequency energy is applied, and the tissue touching the catheter is burned. There is no smoke or an odor of burning flesh; it is more like a sunburn. Subsequent scarring effectively plugs the hole in the insulation. It is a relatively low-risk procedure and is better than life-long drug therapy, especially when drug therapy fails to prevent PSVT.

Sick Sinus Syndrome

The sick sinus syndrome is not just one arrhythmia, and it is rarely diagnosed with a single ECG. Rather, a variety of arrhythmias occur at different times. It most commonly affects the elderly. Most patients have SA node dysfunction, which causes bradycardia.

Patients with sick sinus syndrome have alternating bradycardia and supraventricular tachycardias. This seemingly paradoxical juxtaposition of slow and rapid heart rhythms is also called the brady-tachy syndrome. The supraventricular tachycardia may be PSVT, atrial fibrillation, or flutter—or some combination of these. The rhythm may shift from one form of supraventricular tachycardia to another within a short time. Bouts of tachycardia may be followed by disturbingly long pauses. Both rapid and slow rhythms can cause dizziness or syncope. Diagnosis of the sick sinus syndrome requires demonstrating a variety of these arrhythmias in a patient who has symptoms.

Electrophysiology testing is rarely needed to make the diagnosis. When it is done, the test to assess SA node function is simple. The atria are paced at a rapid rate for a few minutes. When the pacer is turned off, a sick sinus node takes a long time to start beating; the “sinus node recovery time” is prolonged.

CLINICAL INSIGHT

Symptomatic bradyarrhythmia is the usual indication for cardiac pacing. Two exceptions to this are (1) asymptomatic infranodal heart block including complete heart block and Mobitz II second-degree block, and (2) asymptomatic sinus pauses of more than 4 seconds. Both conditions can lead to syncope or sudden death. With other bradyarrhythmias, pacemaker therapy is not necessary in the absence of symptoms.

It often is hard to be sure that the patient’s symptoms are related to an observed arrhythmia. Since the sick sinus syndrome is rarely fatal, a period of observation—perhaps with event monitoring—is better than rushing into pacemaker therapy. Medicine adjustment may help an elderly patient; with atrial arrhythmias and vague symptoms, it is safe to try that.

An interesting feature of the sick sinus syndrome is that the medicines needed to control the symptomatic rapid rhythm (digoxin, beta blockers, or calcium channel blockers) may aggravate the bradyarrhythmia. Treatment may thus combine pacing (to prevent bradycardia) and drug therapy (to prevent tachycardia). This is the most common indication for pacemaker therapy in the United States.

Wandering Atrial Pacemaker and Multifocal Atrial Tachycardia

These rhythms are irregular (Fig 1.18). They are distinguished from atrial fibrillation by P waves before each QRS complex. The P waves have varying morphologies, usually

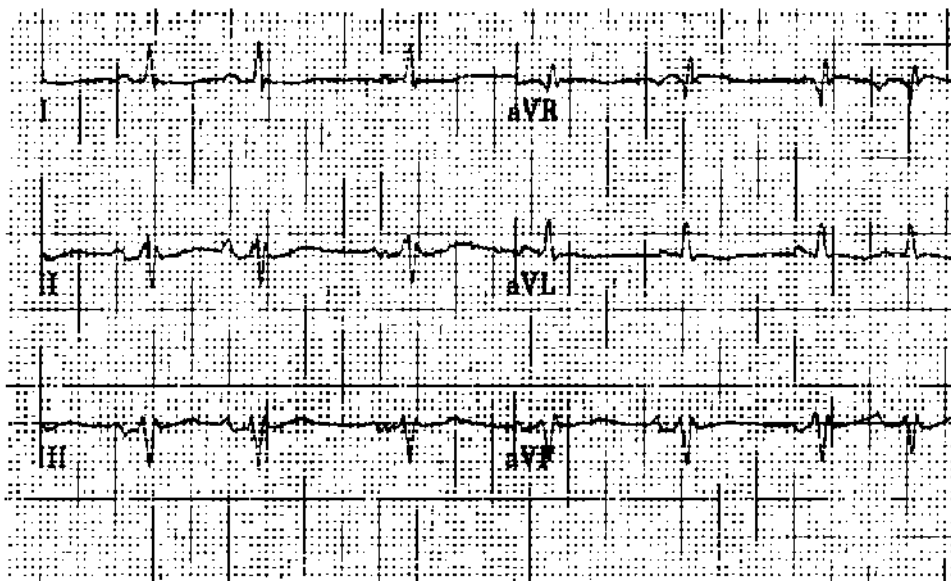


FIGURE 1.18 Wandering atrial pacemaker. These limb leads are from a patient with obstructive lung disease. The variation in P wave morphology is seen in lead II. This is the other cause of an irregular rhythm. In the absence of obvious P waves before each QRS, the diagnosis would be atrial fibrillation, a more common arrhythmia. At rates above 100/min, wandering atrial pacemaker becomes multifocal atrial tachycardia.

three different patterns within a 12-lead ECG. The P waves apparently originate from varying sites in the atria. The only difference between the arrhythmias is the heart rate: when it is rapid, it is called multifocal atrial tachycardia. Both are common arrhythmias in patients with obstructive lung disease.

Ventricular Arrhythmias

Premature Ventricular Contractions

Most of us have PVCs, and they are a common finding on routine ECGs (Fig 1.19). Because they originate within the body of one of the ventricles, activation of the two ventricles is not simultaneous and the QRS is wide. PVCs and other ventricular rhythms may come from an *automatic focus*, tissue that is insulated from the surrounding muscle and fires automatically at a fixed rate. When it discharges between heartbeats, at a time when the surrounding muscle has repolarized and can be stimulated (is *vulnerable*), it produces a PVC. On the other hand, when the ectopic focus discharges while the ventricle is depolarized or before it is repolarized (during a QRS or a T wave), the ventricle is *refractory* to stimulation, and there is no PVC. Interestingly, this is the way old-fashioned, fixed-rate pacemakers work: they click along at a regular rate, capturing the ventricle only when it is vulnerable.

A second, and probably more common, mechanism for ventricular beats is *reentry*, a concept discussed previously in relation to PSVT (see Fig 1.12). The reentrant focus is within the body of the ventricle, possibly an area of fibrosis or ischemia. Current enters the focus, but it is insulated from surrounding tissue. Conduction through the reentrant focus is slow. By the time the wave of depolarization exits the focus, the

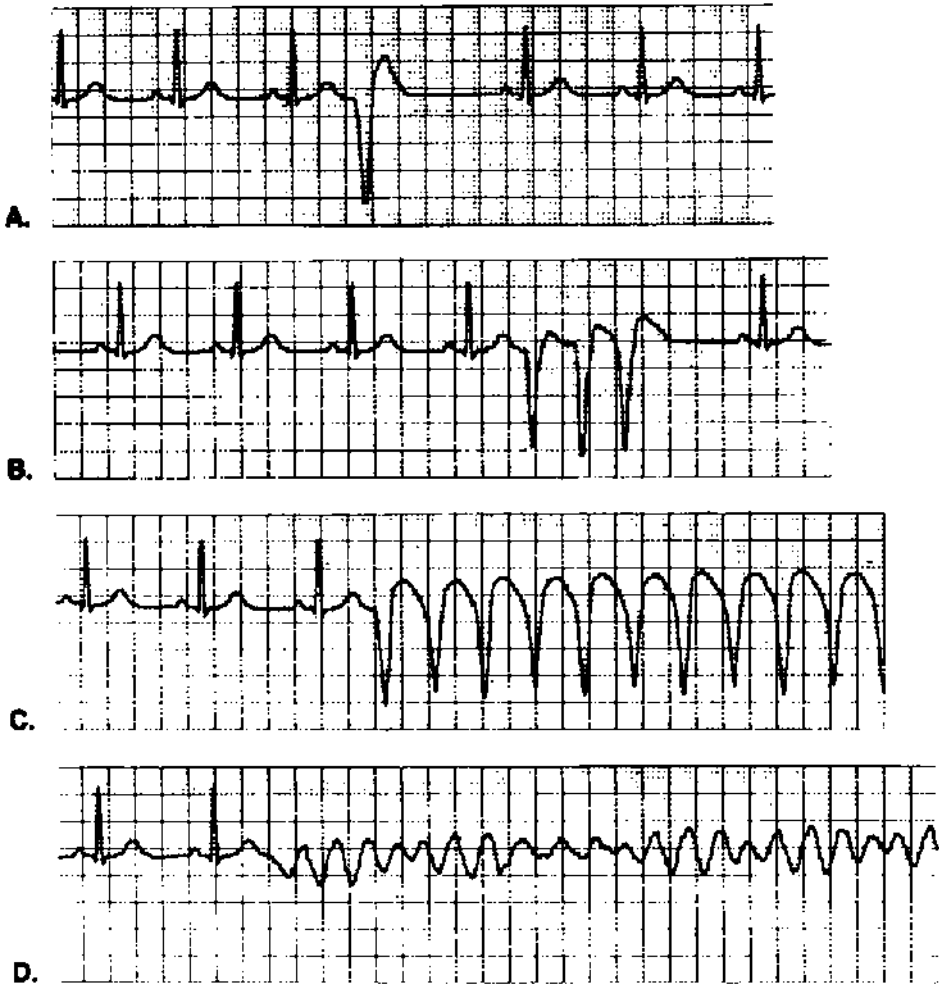


FIGURE 1.19 Ventricular arrhythmias. **A:** Isolated premature ventricular contraction (PVC). **B:** A ventricular triplet; ventricular tachycardia (VT) is defined as three or more PVCs in a row. **C:** Sustained VT. **D:** Ventricular fibrillation, the usual cause of sudden cardiac death.

Isolated PVCs are common in the absence of organic heart disease. More complex forms, including paired PVCs and VT, may be the consequence of LV dysfunction or acute ischemia.

surrounding ventricle has been repolarized and can be stimulated, causing the PVC. A circuit may develop with repetitive stimulation of the ventricle. Most cases of VT are thought to be reentrant rhythms. By convention, we often refer to extra beats or abnormal rhythms as *ectopic*, regardless of the mechanism (automatic or reentrant focus).

When reading ECGs, a common dilemma is deciding whether an ectopic beat is a PVC or is a PAC that is aberrantly conducted because of a blocked nerve below the AV node. *Aberrant conduction* produces a QRS complex that is wide and hard to distinguish from a PVC. One cause of wide-complex tachycardia is PSVT with aberrant infranodal conduction.

There are a few characteristics that help to make the distinction between PVCs and PACs with aberrancy. Aberrant PACs distort the QRS less, and the QRS axis tends to be similar to that of normal beats. That is to say, where normal beats have an upright (positive) QRS, the ectopic QRS is also upright. The PVC's T wave axis is often opposite the QRS axis (i.e., when the QRS is positive, the T wave is negative). Aberrant conduction commonly affects the right bundle branch, which seems a weak link in the infranodal conduction system. Thus, aberrantly conducted PACs often have a right bundle branch block pattern (see Chapter 2 for a description of right bundle branch block). Occasionally, the ectopic P wave can be seen distorting the preceding T wave, suggesting a PAC.

While helpful, these general characteristics are not totally reliable, and there is often uncertainty about the origin of extra beats.

Repetitive Ventricular Rhythms

Ventricular fibrillation is the usual cause of sudden cardiac death (see Fig 1.19). Frequent PVCs in a setting of *acute* MI indicate a high risk of ventricular fibrillation. With *chronic* heart disease, there is a hierarchy of ventricular arrhythmias which may indicate a risk of sudden death (see Fig 1.19).

A wide QRS complex tachycardia may be VT, but it may also be supraventricular tachycardia with aberrant conduction. Even rapid atrial fibrillation with associated bundle branch block can look like VT (although on close inspection, the rhythm is more irregular with AF). The clinical context helps differentiate between VT and PSVT. Patients with acute MI or with a history of congestive heart failure are at high risk for developing VT. On the other hand, a young person without chest pain who is clinically stable—with the exception of palpitations—is more likely to have a supraventricular arrhythmia. When there is a history of recurring episodes, consider a preexcitation syndrome like the WPW syndrome.

The one ECG finding that allows you to diagnose VT with certainty is *AV dissociation*. During VT, if there is no retrograde conduction of ventricular impulses through the AV node to the atria (and there usually is not), the atria continue to beat independently. There are P waves clicking along at a regular rate that is slower than the VT rate, and these may be seen on the surface ECG (Fig 1.20). When electrophysiologists are unsure of the cause of wide-complex tachycardia, they record an ECG from within the right atrium. At this location, P waves are huge and easy to see: AV dissociation makes the diagnosis of VT.

Torsade de pointes is a curious form of VT that is a favorite of Board examiners. The QRS complexes are polymorphic (variable) with an undulating pattern (Fig 1.21). The axis of each successive beat is different from the preceding one—the axis is “turning about a point.” Conditions and drugs that cause QT interval prolongation may precipitate the arrhythmia. Most antiarrhythmic drugs have a paradoxical *proarrhythmic* action; torsade is the typical arrhythmia that may be caused by the class IA drugs (quinidine, procainamide, and disopyramide). It may be prevented by avoiding other conditions that prolong the QT interval as well as by *combinations* of drugs that lengthen the QT (see Table 1.2).

CLINICAL INSIGHT

Serious ventricular arrhythmias occur in patients with left ventricular (LV) dysfunction. And those with LV dysfunction usually have ventricular arrhythmias. This association is so reliable that the syncope workup includes an echocardiogram. A normal LV excludes ventricular tachycardia. Furthermore, a severely depressed LV is an indication for prophylaxis with an implantable defibrillator, even without symptoms.

There are a few exceptions to this association of ventricular arrhythmias and poor LV function: (1) VT or VF may occur during the first 12 hours of MI, even when the MI is small and LV function is normal—"electrical storm" develops during a brief period of instability; (2) hypertrophic cardiomyopathy may cause ventricular fibrillation and sudden death, and LV contractility is normal or hyperdynamic; (3) the long QT interval syndromes described below; (4) right ventricular dysplasia, a rare congenital abnormality.



FIGURE 1.20 Ventricular tachycardia with AV dissociation. Finding intermittent P waves (marked with *dots*) that do not alter the ventricular rhythm is the most reliable indication that the tachycardia originates in the ventricle. If it originated in the atrium, there would necessarily be a relationship between atrial beats (P waves) and ventricular beats. You may consider this identification of P waves a stretch; it is rare to see them on a surface ECG. P waves are obvious on an electrogram recorded in the right atrium, and this is the electrophysiologic maneuver for determining the origin of wide QRS complex tachycardia.

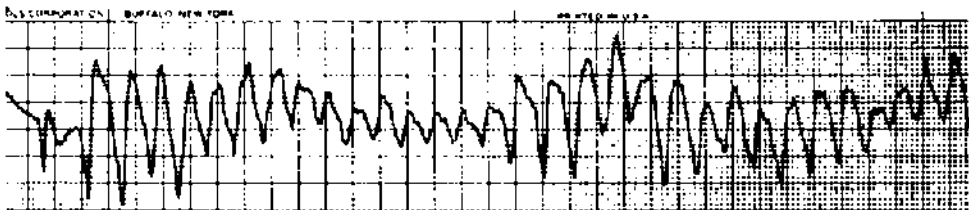


FIGURE 1.21 Torsade de pointes is an undulating, polymorphic VT in which the axis of each successive beat is different from that of the preceding one.

Torsade is important to recognize because its management is different from that of other forms of VT. Measures that shorten the QT interval are most effective. Intravenous magnesium often works. Increasing the heart rate also shortens the QT (with either temporary pacing or intravenous isoproterenol infusion).

CLINICAL INSIGHT

Hypomagnesemia prolongs the QT interval and is a cause of torsade de pointes. Remember that magnesium and potassium move in tandem: conditions or drugs (diuretics) that lower potassium also lower magnesium. Spironolactone causes renal retention of both potassium and magnesium and is effective treatment for hypomagnesemia. The magnesium ion is poorly absorbed—it is a cathartic—so magnesium replacement therapy does not work.

Table 1.3 ECG Abnormalities Caused by Drugs and Metabolic Conditions

	Drugs	Metabolic conditions
<i>Rate</i>		
Sinus bradycardia	β -Adrenergic blockers, calcium channel blockers (verapamil and diltiazem), digitalis, intravenous adenosine	Hypoxemia, hypothyroidism, hyperkalemia, hypothermia
Sinus tachycardia	Catecholamines, caffeine, amphetamines	Hyperthyroidism, anemia, fever
<i>Rhythm</i>		
Heart block	Digitalis, β -adrenergic blockers, calcium channel blockers (verapamil, diltiazem), intravenous adenosine	Hyperkalemia
Atrial flutter		Hypoxemia (consider pulmonary embolus)
Atrial fibrillation	Thyroid hormone	Hyperthyroidism, hypokalemia, hypomagnesemia
Ventricular tachycardia/fibrillation	Most antiarrhythmic agents (proarrhythmia), digoxin, tricyclic overdose	Hypokalemia, hypomagnesemia,
Torsade de pointes	Class I (antiarrhythmic agents (quinidine, procainamide, disopyramide), sotalol, amiodarone, phenothiazine derivatives (including antihistamines), tricyclic overdose	Familial long QT syndrome

Drugs and Metabolic Abnormalities That May Alter the ECG and Cardiac Rhythm

Table 1.2 summarizes conditions and drugs that may alter intervals. Table 1.3 extends this to changes in rate and rhythm. While not comprehensive, it includes the common conditions and drug effects that you may encounter while reading routine ECGs (and taking Board exams).

Electrical Axis

The wave of depolarization passes through the heart in three dimensions, but each two-pole ECG lead records these events in just one dimension. Having 12 leads that are grouped in horizontal or frontal (vertical) planes allows us to reconstruct these events in three-dimensional space (see Fig 1.2). We are able to determine the spatial orientation, or *axis*, of each electrical event in the cardiac cycle.

Atrial depolarization starts high in the right atrium and moves down and to the left, toward the AV node (see Fig 1.3). The general direction, or axis, of the P wave is thus about 60° in the frontal plane. Because ECG lead II has its positive pole at 60° (see Fig 1.2), we would expect the P wave to be positive in that lead, and to have its maximum deflection or current in that lead. Lead aVR, with an orientation of -150° , would be expected to have a negative P wave.

What about the P wave in lead aVL, oriented just 90° from lead II? Simple vector principles tell us that measuring a vector from a perpendicular position produces a net measurement of zero. That is to say, the forces moving toward the position of measurement are balanced by the forces moving away. In lead aVL, the normal P wave either has little amplitude or is *biphasic*, with negative and positive deflections that are similar (in effect, canceling each other).

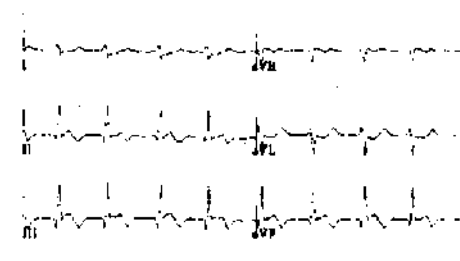
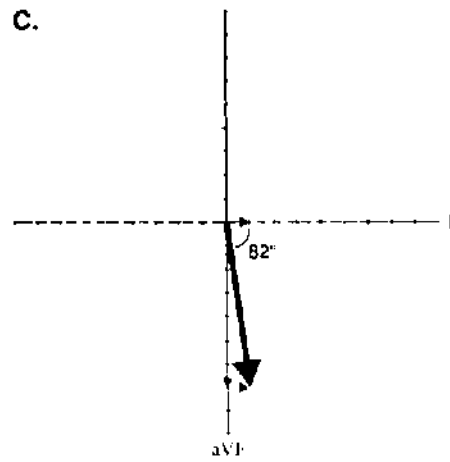
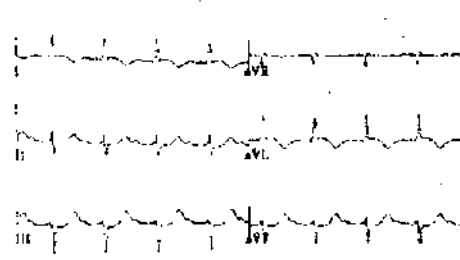
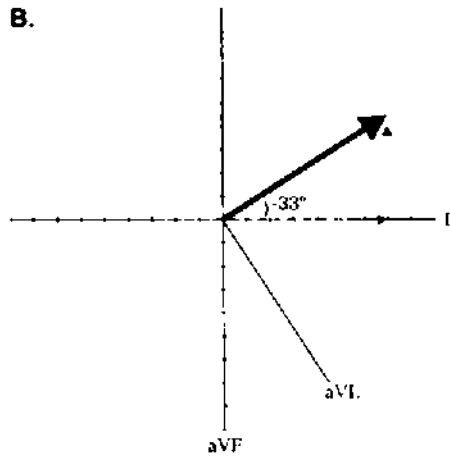
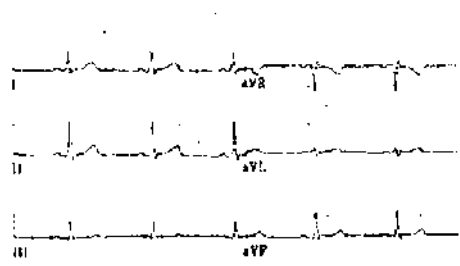
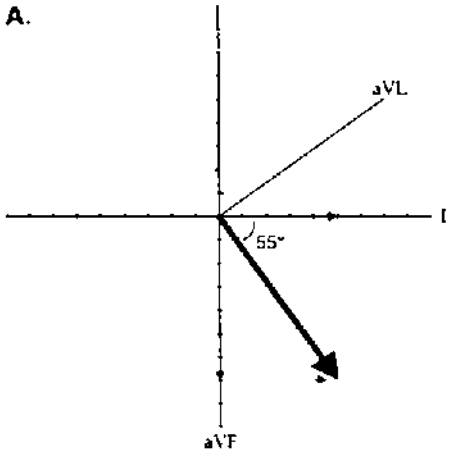
The P wave axis is not usually measured; as long as it is positive in inferior leads, it is good enough. When it is negative in those leads, it indicates an ectopic atrial pacemaker located in the lower part of the atrium and depolarizing the atrium from bottom to top. This has little clinical significance, but it is worth comment in the context of reading ECGs.

QRS Axis

From the AV node, the wave of depolarization moves first to the interventricular septum, discharging it from left to right, then through the body of the two ventricles (see Fig 1.3). The left ventricle is much thicker than the right and produces more voltage. The net vector of ventricular depolarization is therefore down and/or to the left in the frontal plane, normally about 60° , but ranging from -30° to $+110^\circ$.

Measurement of the QRS axis in the frontal plane is a technical challenge for most students. It is not that hard, and the practice ECGs will help you to learn to do it quickly. The ECG computer measures the QRS axis with the simple principle of vector addition (Fig 1.22). You can easily do that with graph paper, and the result is accurate, but there are faster ways.

One quick and simple method uses the principle that the QRS amplitude will be maximum and positive in the lead whose orientation is closest to the axis of the QRS vector. Thus, if the QRS axis is 0° , the QRS should have maximum amplitude in lead I. If the QRS axis is 90° , maximum amplitude should be in lead aVF. If leads I and aVF are both positive and with equal amplitude, the QRS should be half-way between them, or 45° . It is a crude approach, but at least it allows you to place the QRS vector within a quadrant.



Another method uses the principle that a net vector amplitude of zero indicates that the direction of the vector is perpendicular (90°) to the voltmeter's orientation. Thus, if the positive and negative QRS deflections are equal, that is to say *isoelectric* (or add up to zero) in lead I of the ECG, the QRS vector is pointed at $+90^\circ$ or -90° . If the QRS is positive in lead aVF, the axis must be $+90^\circ$.

That is the method I use. I find a lead where the positive and negative QRS deflections are equal—where the QRS is isoelectric. *The QRS axis is perpendicular to that lead; 90° in a direction that is quickly determined by looking at the general direction of the QRS vector (Fig 1.22).*

It may not be possible to find an isoelectric lead for which positive and negative deflections are equal. In this case, I choose a lead for which the deflection is close to isoelectric. For example, if the positive forces in lead aVL are slightly, but not much, higher than the negative forces, the axis is close to 60° , but actually a little more in the direction of aVL (perhaps 55°). It is a good approximation.

As we work through the first of the practice ECGs, we will pay close attention to measuring the QRS axis.

T Wave Axis

The T wave axis, like the P wave axis, is not usually calculated. Generally, it is in the same direction as the QRS axis. Where the QRS is positive, the T wave is also positive. T wave inversion—a T wave axis opposite that of the QRS—in an abnormal finding that is discussed in the next chapter.

FIGURE 1.22 Calculation of the QRS axis: three examples. Vector addition is a simple process. Choose any two leads (the figure uses leads I and aVF) and plot the net voltage. Move one of these plotted vectors so that its tail is positioned at the head of the other (*dotted line*). The sum of vector addition is the line drawn from the origin of the head of the repositioned vector (*bold line*). This is the mean QRS vector, and it is what the computer does to plot its direction.

There are faster ways to estimate the QRS vector axis. Look first at example **C**. In lead I, the positive and negative forces almost cancel each other; net voltage is just 0.1 mV (1 mm). When this tiny vector is moved to aVF, the resulting mean QRS vector is quite close to aVF. If the net forces in lead I equaled 0 mV (i.e., lead I was isoelectric), there would have been no displacement of the mean vector from aVF at all. The final QRS axis would be 90° . This illustrates the method I use for estimating the QRS axis: find a lead where the QRS is isoelectric (or close to isoelectric). The QRS vector is perpendicular to that lead.

Try this for the other two examples. **A**: The QRS is isoelectric in lead aVL; 90° from aVL is $+60^\circ$, and that is the QRS vector. Why is it not -120° , 90° in the other direction from aVL? Simply because the QRS is positive in the right lower quadrant leads (I, II, aVF). **B**: The QRS is almost isoelectric in II; 90° from II is either -30° or $+150^\circ$. Because the QRS is positive in the left side leads (I and aVL), the axis is close to -30° . Actually, the net forces in II are slightly negative, which pushes the vector a little farther to the left. I am calling the axis -35° , identifying this as left axis deviation (LAD).

Morphologic Changes in P, QRS, ST, and T

You have recorded rate, rhythm, intervals, and the QRS axis. The next step in reading the ECG is to evaluate the P wave, QRS complex, ST segment, and T wave for abnormalities, and then give a final interpretation. This is an exercise in pattern recognition. Yet ECG changes logically reflect what is happening with the heart's anatomy and physiology. All of it makes more sense if you think of mechanism while learning diagnostic criteria.

Atrial (P Wave) Abnormalities

Left Atrial Abnormality

There are two possible patterns of left atrial abnormality (LAA). The most common is a *biphasic P wave in lead V₁* (Fig 2.1). For it to be significant, the negative deflection has to be deep enough and wide enough to contain a small box (1 × 1 mm). The biphasic P is

CLINICAL INSIGHT

Left atrial abnormality (LAA) occurs when there is pressure or volume overload of the atrium. Patients with hypertension and left ventricular hypertrophy have elevation of the LV diastolic pressure, and this is transmitted to the left atrium since the mitral valve is open during diastole. The left atrium must contract against the stiff LV. LAA has been identified as the most consistent, early ECG abnormality in hypertension, appearing well before other features of left ventricular hypertrophy. Before this discovery I often read ECGs with isolated LAA as borderline rather than abnormal. Now I call such ECGs abnormal, as LAA indicates an end-organ effect of elevated pressure—hypertensive heart disease—and a need for more aggressive antihypertensive therapy.

LAA can be a transient finding. It may be present during acute pulmonary edema, and gone on the next day's tracing after diuresis, which lowers left atrial pressure.

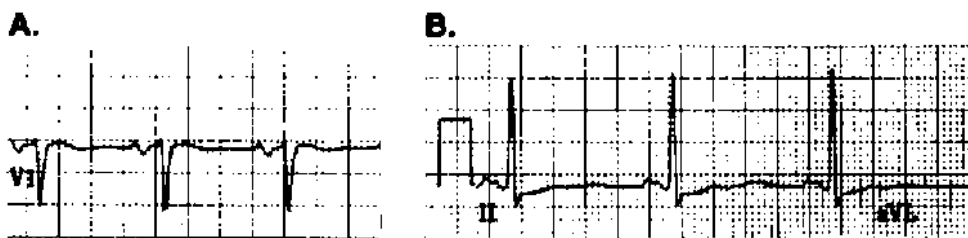


FIGURE 2.1 Left atrial abnormality (LAA). Two ECG findings may be used to make the diagnosis. **A:** Biphasic P wave in lead V_1 ; the negative deflection should be 1 mm deep and wide. **B:** Broad, notched P wave in one of the limb leads, most commonly II, III, or aVF, as the P wave vector is aimed at the inferior leads.

most common in conditions that increase left ventricular diastolic pressure—and therefore left atrial pressure—including congestive heart failure and left ventricular hypertrophy.

A second LAA pattern is a *broad, notched P wave* in lead II, III, or aVF (Fig 2.1). It may be present only in lead II. The notched P wave is most common in patients with marked dilatation of the left atrium, as may be seen with mitral stenosis or regurgitation, and is referred to as “P mitrale.”

Right Atrial Abnormality

Normally, P waves are less than 2.5 mm tall (in any lead). In right atrial abnormality (RAA), the P waves are tall and narrow, and they appear peaked (Fig 2.2). *P amplitude* ≥ 2.5 mm in those leads oriented along the P wave axis (the inferior limb leads, II, III, and aVF) usually indicates RAA. This often is referred to as “P pulmonale” because it may be caused by advanced lung disease with associated pulmonary artery hypertension. It is seen with pulmonary hypertension caused by congenital heart disease as well.

Intraventricular Conduction Abnormalities

Normally, the wave of depolarization exits the bundle of His, moves through the two bundle branches, and activates the two ventricles *simultaneously* (see Fig 1.3). When one of the bundle branches, or one of their major divisions, is injured and conduction is blocked, the affected ventricular region is stimulated late by current that has spread from an adjacent ventricular region. Late activation creates a deflection at the terminal end of the QRS complex, making the overall QRS complex wider. A QRS duration of 0.12 second or more (3 mm) is the first diagnostic criterion for bundle branch block.

Right Bundle Branch Block

When the right bundle branch is blocked (RBBB), the interventricular septum and the left ventricle are activated normally (Fig 2.3). Current then spreads from the left to the right ventricle, which is depolarized late. Electrical events that occur early—septal and

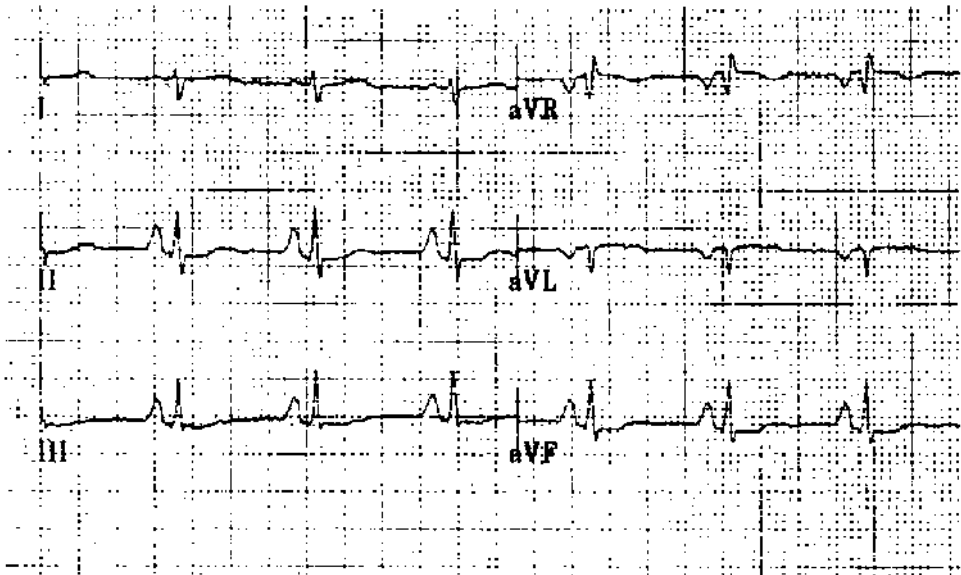


FIGURE 2.2 Right atrial abnormality (RAA). Tall, peaked P waves in inferior leads (at least 2.5 mm in one of the leads).

left ventricular activation—are thus unchanged. What is different is an extra deflection at the end of the QRS caused by late, right ventricular depolarization.

I will restate this with reference to specific changes on the ECG. But first, recall a basic principle of electrocardiography regarding the polarity of leads. Each lead has spatial orientation and polarity (see Fig 1.2). A wave of depolarization that moves toward the positive pole of a lead produces a positive (upright) deflection, an R wave. If the wave of depolarization moves away from the positive and toward the negative pole of a lead, it still is detected, but it produces a negative (downward) deflection, an S wave.

Back to RBBB (see Fig 2.3): Lead V_1 , on the *right side* of the chest, sits just over the right ventricle (RV) and is a sensitive detector of right ventricular events. In RBBB, lead V_1 first records normal septal activation, a positive deflection, or R wave, because the septum depolarizes from left to right. The left ventricle (LV) is activated normally, and in lead V_1 this produces a negative deflection, or S wave, as the wave of depolarization moves posteriorly and to the left. Finally, current works its way from the LV to the RV—remember, it could not get there directly because of the blocked right bundle. *The vector of RV depolarization is aimed at V_1* ; thus, the terminal deflection in V_1 is positive (upright), another R wave. RBBB thus produces an RSR' pattern in V_1 . In other leads, terminal forces (the RV vector) also are oriented toward the right. Thus, terminal QRS forces in the left-side leads, such as I, aVL, and V_6 , would be negative (an S wave).

RBBB diagnosis: RSR' pattern in V_1 , and QRS ≥ 0.12 second.

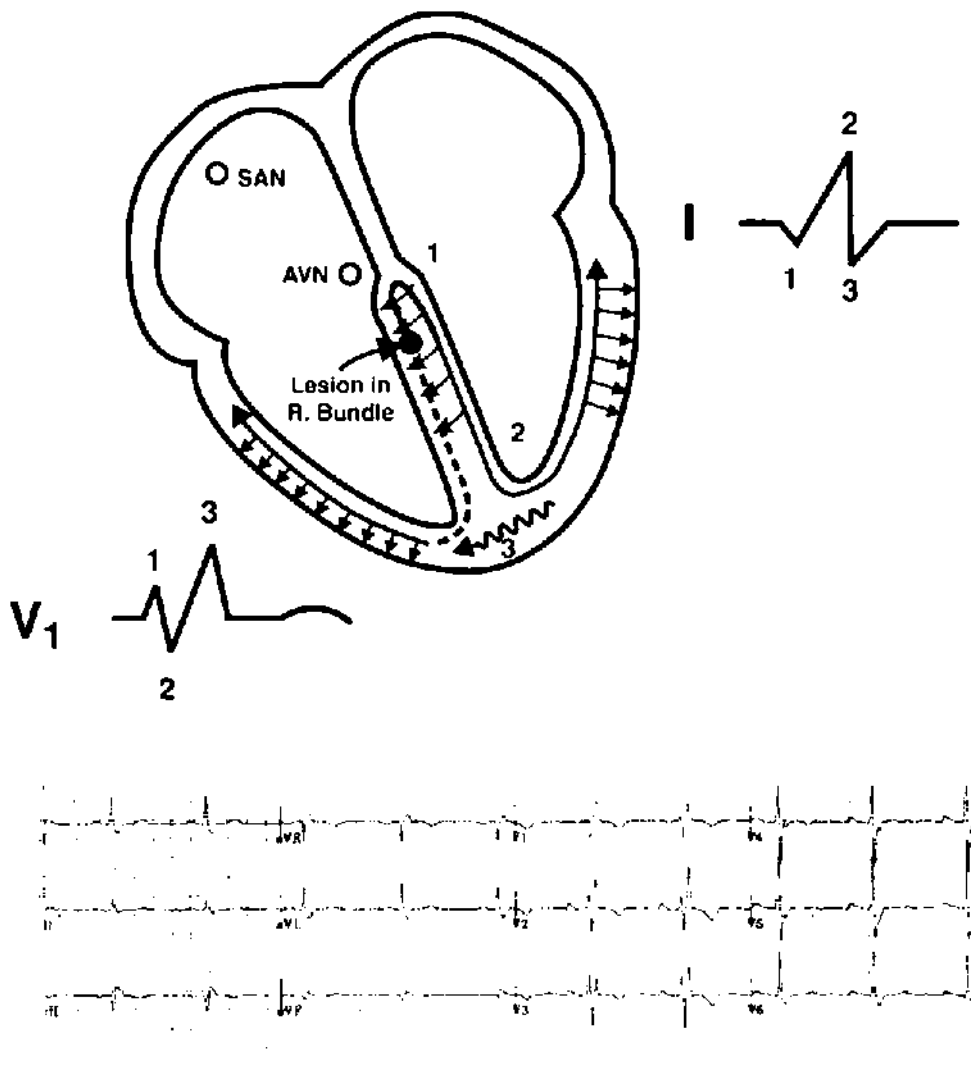


FIGURE 2.3 Right bundle branch block (RBBB). Follow the sequence of ventricular activation, and its effect on leads I and V₁, which, in the figure, are appropriately positioned. (1) There is normal septal activation from left to right. (2) Left ventricular activation is normal. (3) Because the right bundle branch is blocked, current must move from the left ventricle to the right, and this occurs late. The tail end of the QRS is slurred because of late depolarization of the right side. Pattern recognition: RSR in V₁ + wide QRS.

Incomplete Right Bundle Branch Block

Incomplete right bundle branch block (IRBBB) is usually a normal variant, but in some cases it reflects RV hypertrophy or dilatation. Our ECG computer program interprets it as “RV volume overload.” IRBBB is a common, almost invariable, finding with atrial septal defect (ASD), in which the RV may pump two or three times as much blood as the LV. ASD may cause no symptoms until a person reaches age 50. Thus, the diagnosis of ASD may be suggested by a routine ECG in an otherwise healthy young adult.

IRBBB diagnosis: RSR' pattern in V_1 , and QRS duration < 0.12 second.

CLINICAL INSIGHT

When I ask students how to exclude atrial septal defect (ASD) in a young person with incomplete right bundle branch block (IRBBB), the usual answer is an echocardiogram. However, ASD is a rare finding in people with IRBBB, so you would order many normal echocardiograms before finding an ASD. A more reasonable approach would be a physical exam looking for fixed splitting of the second heart sound. It is not a subtle finding, and its absence excludes ASD. If there is uncertainty a relatively inexpensive chest x-ray can also exclude the diagnosis; the radiologist easily recognizes pulmonary plethora. Finally, the more expensive echocardiogram is indicated if these screening studies are abnormal. ASD is a common congenital heart abnormality, and for this reason it is commonly encountered on board exams. If you suspect ASD expect to see IRBBB on the ECG. Without it the diagnosis is unlikely.

Left Bundle Branch Block (LBBB)

In LBBB, the sequence of ventricular activation is almost the opposite of that described with RBBB. The left bundle innervates the interventricular septum, so initial septal depolarization, normally from left to right, is lost (Fig 2.4). The initial small negative deflection in left-side leads (I, aVL, V_6) is lost—the so-called septal Q wave. The septum is instead activated from right to left, causing an initial positive deflection in left-side leads. Because the right ventricle is thin walled, little current is produced by RV excitation. Septal and early left ventricular activation predominate, and current generated by RV discharge (which would be oriented anterior and to the right) is buried within the LV complex. LV activation is slow because of the blocked left bundle, and the QRS complex is wide. The terminal forces are aimed at the blocked side, to the left; therefore, the terminal portion of the QRS is positive in left-side leads such as I, aVL, and V_6 (see Fig 2.4).

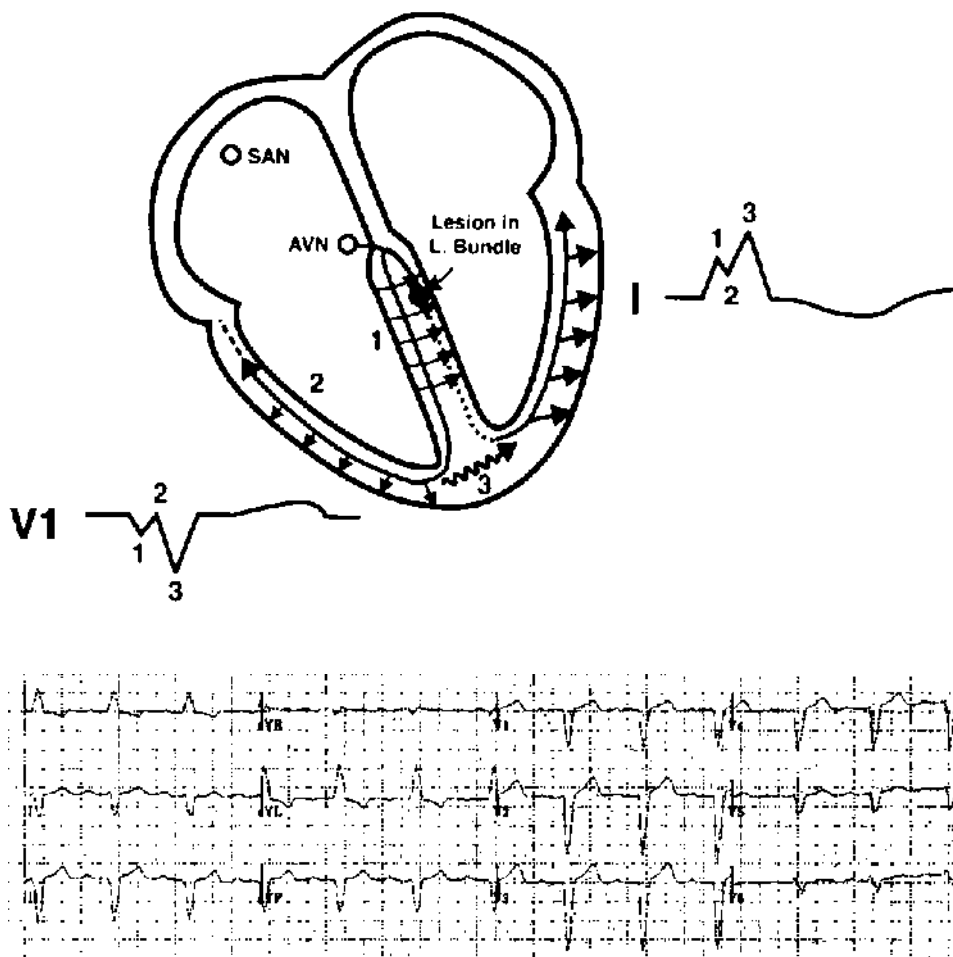


FIGURE 2.4 Left bundle branch block (LBBB). Follow the sequence of ventricular activation. (1) The normal left-to-right depolarization of the septum is interrupted by the blocked left bundle branch. The septum is activated from right to left. (2) Activation of the thin-walled right ventricle produces little current. (3) The left ventricle is depolarized late by current working its way over from the right side, and terminal QRS forces are oriented toward the left.

Pattern recognition: broad positive complex—often notched—in left-side leads (I, aVL). Small Q waves in these leads would exclude LBBB because they would indicate normal, left-to-right activation of the septum. This patient also had marked LAD. T wave changes and prolongation of the QT interval may accompany LBBB. It is not possible to diagnose either left ventricular hypertrophy or MI in the presence of LBBB.

LBBB diagnosis: QRS duration ≥ 0.12 second plus a broad, positive complex in left-side leads (I, aVL, and V_6).

CLINICAL INSIGHT

The ECG computer will occasionally describe an “intraventricular conduction defect” when the pattern looks like left bundle branch block (LBBB). Look more closely at leads I and aVL. The computer probably has detected a tiny Q wave, indicating normal left-right depolarization of the interventricular septum. LBBB interrupts this, so the presence of a “septal Q” excludes LBBB.

The left bundle is a broad complex of nerves in the interventricular septum, occupying a lot of space. For this reason LBBB usually indicates heart disease, with an abnormal echocardiogram. In contrast, the right bundle is a long, thin nerve that can be blocked by a small amount of fibrosis. The echocardiogram may show no structural or functional abnormality.

Left Anterior and Posterior Fascicular Block

The fascicular blocks, or **hemiblocks**, cause changes in the QRS axis. The left bundle divides into anterior and posterior branches, or fascicles. The *anterior fascicle* is a thin nerve that runs through the septum close to the right bundle branch. It is relatively susceptible to injury, possibly because of its size and location, and left anterior fascicular block (LAFB) is common. The left *posterior fascicle* is a broad group of nerves that fans out through the posterior region of the interventricular septum. Possibly because of the space it occupies, it is less susceptible to injury than the anterior branch, and left posterior fascicular block (LPFB) is less common than LAFB.

Diagnostic criteria: The QRS complex is not necessarily wider than normal; the diagnosis of fascicular block is made when there is a *shift in axis*.

1. LAFB: Extreme left axis deviation, at least -45° , not caused by inferior myocardial infarction (MI).
2. LPFB: Right axis deviation (RAD) $> 90^\circ$ (some have suggested more extreme RAD, as much as 110° or 120°).

This is a bit oversimplified, as other conditions may cause a shift in QRS axis. The most common of these is inferior MI with deep Q waves in inferior leads causing extreme left axis deviation. Inferior infarction does not alter conduction through the left anterior fascicle. When there are inferior Q waves (reviewed later in this chapter), the diagnosis is left axis deviation rather than LAFB.

Bifascicular Block

Think of the infranodal system as having three branches, or fascicles: the right bundle and the two branches of the left bundle. LBBB, or block of both branches of the left bundle, could be considered bifascicular block. However, the term is usually reserved for RBBB plus block of one of the two branches of the left bundle (RBBB plus LAFB, or RBBB plus LPFB).

Because of the anatomic proximity of the right bundle and left anterior fascicle, conditions that injure one often affect the other; the combination of *RBBB plus LAFB* is observed in as many as 1 in 25 hospitalized patients. The diagnosis is simple: there is RBBB plus extreme left axis deviation (LAD). This condition does not necessarily reflect advanced, serious heart disease. A small amount of fibrosis may block the two nerves. Many patients with RBBB plus LAFB have normal LV function and no other structural cardiac abnormalities.

By contrast, patients with other forms of bifascicular block—RBBB plus LPFB, or LBBB—usually have detectable, structural problems, such as poor LV function, ischemic injury, or hypertrophy.

CLINICAL INSIGHT

AV nodal block and infranodal block are both common, so it is no surprise that they are occasionally seen together. Earlier, there was concern about the patient with first-degree AV block who also has bifascicular block (right bundle branch block [RBBB] plus left anterior fascicular block [LAFB]). If the long PR interval is from conduction delay in the one remaining infranodal nerve, the left posterior fascicle, then the patient might be at risk for complete heart block. This was the subject of the first clinical studies using His bundle recording (see Fig 1.8). The result: virtually all patients with long PR + RBBB + LAFB have a long A-H interval, e.g., block in the AV node. The H-V interval—infranodal conduction—is normal. Prophylactic pacemaker therapy is unnecessary.

Ventricular Hypertrophy, QRS Amplitude, and R Wave Progression

First, the big picture; then we will get to the specifics. Pressure overload of a ventricle may be caused by increased vascular resistance downstream, or ventricular outflow tract obstruction. The ventricle responds to pressure overload by adding muscle, just as you add muscle to your arms with weight lifting. Increased muscle thickness on one side of the heart or the other may cause a shift in QRS axis toward the hypertrophied side and an increase in voltage (more muscle, more voltage).

The large coronary artery branches are located on the epicardial surface of the heart, and they send blood to underlying muscle through small perforating branches. An increase in ventricular thickness means an increase in the *distance* from the epicardial artery to the endocardium. Blood supply to the subendocardial region—farthest from the epicardial source—may be compromised, causing changes in the ST segment and T wave that look ischemic. It is commonly referred to as a *strain* pattern. In a sense, the ventricle outgrows its blood supply. Most coronary blood flow occurs during diastole. The relative reduction in flow to subendocardial regions with hypertrophy is aggravated by high ventricular diastolic pressures.

Finally, high ventricular diastolic pressures are reflected back to the atria, causing atrial (P wave) abnormalities on the ECG.




FIGURE 2.5 Left ventricular hypertrophy (LVH). This patient with aortic stenosis had LAA, high QRS voltage (V_2), ST-T changes in lateral leads (the typical LV strain pattern), and wide QRS. He did not have LAD, and the intrinsicoid deflection was borderline (see Table 2.1).

Table 2.1 The Estes Point System for Left Ventricular Hypertrophy (LVH)

1. Amplitude	3 points
Any of the following	
(a) Largest R or S wave in the limb leads ≥ 20 mm	
(b) S wave in V_1 or $V_2 \geq 30$ mm	
(c) R wave in V_5 or $V_6 \geq 30$ mm	
2. ST-T changes (typical pattern of left ventricular strain with the ST segment vector shifted in direction opposite to the mean QRS vector, usually ST depression)	
Without digitalis	3 points
With digitalis	1 point
3. Left atrial abnormality	3 points
4. Left axis deviation (-30° or more)	2 points
5. QRS duration ≥ 0.09 second	1 point
6. Intrinsicoid deflection in V_5 and $V_6 \geq 0.05$ second	1 point

LVH = 5 or more points

Probable LVH = 4 points

Left Ventricular Hypertrophy

Predictably, left ventricular hypertrophy (LVH) causes an increase in LV voltage plus ST segment depression and T wave changes in these leads with high voltage (the LV strain pattern), a shift in axis to the left, and LAA (Fig 2.5). In addition, there may be slight widening of the QRS to more than 0.09 second, and some patients develop LBBB. However, LBBB changes the QRS complex enough that LVH cannot be diagnosed when LBBB is present. The initial upstroke of the R wave in V_5 and V_6 , from baseline to its peak—called the *intrinsicoid deflection*—may be prolonged to over 0.04 second. This is the time that it takes the LV to be activated, and it is longer when the ventricle is thickened.

A patient with LVH may not have all these ECG findings, especially early in its development (Fig 2.5). The diagnosis can be made when just some of these features are present, but with fewer findings the certainty of the diagnosis is lower. The Estes scoring system is provided in Table 2.1. A point total of 5 makes the diagnosis of LVH, and with 4 points, the patient has probable LVH. Use of multiple diagnostic criteria rather than QRS voltage alone gives good specificity (fewer false positives, less overdiagnosis).

On the other hand, the sensitivity of the ECG in detecting LVH is poor; it tends to underdiagnose. Using an ECG point system, both anatomic and echocardiographic correlation studies have shown that just half the cases of true LVH meet rigid ECG criteria. Relaxing the diagnostic criteria, by using voltage alone for example, increases sensitivity but also increases the number of false positives. This choice between sensitivity and specificity is a common dilemma when reading ECGs.

CLINICAL INSIGHT

In general, avoid overdiagnosis. Left ventricular hypertrophy (LVH) demonstrates the importance of this principle. Young people often have high QRS voltage, particularly if thin or athletic. Using voltage alone to diagnose LVH could mean assigning that diagnosis to a healthy person. LVH is considered bad heart disease, and carrying that diagnosis would be a problem for anyone applying for a job or for insurance. It seems better to stick with strict ECG diagnostic criteria for LVH, recognizing the insensitivity of the ECG.

A counter argument is that LVH is a serious heart condition. For example, a person with coronary artery disease has a worse prognosis with the addition of LVH. Any ECG finding that would lead to earlier diagnosis and treatment might justify the risks of overdiagnosis.

In most cases, I place my vote for specificity (first, do no harm). When there is doubt, it can be sorted out with an echocardiogram.

Right Ventricular Hypertrophy

Most of the voltage in the QRS complex is generated by the LV, which is much thicker than the RV. This makes the QRS complex in the right-side precordial leads (V_1 and V_2) negative, and that in the left-side precordial leads (V_4 – V_6) positive. The *transition* from negative to positive complexes usually occurs around V_3 – V_4 . That changes with right ventricular hypertrophy (RVH). As you would expect, RVH causes an increase in RV voltage over the right chest leads and an associated shift in QRS axis toward the right. There is often a strain pattern in leads reflecting high RV voltage (Fig 2.6). Specific diagnostic criteria are outlined in Table 2.2.

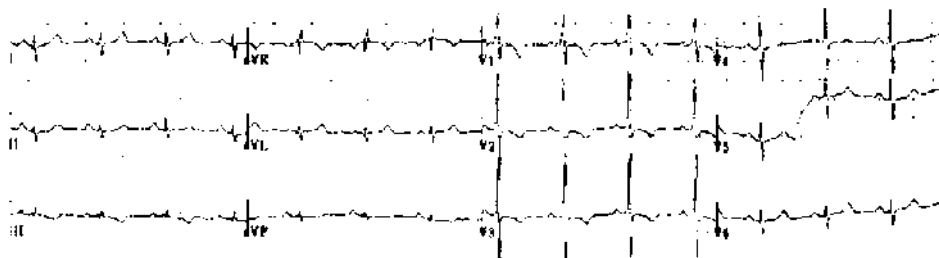


FIGURE 2.6 Right ventricular hypertrophy (RVH). This young woman with primary pulmonary hypertension had rightward axis, a tall R in V_1 , deep S in V_6 , and ST-T changes in the right precordial leads (the RV strain pattern). She did not have RAA (see Table 2.2).

Table 2.2 Diagnosis of Right Ventricular Hypertrophy

Criteria
R/S in $V_1 \geq 1$, or
R in $V_1 \geq 7$ mm, or
R in $V_1 + S$ in V_5 or $V_6 > 10.5$ mm
Supportive findings
Right axis deviation $\geq 110^\circ$
Right atrial abnormality (RAA)
ST depression + T wave inversion in V_1 or V_2 (RV strain)

RVH may not cause all these changes. The voltage changes alone may be used to make the diagnosis. I feel more confident when there is also ST-T change or axis shift. The possibility of false positives is enough that I usually hedge when reading ECGs with no clinical history. On the other hand, in the presence of a condition that may cause RVH (e.g., lung disease with probable cor pulmonale, mitral valve, or congenital heart disease, which can cause pulmonary hypertension, or primary pulmonary hypertension), the typical ECG pattern indicates RV pressure overload, most commonly from elevated pulmonary artery pressure.

CLINICAL INSIGHT

Cor pulmonale is common, but it is diagnosed infrequently. Consider it when a patient with chronic lung disease has peripheral edema. The ECG may or may not show evidence for right ventricular hypertrophy (RVH), but the echocardiogram should demonstrate RV and right atrial enlargement. Low oxygen saturation on room air is common. The treatment is continuous oxygen therapy, which allows the midsize pulmonary arteries to relax. When oxygen saturation is borderline for home oxygen, the presence of cor pulmonale (edema) is an indication for treatment.

Delayed, or Poor, R Wave Progression in Precordial Leads

To this point, each section has considered a cardiac diagnosis. This and a number of following sections will consider ECG findings that do not clearly indicate anatomic or functional abnormalities, and that must be recognized in the interpretation as nonspecific.

As noted previously, negative (S wave) forces predominate over right chest (precordial) leads. There is *transition* in the midprecordial leads, and the QRS should be isoelectric by lead V_3 , with positive and negative forces equal. In leads V_4 – V_6 the R wave amplitude should exceed negative forces. Delay in transition, or poor R wave progression, simply means that this transition point is further to the left (Fig 2.7), and that more of the precordial leads have (net) negative voltage.




FIGURE 2.7 Poor R wave progression (PRWP). Transition from a negative to positive QRS complex normally happens by lead V₄. This patient's QRS is still negative in V₄ and V₅.

CLINICAL INSIGHT

Because there are a number of causes of delayed R wave transition, it is not a diagnosis but rather a description of the ECG changes. It frequently accompanies left anterior fascicular block. Other causes are anterior myocardial infarction with a loss of positive forces in anterior leads, or marked dilatation of the left ventricle (LV) with displacement of the apical impulse—and with it the position over the LV where QRS voltage becomes positive.

A noteworthy cause is chronic obstructive pulmonary disease (COPD). Think for a moment of COPD with its barrel-chest deformity. On chest x-ray, the heart may appear to be hanging more vertically in the hyperexpanded chest cavity, and on physical exam the apical impulse is best felt in the subxiphoid region. There is a ligament attaching the pericardium to the diaphragm, and flattening of the diaphragm pulls it down, altering the heart's position. This has two effects: (1) rotation of the heart counter-clockwise, causing delayed R wave progression; and (2) a change in left atrial position causing a negative deflection in the P wave in lead aVL (less frequently observed than PRWP, but more specific for emphysema).

On the other hand, COPD can cause cor pulmonale and right ventricular hypertrophy (RVH). This may cause deep S waves in V₅₋₆ creating a delay in R wave transition. But remember that RVH also causes tall R waves in V₁, which I think of as the right ventricle lead. Studies correlating ECG and anatomic findings have shown that a deep S wave in V₅₋₆ but no tall R wave in V₁ may lead to a false positive diagnosis of RVH.

Low QRS Voltage

Diagnostic criterion: The QRS amplitude is less than 5 mm in all of the limb leads. When this is the case, the amplitude in each of the precordial (V) leads is usually less than 10 mm, but that is not necessary for the diagnosis.

As with delayed R wave transition, low voltage should be considered a description, not a diagnosis. It may be a normal variant. Among the cardiac conditions associated

with low QRS voltage are dilated cardiomyopathy, infiltrative cardiomyopathy, pericardial effusion, and constrictive pericarditis. Noncardiac causes include hypothyroidism, emphysema, and obesity. Low voltage is such a nonspecific finding that it is not considered a diagnostic criterion for any of these illnesses.

CLINICAL INSIGHT

An exception to a lack of diagnostic specificity using low QRS voltage is cardiac amyloidosis. The combination of low QRS voltage plus a thick left ventricle on the echocardiogram strongly suggests that diagnosis. The increased thickness is the amyloid. It is not muscle (not true hypertrophy), does not depolarize, and therefore adds nothing to QRS voltage.

ST Segment and T Wave Changes and Q Waves: Patterns of Ischemia and Infarction

Myocardial ischemia tends to be a regional event (Fig 2.8). Only one of the major coronaries is likely to cause ischemia or infarction at a time. To have multiple branches develop stenoses that cause active ischemia *simultaneously* would be a rare coincidence. Thus, an ischemic event is limited to the *anterior* wall (the anterior descending artery, the precordial V leads), the *inferior* wall (usually the right coronary artery, ECG leads II, III, and aVF), or the *lateral* wall (the circumflex artery, leads I, aVL, and V₆).

There can be some overlap in vascular distributions, as there is considerable anatomic variation. Thus, occlusion of an especially large right coronary artery that loops around to the lateral wall might cause *inferolateral* infarction with ECG changes in inferior leads, plus changes in one or more of the lateral leads. A large anterior descending artery might have branches that supply part of the lateral wall, and *anterolateral* MI would mean changes in anterior precordial leads plus one or more of the lateral leads (see Fig 2.8).

ECG changes that are global, involving all the vascular regions, are rarely caused by ischemia. Pericarditis, for example, affects the entire heart and causes ST segment and T wave changes that are global, present in anterior, inferior, and lateral leads.

Ischemic injury can cause a variety of changes in ST segments, T waves, and the QRS complex. The following section is organized around the ECG changes. While reading this, you may find it useful to refer to Table 2.3, which organizes the same ECG findings according to cardiac diagnoses—the same information, just a different way of looking at it.

ST Segment Depression

During the short time from the end of the QRS complex to the beginning of the T wave, no voltage is recorded on the ECG; the ST segment is isoelectric (see Fig 1.2). This is another use of the term *isoelectric*. Here it means that there is no voltage—as is the case with the ST segment that rests on the baseline; it can also mean that positive

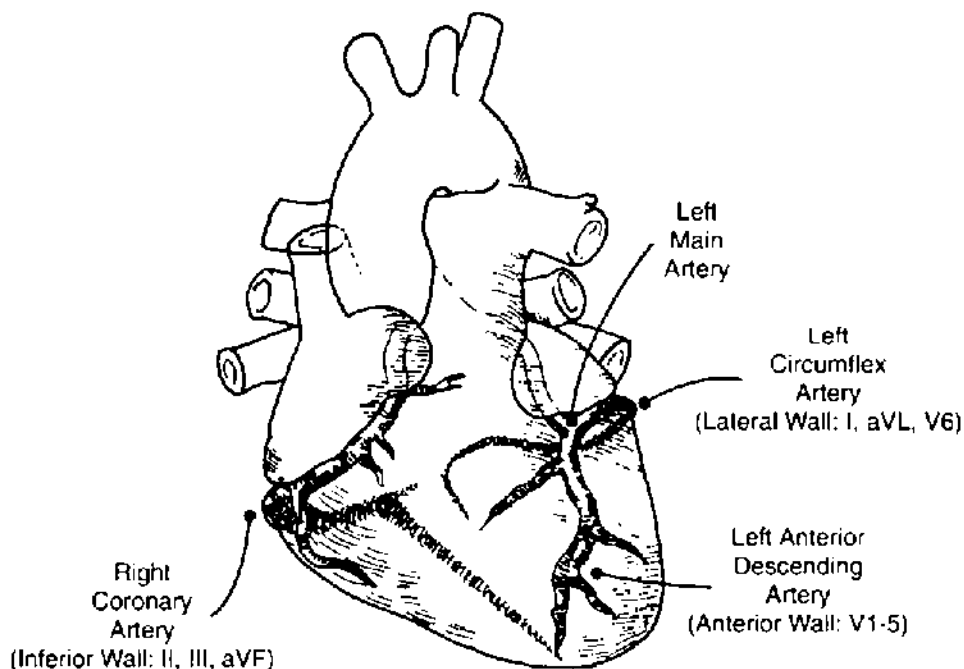


FIGURE 2.8 Coronary artery anatomy. The circumflex and right coronary arteries circle the heart in the AV groove; branches of the circumflex leave the groove to supply the lateral wall. The major right coronary branch (the posterior descending artery) supplies the inferior wall. The anterior descending artery is located just over the interventricular septum (the *interventricular groove*); it sends perforating branches into the septum, and diagonal branches to the anterior LV surface. The spatial orientation of the ECG leads allows groups of leads to reflect events in a given region of the heart (see Fig 1.2 as well).

Table 2.3 ECG Changes with Syndromes of Myocardial Ischemia

Condition	ECG changes	Timing	Pathophysiology
Angina pectoris	ST depression	Coincidental with chest pain	Stenosed artery, but with some antegrade flow; O ₂ demand exceeds supply; subendocardial ischemia
Coronary artery spasm (angina pectoris)	ST elevation	Coincidental with chest pain	Spasm may occur in a normal artery or at the site of plaque; usually total occlusion; transmural ischemia, temporary
Non-Q MI	ST depression T wave inversion	During pain but may be permanent	Stenosed artery, but with some antegrade flow; subendocardial ischemia, then necrosis
Q wave MI	ST elevation T wave inversion Q wave	Coincidental with pain Minutes to hours later, while ST elevation persists Minutes to hours after onset of MI; permanent	Total occlusion, transmural ischemia, then necrosis

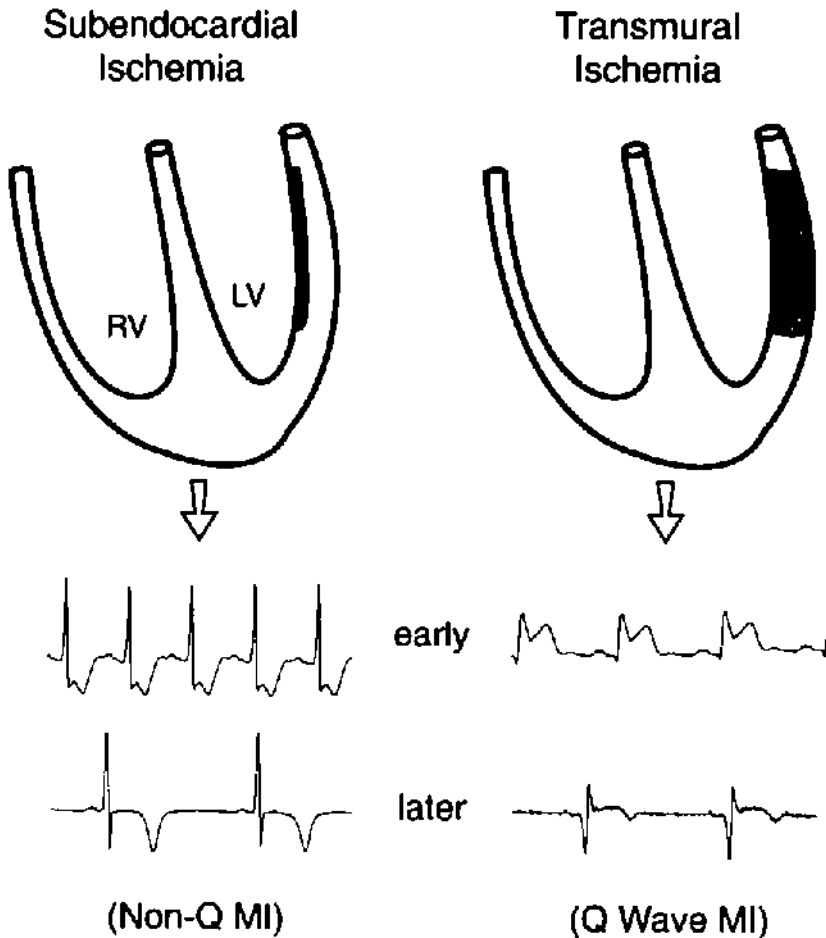


FIGURE 2.9 Patterns of myocardial ischemia. The epicardium is the outside surface of the heart, and the endocardium is the surface next to the ventricular cavity. The coronary arteries are located on the epicardial surface. Subendocardial (*nontransmural*) ischemia causes ST segment depression. If ischemia persists and there is myocardial injury, there may be T wave inversion (a pattern now called non-ST elevation MI, but also referred to as subendocardial or nontransmural or non-Q wave infarction). Transmural ischemia is caused by total occlusion of the artery. During acute ischemia, there is ST segment elevation. Resolution of spasm or dissolution of thrombus may open the occluded artery before there is injury. In this case, the episode of ischemia represents angina pectoris. If occlusion and, therefore, ischemia persists and there is myocardial injury, the pattern is called ST elevation MI (also referred to as transmural or Q wave infarction).

and negative forces are equal, canceling each other with a net sum of zero voltage. At times it is difficult to identify the baseline. The segment just before the P wave is generally accepted as the baseline. Note that the PR segment or ST segment can shift up or down with disease.

A shift in the ST segment from the baseline may indicate ischemia. *ST depression* occurs with *subendocardial ischemia* (Fig 2.9). Cardiac catheterization during subendocardial ischemia usually reveals that the coronary artery supplying the ischemic zone is tightly stenosed but not (totally) occluded. There is a mismatch between blood supply

and demand across the stenosed artery, and the region of myocardium farthest from the epicardial artery—the subendocardium—is the most ischemic.

The ECG in Fig 2.10 is a good example. It was recorded during a treadmill stress test from a middle-aged woman with chronic, stable angina pectoris. At rest, she had no ST segment depression. During exercise, heart rate and systemic blood pressure rose, both in direct proportion to the increase in cardiac work. Increased cardiac work means an increase in myocardial oxygen demand. To meet the increase in demand, her coronary artery blood flow increased. But the coronary artery stenosis placed a limit on how much the arterial blood flow could increase. When cardiac work load exceeded that limit, she developed ST segment depression and angina pectoris.

PATHOPHYSIOLOGY

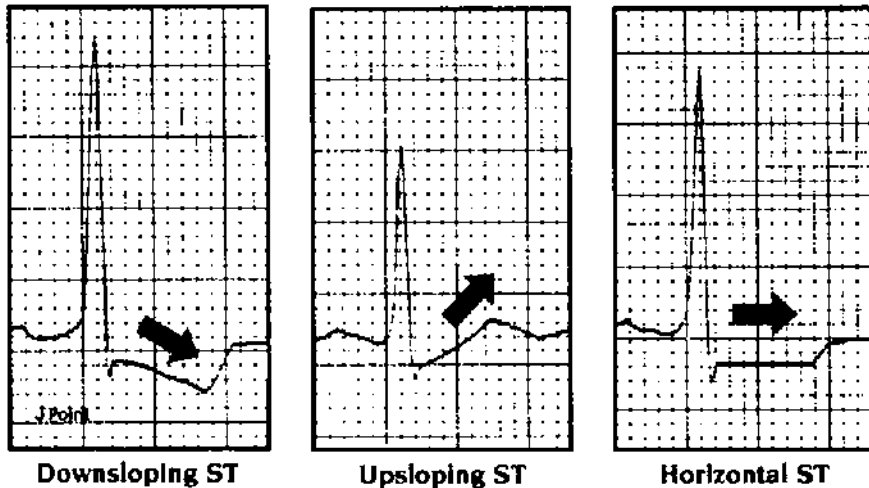
Angina occurs when there is a mismatch between myocardial oxygen supply and demand. The initiating event in *chronic stable angina* is increased demand with exercise or stress. Reducing demand with rest, nitrates, or beta blockers provides relief. The coronary artery stenosis does not change and is stable. Thus, the angina threshold—the increase in cardiac work that provokes angina—is the same from week to week.

During ischemia, the ST segment is depressed well below baseline (see Fig 2.10). In addition, the ST segment has a check mark or hockey-stick appearance, and the segment is either horizontal or downsloping (Fig 2.11). This is the typical shape of ST segments depressed by subendocardial ischemia. A depressed but up-sloping ST segment is not as specific for ischemia (see Fig 2.11). In this case, the **J point**—the junction between the QRS complex and the beginning of the ST segment—is depressed below the baseline, but the ST segment moves rapidly upward.

Poor specificity is a fundamental problem with the diagnosis of subendocardial ischemia based on ST depression. Other conditions may cause ST depression including LVH,

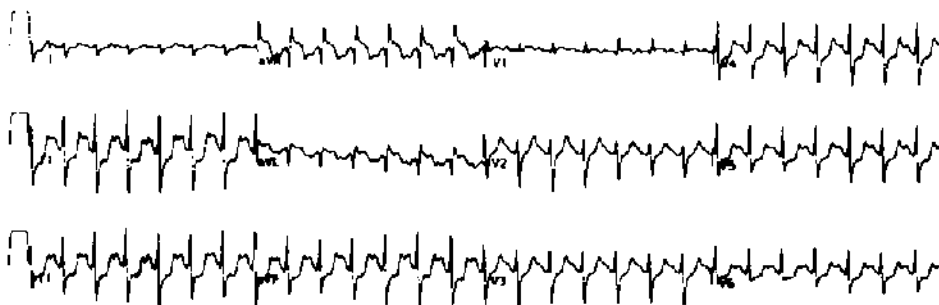

FIGURE 2.10 Positive stress ECG. At rest, the patient's ECG was normal. While walking on the treadmill, she developed ST segment depression (inferior and lateral leads). Within 3 minutes, she experienced chest heaviness, and exercise was stopped.



ST Segment Depression

FIGURE 2.11 ST segment depression. The J point is the junction of the QRS complex and the beginning of the ST segment. Downsloping and horizontal ST depression are more specific for subendocardial ischemia than is J point depression with upsloping ST's (middle tracing).

digitalis, and hypokalemia. It is a common finding in older patients both with and without a history of ischemic heart disease. ST depression on a routine ECG does not necessarily indicate the presence of coronary artery stenosis, and in the absence of any clinical history you should consider it a nonspecific finding. Associated T wave flattening and inversion are common; their presence does not change the fact that the findings are nonspecific.

Nonspecific ST-T wave changes (NSSTWCs) is a frequently applied ECG interpretation. Do not be frustrated by this or consider it a cop-out; instead, accept it as the interpretation of a reader who understands the limitations of the ECG.

ST depression may become diagnostic when it is placed in clinical context. The stress test is a good example (see Fig 2.10). An ECG obtained during chest pain and that can be *compared with a previous tracing* is another. For a patient with chest pain of uncertain etiology, finding ST depression during pain helps make the diagnosis of angina pectoris. The absence of ST segment changes with pain makes coronary disease less likely.

T Wave Inversion

T wave inversion may be observed *during* acute ischemia (i.e., during chest pain), and it is often associated with ST segment changes, either depression or elevation. T inversion that develops during chest pain, like ST depression, is evidence of a cardiac etiology. It may also be a permanent finding after pain has resolved. In that case, T inversion may indicate injury. Deep, symmetrical T inversion is the ECG finding of non-Q wave infarction, also called nontransmural or subendocardial infarction, and, more recently, non-ST elevation infarction (Fig 2.12).

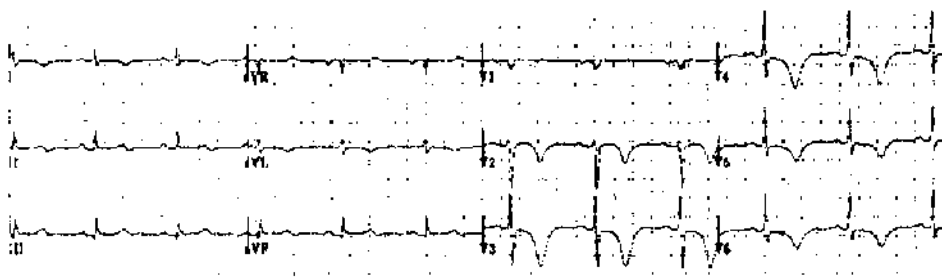


FIGURE 2.12 Anterior, non-ST elevation MI. This may be called subendocardial, nontransmural, or non-Q MI. There is deep and symmetrical T wave inversion in the anterior leads. The QT interval is long; this is not a criterion for non-Q MI, but may accompany it.

Let us backtrack a moment and be sure that we understand the sequence of events with ischemia (see Table 2.3 and Fig 2.9). It is the direction of ST segment shift that distinguishes subendocardial from transmural ischemia. The combination of chest pain and ST depression indicates ongoing, subendocardial ischemia. If pain is prolonged and there is myocardial injury, T wave inversion develops and may be permanent. Deep and symmetrical T wave inversion is the non-Q wave infarct pattern, and ST depression may resolve when the pain (active ischemia) is over. With non-Q wave infarction, injury is limited to the subendocardium, not the full thickness of the ventricle (see Fig 2.9). Cardiac catheterization during the acute phase of non-Q wave MI (during pain) shows that the infarct artery is tightly stenosed but that there is still some antegrade flow.

CLINICAL INSIGHT

The traditional distinction between subendocardial and transmural infarction provides a tidy explanation but is not completely accurate (Fig 2.9). Recent studies indicate that the main difference between the two is the size of the MI and not necessarily the location of injury within the myocardium. The non-Q wave MI is smaller. Less injury is good, as myocardium is irreplaceable. On the other hand, the smaller MI may be “incomplete.” Early angiography usually shows a tightly stenosed artery with unstable appearing plaque surface, indicating a risk of occlusion and “completion” of the MI. Non-ST elevation MI is therefore an indication for cardiac catheterization and possible revascularization.

Nonischemic cardiac conditions, including pericarditis and virtually any disease that affects the myocardium, may cause T wave inversion. Children and young adults without heart disease may have T inversion, the so-called juvenile pattern.

Intracranial bleeding may cause deep T wave inversion; look for this on Board exams. The ECG recording in Figure 2.12 could be the result of intracranial hemorrhage. Pathologic studies have shown that most of these patients suffer subendocardial myolysis at the time of the bleed—the T wave changes come from the heart, not the brain. Sympathetic discharge at the onset of bleeding may be the mechanism.

Nonischemic heart disease, such as pericarditis or myocarditis, generally produces global changes, altering ST segments and T waves in anterior, inferior, and lateral leads. Remember that changes resulting from ischemia are usually limited to one vascular region.

ST Segment Elevation

The most common cause of ST segment elevation is transmural MI, now called ST-elevation MI. Catheterization during chest pain and ST elevation shows a coronary artery that is totally occluded. ST elevation is the primary ECG indication for emergency angioplasty or thrombolytic therapy. Compared with ST segment depression, ST elevation is a more specific indication of acute ischemia. Most patients with new ST elevation are in the emergency room with chest pain.

PATHOPHYSIOLOGY

Note the basic differences between chronic stable angina and the acute coronary syndromes including unstable angina, non-ST and ST elevation MI. With stable angina, the lesion is fixed and angina is caused by an increase in oxygen demand. With the acute coronary syndromes, the lesion is variable, and it is a drop in supply that initiates chest pain. It often occurs at rest. In most cases this is due to unstable plaque surface that has attracted platelets.

Acute MI with ST segment elevation is a dramatic finding on the ECG (Figs 2.13 and 2.14). Review these tracings from seven patients with inferior or anterior MI. The ST elevation is limited to leads that reflect a single vascular distribution (see Fig 2.8). Patients with large transmural infarction who have ST segment elevation may also have ST depression in leads reflecting nonischemic myocardial regions (see Fig 2.13). The ST depression is called *reciprocal ST depression*, and it does not indicate ischemia in the noninfarct zone.

Not all ischemic ST elevation leads to injury. Vasospastic, or Prinzmetal's, angina pectoris also causes ST elevation. An angiogram obtained during a spontaneous episode, or with provocative testing with ergonovine infusion, usually shows total coronary occlusion. This would induce full thickness—transmural—ischemia in that vascular distribution. The ST elevation and chest pain are usually self-limited, or respond to nitrates and calcium channel blockers. MI is an uncommon complication of spontaneous coronary vasospasm. However, cocaine-induced spasm may cause infarction or sudden cardiac death.

Although more reliable than ST segment depression, ST elevation is not specific for ischemia, and it must be interpreted in clinical context. Two nonischemic causes of ST elevation deserve special attention.

- 1. Acute pericarditis** may cause ST elevation and chest pain, raising the possibility of acute MI (Figs 2.15 and 2.16). Features that may help you distinguish the ST elevation of pericarditis from that caused by ischemia are reviewed in Table 2.4. Although these features are helpful when found, they may also be subtle or missing. There may be uncertainty about the diagnosis, and the ECG is just one piece of the puzzle. The clinical presentation is just as important as the ECG.

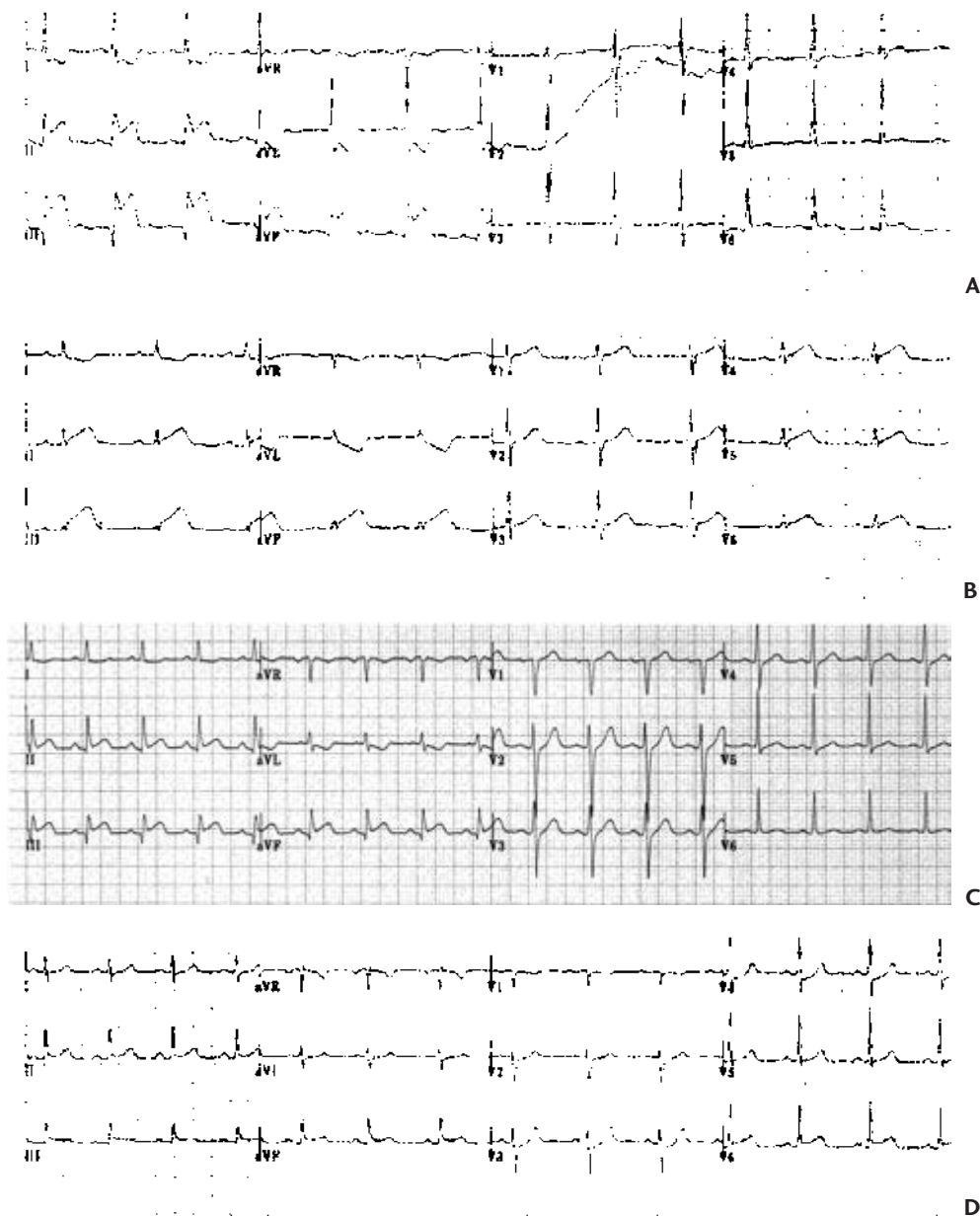


FIGURE 2.13 Four patients with acute inferior MI. The size of inferior MI is proportional to the sum of ST elevation in the three inferior leads. In addition, those with reciprocal ST depression in anterior or lateral leads tend to have larger infarctions. Using these criteria, patient **A** was having the largest MI, patients **B** and **C** moderate-sized MIs, and patient **D** a small infarct. Patient **B** also had ST elevation in V_5 and V_6 ; this may be called an inferolateral MI. In this case, the distal right coronary artery in the AV groove was large, and it terminated in a branch to the lateral wall (see Fig 2.8).

Patient **D** is an arguable case of infarction, as the ST segment elevation is minimal. I am tempted to say that the mild J point depression in V_2 through V_4 represents reciprocal ST depression; typical chest pain and a subsequent rise in cardiac enzymes would be needed to make the diagnosis of MI with certainty in this case. The ECG changes of ST segment elevation infarction are usually obvious, but there are borderline cases like this one. As a rule, such borderline cases involve small MIs; with big ones there is little doubt.

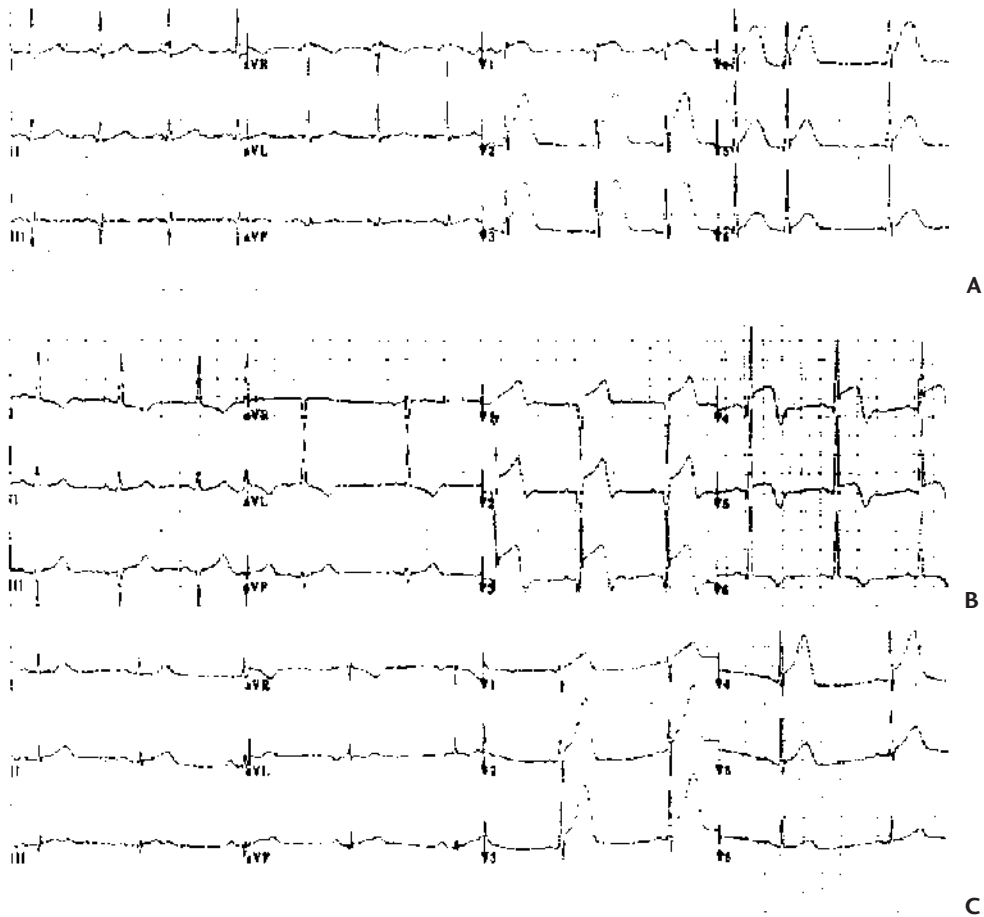


FIGURE 2.14 Three patients with acute anterior MI and ST elevation. Patient **A** has upwardly convex ST segments. Patient **B** has similarly shaped STs in V_3 through V_5 , but still has some upward concavity in V_1 and V_2 . This patient has developed T inversion in addition to ST elevation (see Table 2.1). Patient **C** has ST elevation plus tall, peaked T waves. These T wave changes may be called *hyperacute*, and they would indicate ischemia in the absence of ST elevation.

The size of anterior MI is proportional to the number of leads with ST elevation. Each of these patients has ST elevation in five different leads and is having large infarction.

- 2. Early repolarization** is a common cause of ST elevation. The cause is not certain, but the name suggests that some portion of the ventricle repolarizes before the obvious onset of the T wave, raising the ST segment. As with pericarditis, ST segment elevation may be global rather than regional (although it may be limited to just one or two leads), and the ST segment usually has normal upward concavity. It is often difficult to distinguish early repolarization and acute pericarditis. Depression of the PR segment is a specific finding for pericarditis (see Fig 2.15). Early repolarization is a benign condition, common in young people. There is little day-to-day variation in this pattern, so comparison of the ECG with previous tracings should help make the diagnosis.

CLINICAL INSIGHT

ST segment elevation resolves over a day or two after acute MI. But an occasional patient with anterior MI has chronic ST segment elevation. This ECG finding suggests left ventricular aneurysm.

Q Waves and Evolution of Myocardial Infarction

An initial negative deflection of the QRS complex is labeled a Q wave. A significant Q wave is deep and broad, at least 1 mm deep and 1 mm wide. Isolated Q waves may be normal in leads III or V₁; in other leads, Q waves are abnormal and indicate transmural myocardial injury (see Fig 2.9).




FIGURE 2.15 Acute pericarditis. This 19-year-old man had a 2-week history of the flu. There was mild fever. On the morning of this ECG, he developed chest pain that worsened with deep breathing (e.g., pleuritic pain). On exam, there was a pericardial friction rub. The ECG shows ST elevation in multiple leads, and there is no reciprocal ST depression. The STs are upwardly concave. There is depression of the PR segment in leads II and aVF, and probably in III; PR depression makes the diagnosis of pericarditis more certain.

3 Patients with ST Segment Elevation

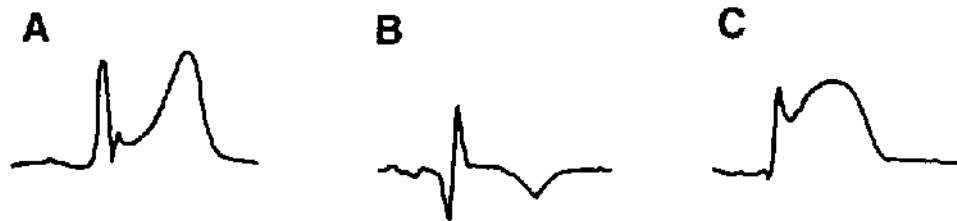


FIGURE 2.16 ST segment elevation. Patient **A** still has the normal upward concavity of the ST segment. This is usually the case with pericarditis, although we have seen similar ST changes with acute, transmural ischemia (see Fig 2.14). Patient **B** has simultaneous ST elevation and T inversion. This combination indicates ischemia. The T waves may invert with pericarditis, but the ST's usually become isoelectric before the T's turn over. Patient **C** has an upwardly convex ST segment; this usually indicates ischemia.

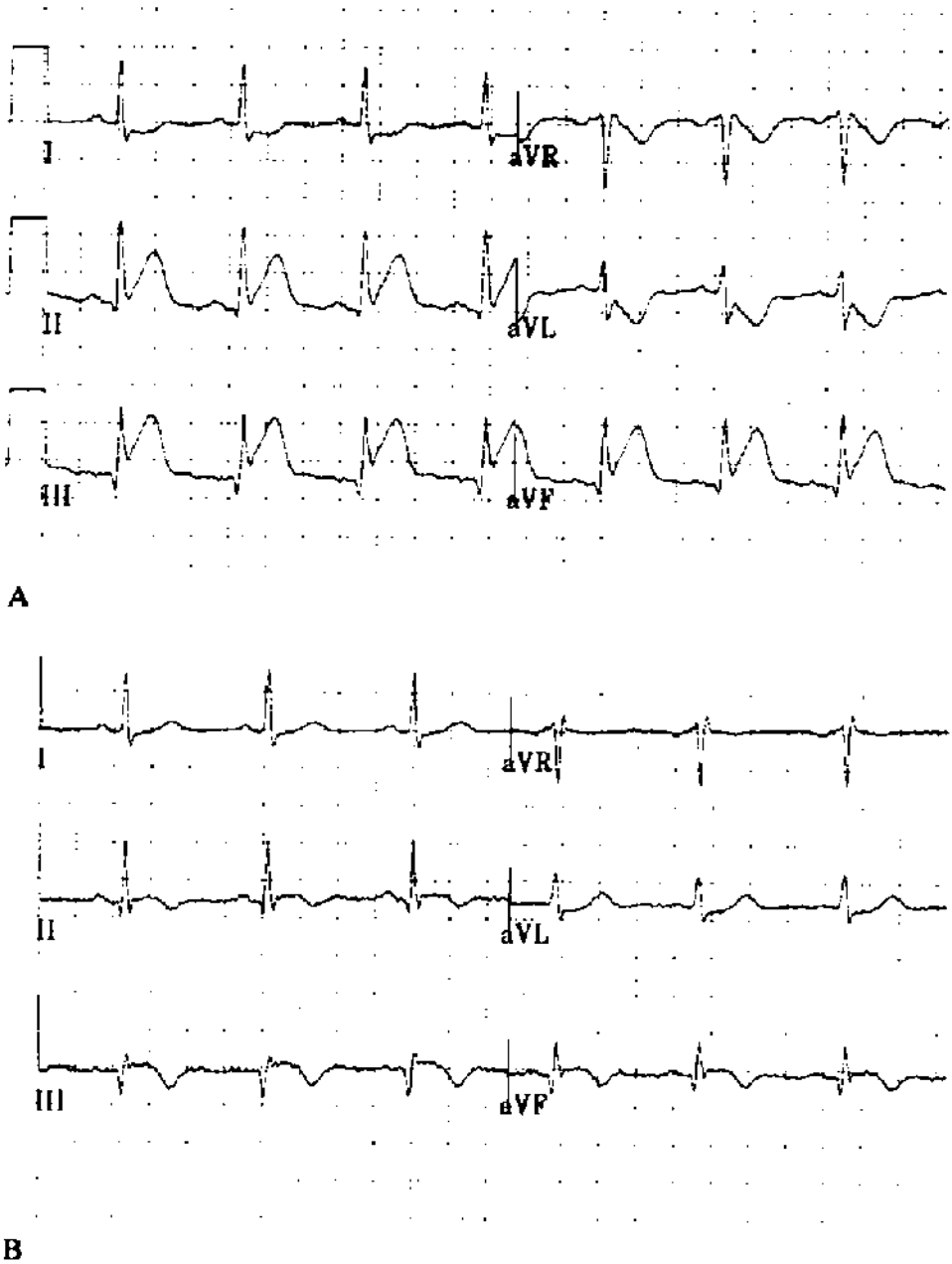


FIGURE 2.17 Typical evolution of transmural MI. **A:** Limb leads from a patient with acute MI who had inferior ST elevation plus reciprocal ST depression in lateral leads. **B:** The next day there was less ST elevation, the reciprocal ST depression had resolved, and the T waves were inverted in the inferior leads. Deeper Q waves developed in the inferior leads.

Table 2.4 ST Segment Elevation: Pericarditis versus Ischemia

	Pericarditis	Ischemia
Distribution	Global (multiple vascular distributions)	Regional (one vascular distribution)
Reciprocal ST depression	Absent	May be present
ST segment shape	Normal (upwardly concave)	Ischemic (upwardly convex)
PR depression	Present (see Fig 2.15)	Absent
Timing of T inversion	T's invert after ST's become isoelectric	T's invert while the ST's are still elevated

In the absence of acute reperfusion therapy, the ECG pattern of MI evolves over a couple of days (Fig 2.17 and Table 2.3). The earliest change is ST segment elevation, and this develops immediately with coronary occlusion. It may be associated with tall, peaked T waves, also called *hyperacute T waves* (see Fig 2.14D). Within hours, the T waves may become inverted while there is persistence of ST elevation. Hours to days after the onset of MI, Q waves appear. The diagnosis of MI is most secure when these evolutionary changes are recorded on serial ECGs. ST elevation without evolutionary changes suggests a nonischemic etiology.

CLINICAL INSIGHT

The concept of *complete versus incomplete MI* is useful. A patient who has had a Q wave infarction but who develops postinfarction angina may have viable muscle in the infarct zone (the source of angina). The usual mechanism for this is spontaneous thrombolysis early in the course of MI. As with thrombolytic therapy, an hour or two of ischemia is enough to cause Q waves, even though injury is incomplete and there is residual, viable muscle. As noted, early reperfusion seems to hasten the evolution of Q waves.

This is the mechanism for what used to be called *extension of MI*. Recurrent pain, more ST elevation, and another increase in cardiac enzyme during the week after a Q wave infarction may indicate that the initial infarction was incomplete, possibly because of spontaneous thrombolysis. Reocclusion of the infarct artery is responsible for recurrence, or “extension,” of the MI.

While ST elevation and T wave inversion may resolve during the 2 weeks after acute MI, Q waves persist in 70% to 90% of patients. They may disappear after a small inferior MI, but Q's tend to be permanent after a large MI.

Reperfusion therapy for MI has changed some of this. The evolution of ECG changes is more rapid. When the occluded infarct artery is opened, the ST segment elevation either resolves or improves. That is not always the case, and persistent elevation of ST segments may indicate microvascular injury, even though the large coronary artery is open. Prompt resolution of ST elevation is the best indicator of successful reperfusion and myocardial salvage.

Q waves develop rapidly with reperfusion, possibly within minutes. Our experience with reperfusion also has provided new insights into the significance of Q waves. In the old days, I was taught that Q waves meant transmural scar with loss of all muscle (and, therefore, a loss of contractility). Now we know that deep Q waves may develop even when there is early reperfusion and only partial injury to muscle in the infarct zone. Thus Q waves do not reliably define an LV segment as irreversibly damaged—or the infarction as completed.




FIGURE 2.18 Acute lateral MI. ST elevation is limited to the lateral leads, I, and aVL. It is possible to have ST changes in just V₆, or in V₅ and V₆. And it is also possible to have lateral, transmural ischemia with no ECG changes at all.

Lateral Wall MI

The ECG criterion for transmural MI is pathologic Q waves. Occlusion of the circumflex artery may cause ST segment elevation in lateral leads (Figs 2.8 and 2.18). However, it is possible to have transmural injury involving the lateral wall of the LV with few ST segment or T wave changes and without Q waves. The lateral wall seems to be an electrocardiographically silent region of the heart (see Fig 2.8). The patient may have typical chest pain and a subsequent rise in cardiac enzymes and may even be left with akinesis (no contractility) of the lateral wall. Yet the ECG may be unchanged throughout the course of MI. This is the rationale for extended observation and cardiac enzyme measurement when there is typical, ischemic chest pain but a normal ECG, or one that does not provide the usual evidence for acute MI.




FIGURE 2.19 Pseudoinfarction pattern caused by pre-excitation (Wolff-Parkinson-White syndrome). The inferior Qs are, in fact, delta waves. The tip-off is the short PR interval plus the more obvious delta wave in the lateral precordial leads.

Silent MI, Pseudo MI

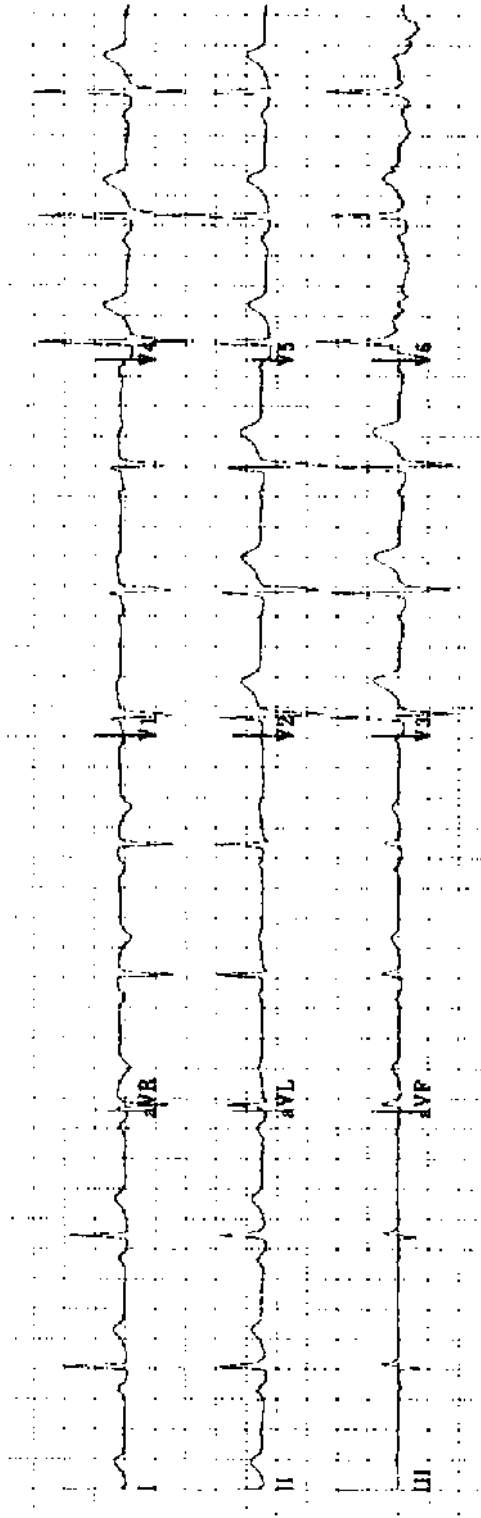
The opposite side of the coin is the patient with no symptoms who has significant Q waves, and an akinetic LV segment involving the same vascular region (i.e., anterior Q waves and anterior akinesis on the echocardiogram). Taking a careful history, you may get the patient to remember vague symptoms that could have been the infarction, but in many cases there are no symptoms at all. This is the case with at least 20% of MIs, and it may be more common in patients with diabetes and diabetic neuropathy. It is important to recognize silent ischemic heart disease because it is associated with a poor prognosis.

Poor R wave progression may begin with Q waves in V_1 – V_2 , raising the possibility of prior anterior MI. This is easily sorted out with an echocardiogram which identifies an anterior and septal wall motion abnormality after infarction.

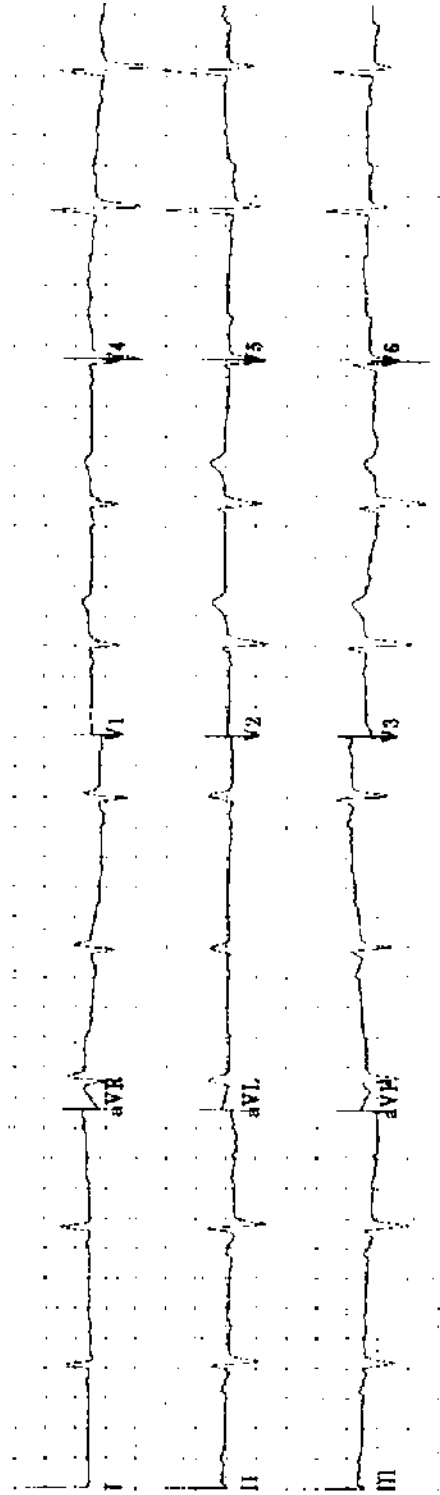
A couple of conditions may produce false-positive Q waves. The delta wave of pre-excitation may appear to be a Q wave (Fig 2.19). Recognition of the short PR interval, the absence of a clinical history of MI, and a normal echocardiogram are tip-offs. Q waves may be seen in patients with hypertrophic cardiomyopathy; the physical examination suggests the diagnosis and it is confirmed by echocardiography.

150 Practice ECGs

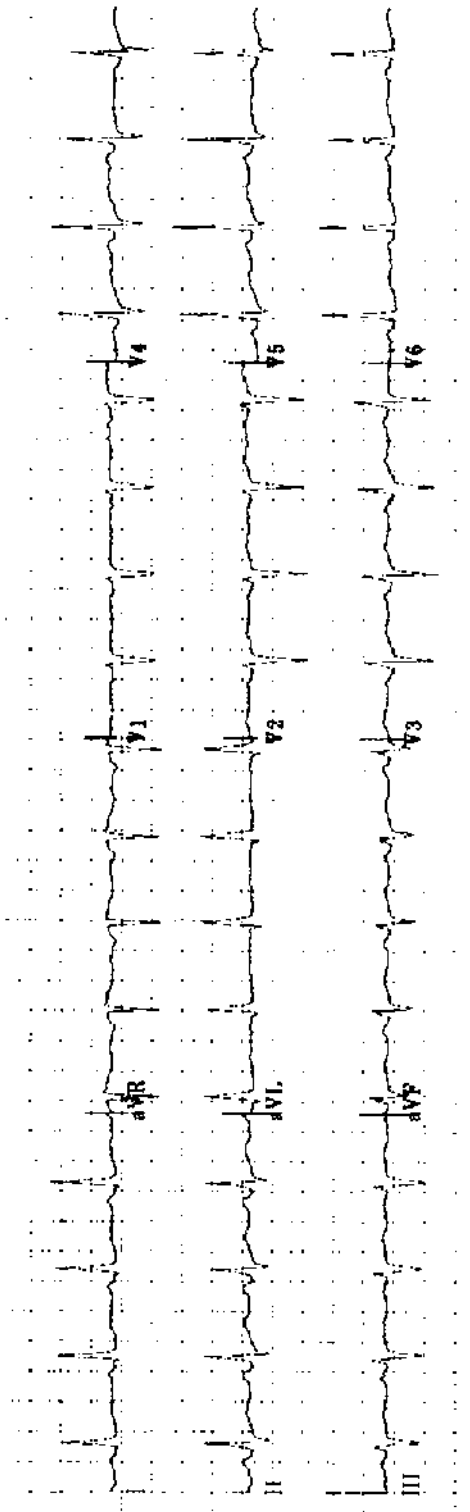
As you read the practice ECGs, write the ECG report including rate, rhythm, intervals, axis, and interpretation. If you do not commit yourself on paper, it does not count! Read five to ten ECGs in a row before checking answers. There is a rhythm to this exercise that you should not interrupt. After you have read 150 ECGs, you will be reading them with confidence.



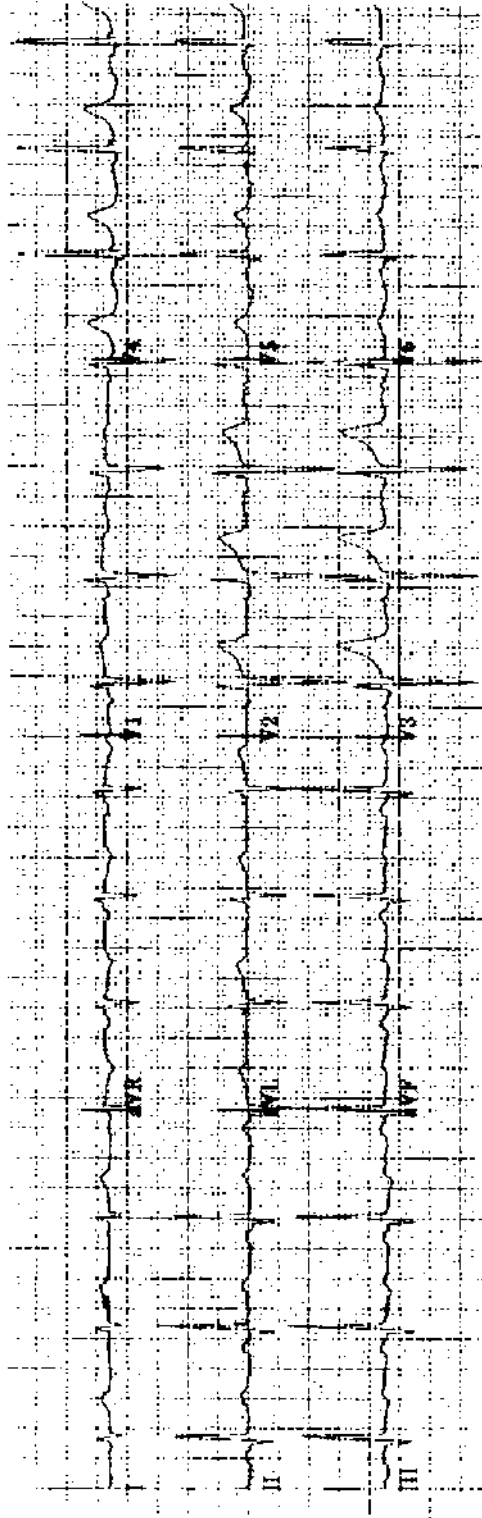
Practice ECG 1 A 57-year-old man, preoperative ECG.




Practice ECG 2 A 78-year-old man, no history provided.



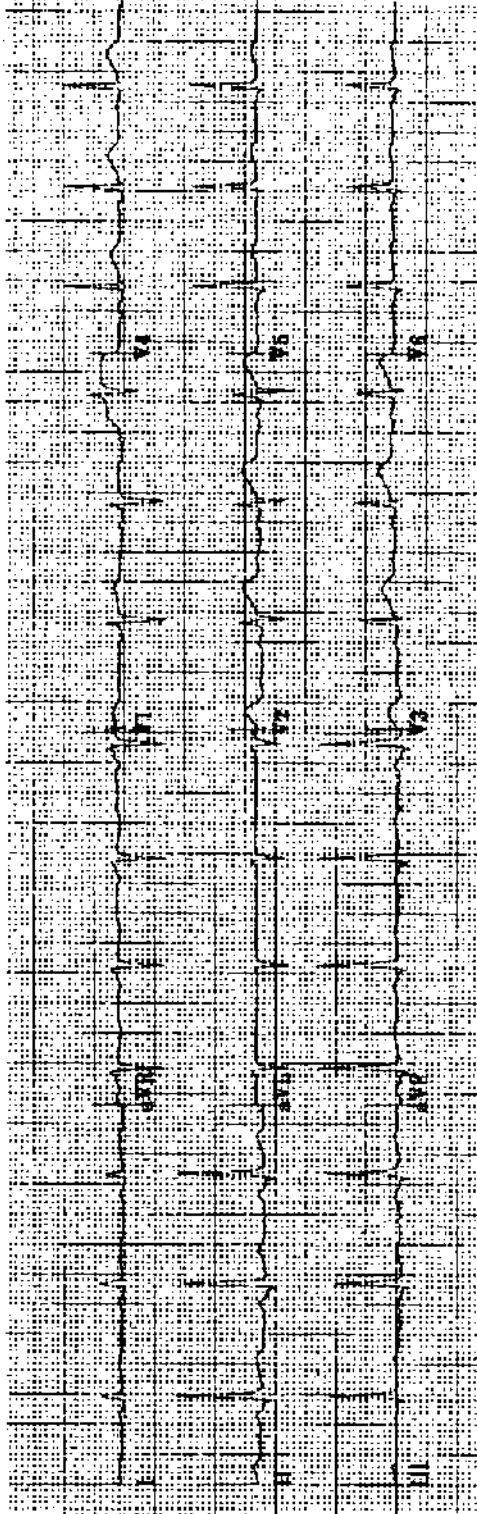
Practice ECG 3 A 54-year-old woman, admitted with cholecystitis.



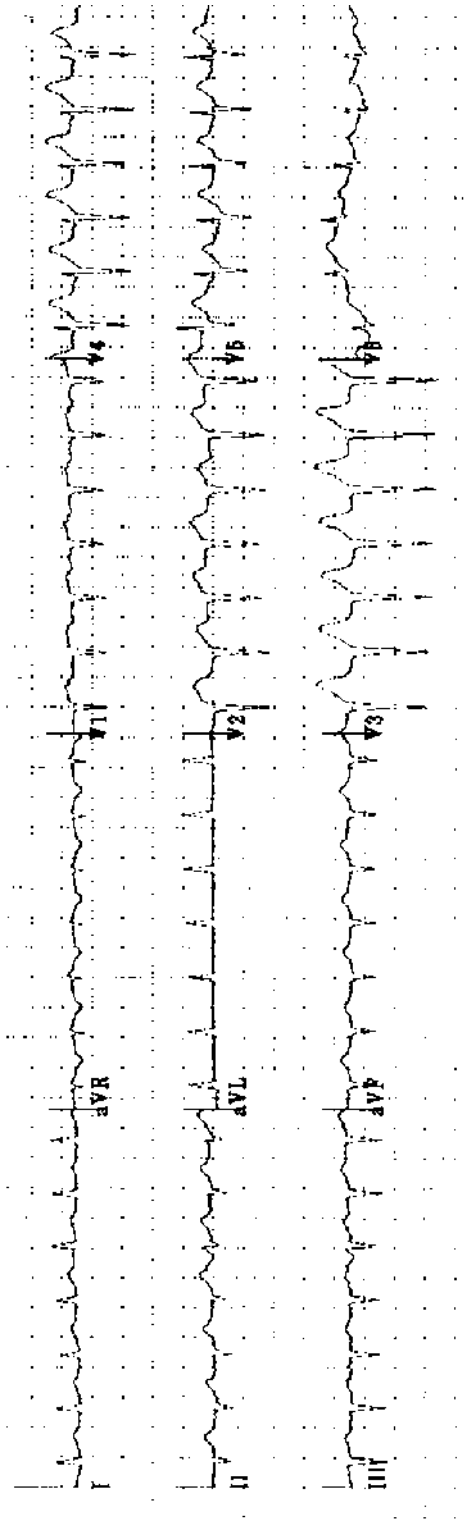
Practice ECG 4 A 49-year-old man, no history given. Has he had an MI? When?



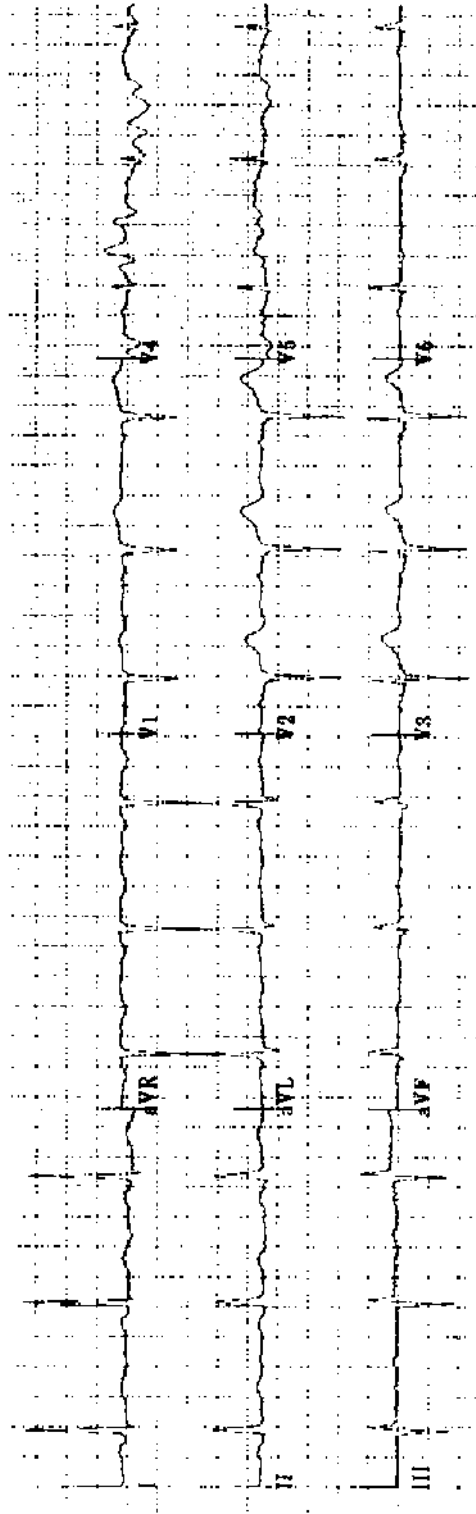
Practice ECG 5 A 78-year-old woman with a history of MI is now in the emergency room with chest pain. There is a prior ECG for comparison. Can you be sure that her pain is due to MI?



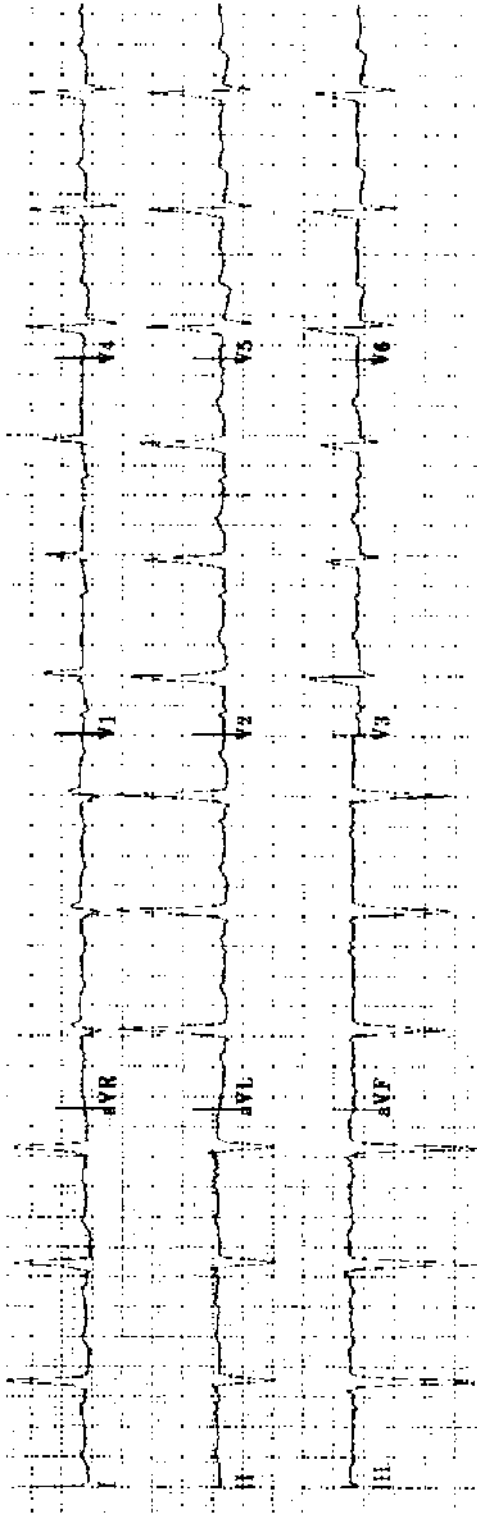
Practice ECG 6 A 36-year-old man; life insurance examination, no history of heart disease.



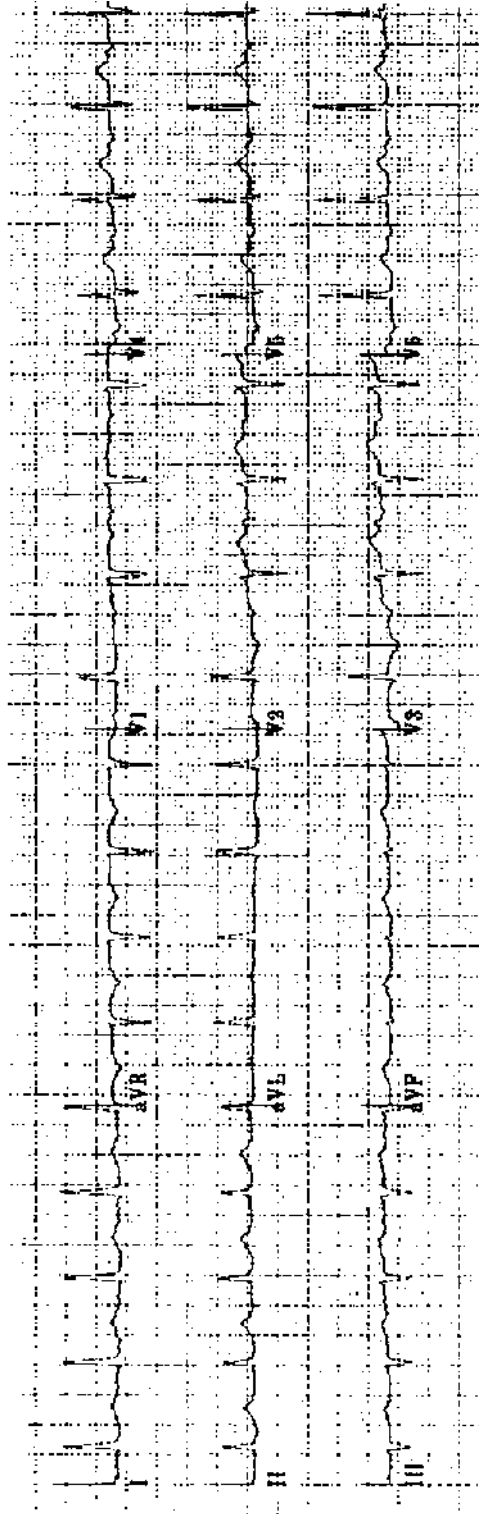
Practice ECG 7 A 79-year-old man brought from the nursing home with a rapid pulse.



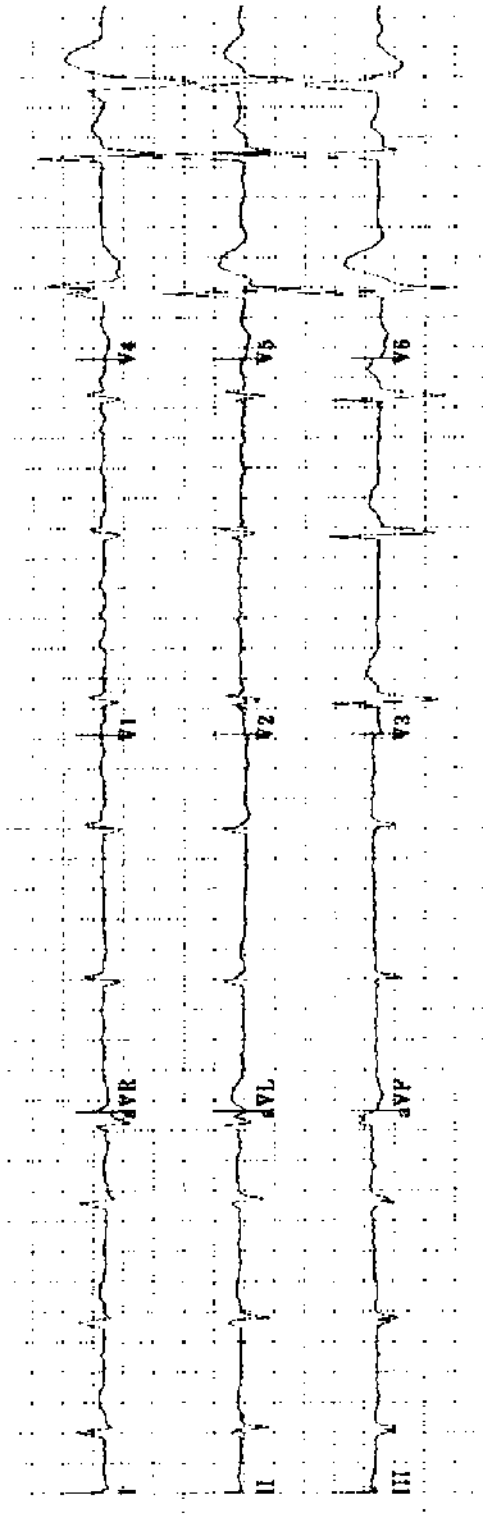
Practice ECG 8 A 72-year-old woman with heart failure. What is the cause?



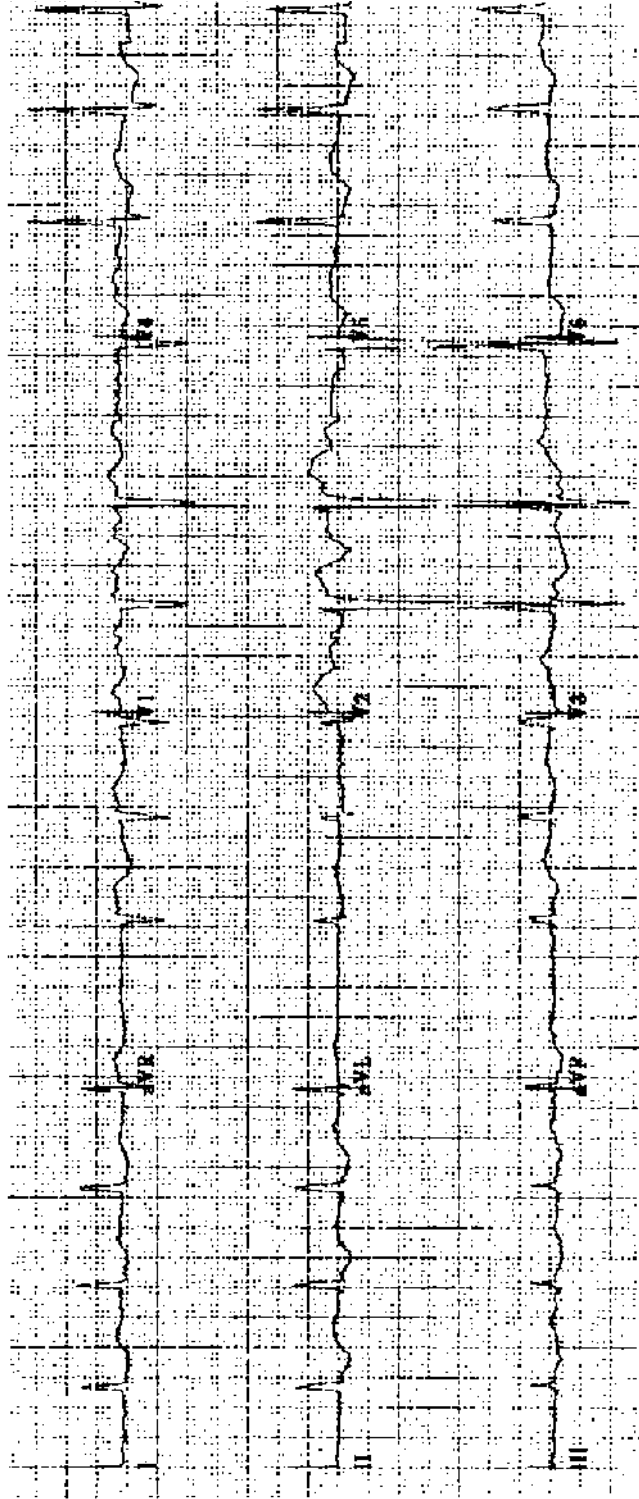
Practice ECG 9 An active 82-year-old woman with hypertension. Should we worry about possible syncope?



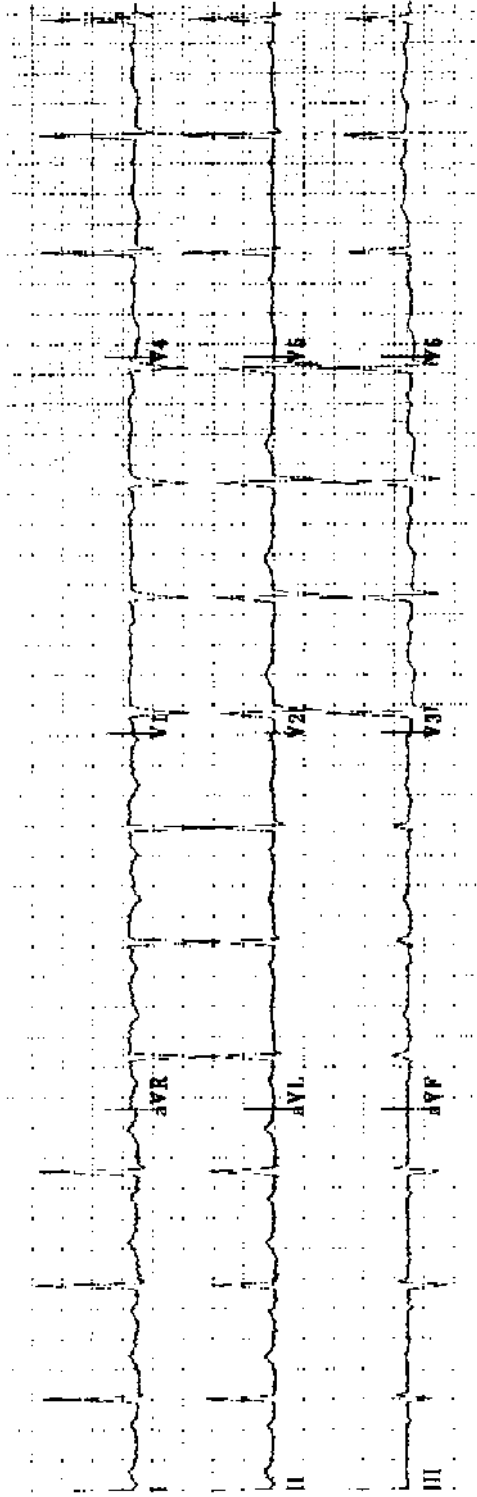
Practice ECG 10 A 94-year-old woman with failing memory.



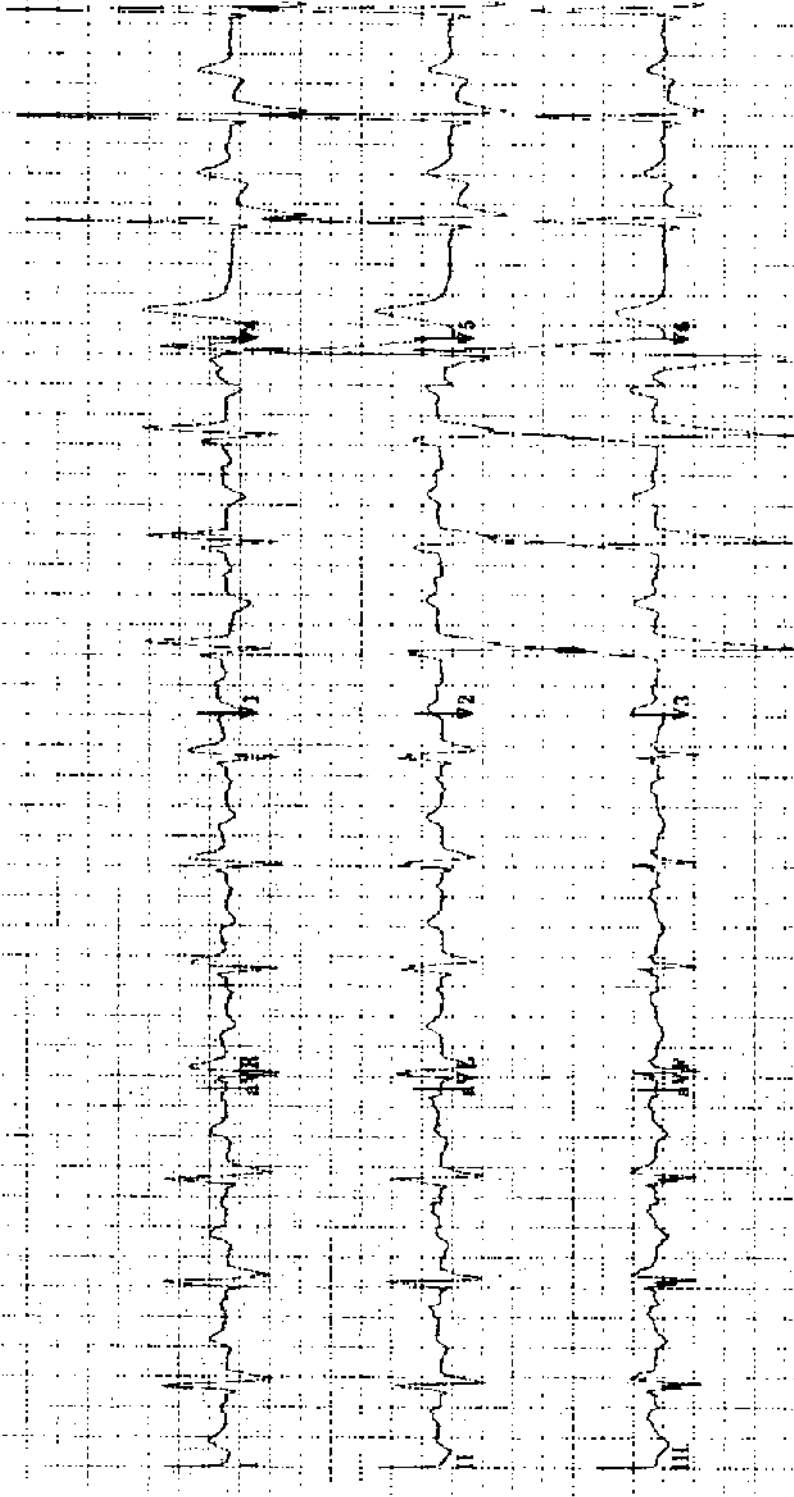
Practice ECG 11 A 72-year-old man with a long history of heart disease, on digoxin.



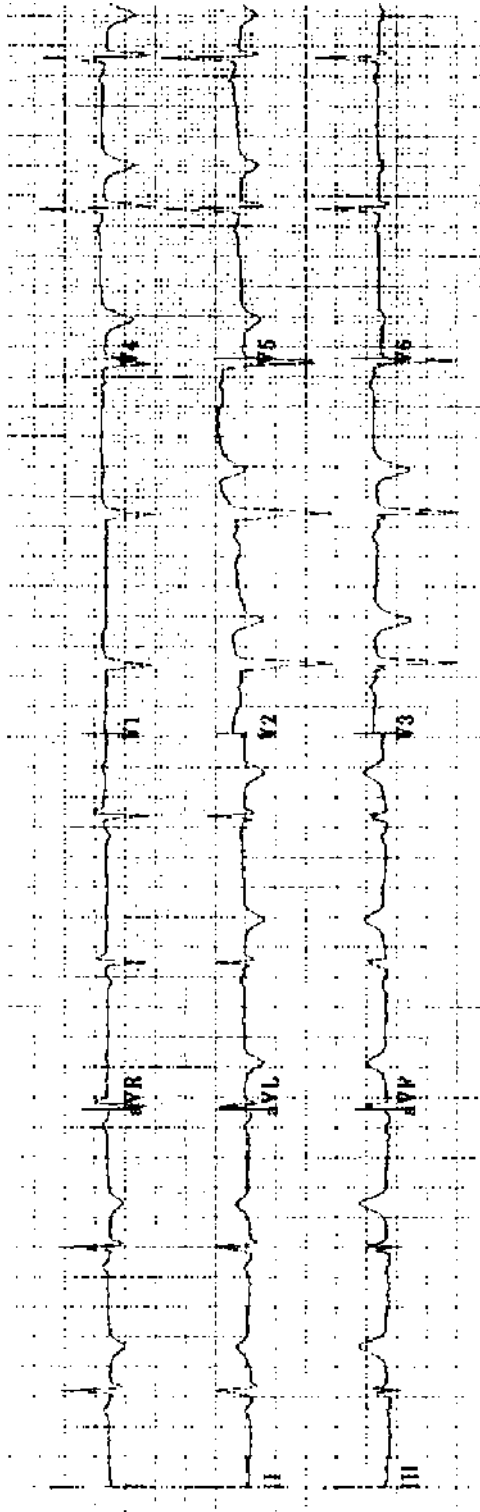
Practice ECG 12 A 75-year-old woman with hypertension, on multiple medicines. Can you identify one of them?



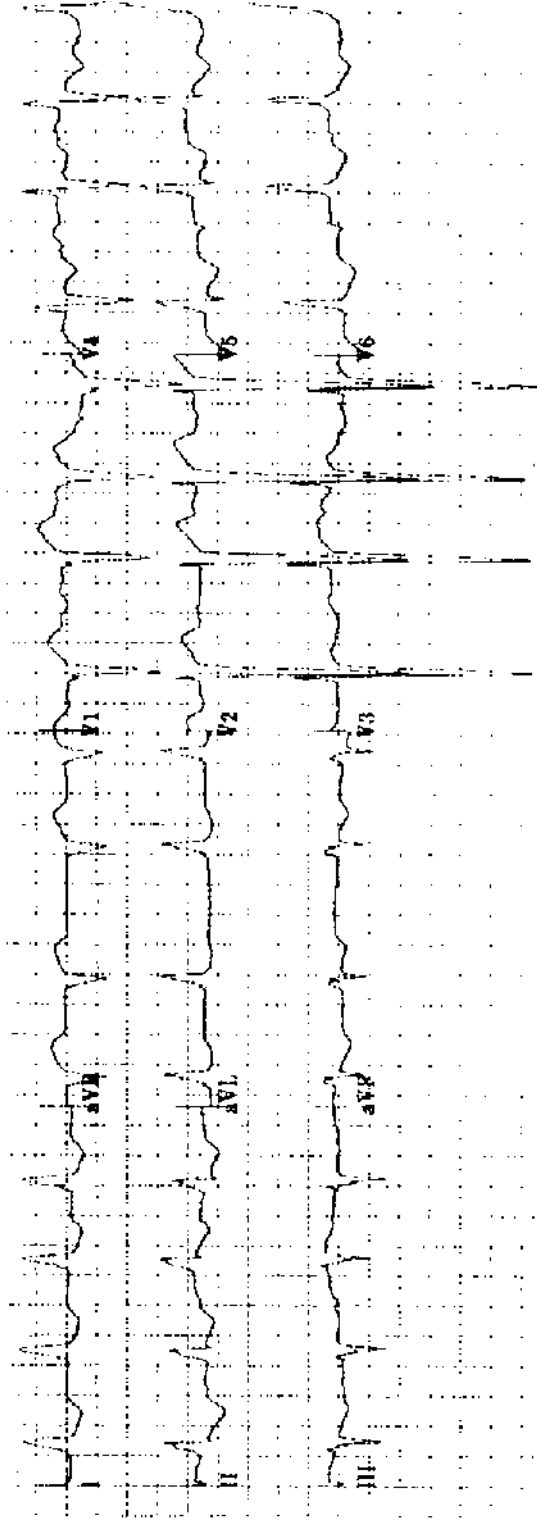
Practice ECG 13 A 48-year-old woman; routine exam.



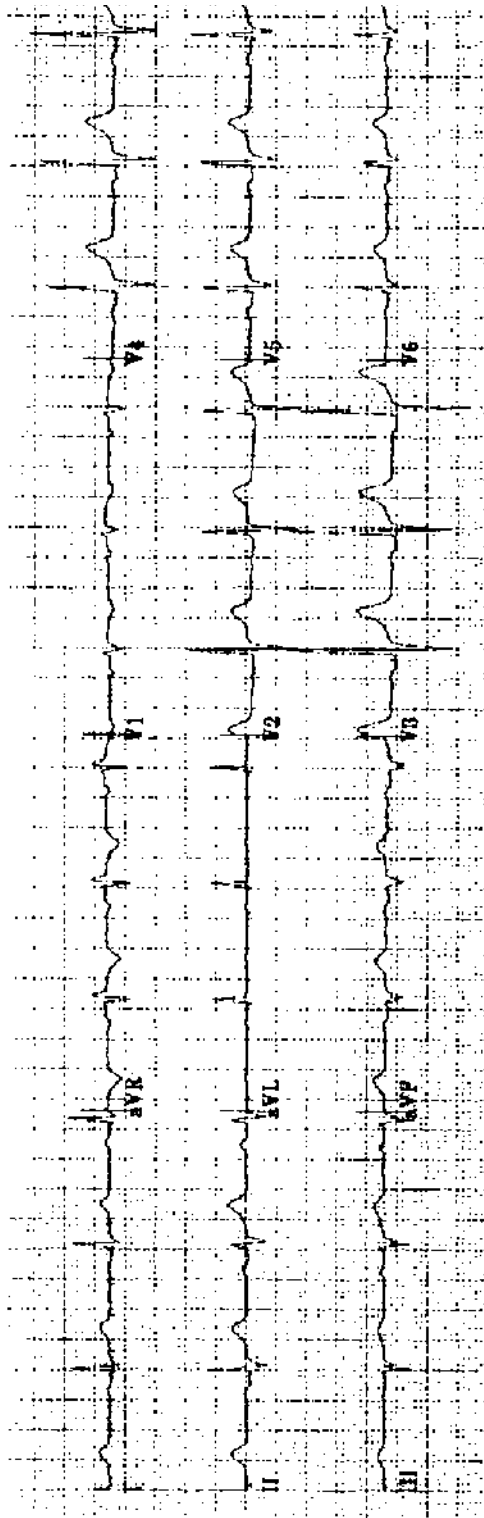
Practice ECG 14 A 67-year-old man; no history provided.



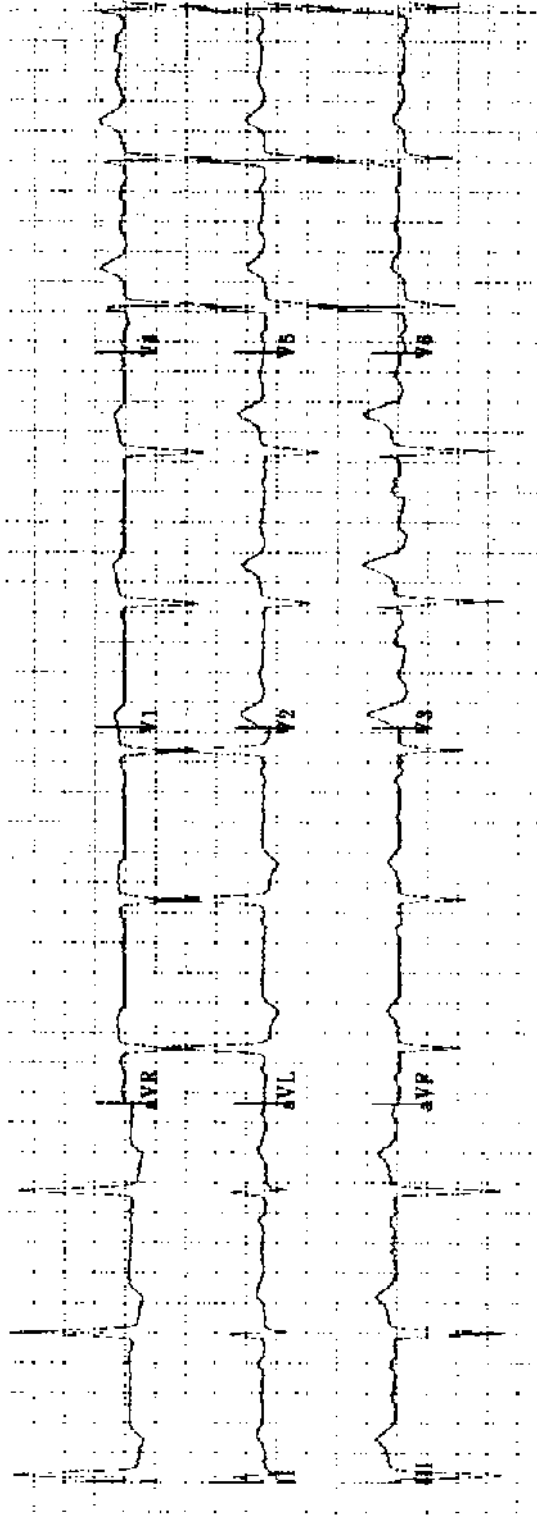
Practice ECG 15 A 43-year-old woman with history of MI is in the emergency room with lower chest, epigastric discomfort not quite like the heart attack pain. Would you consider thrombolytic therapy?



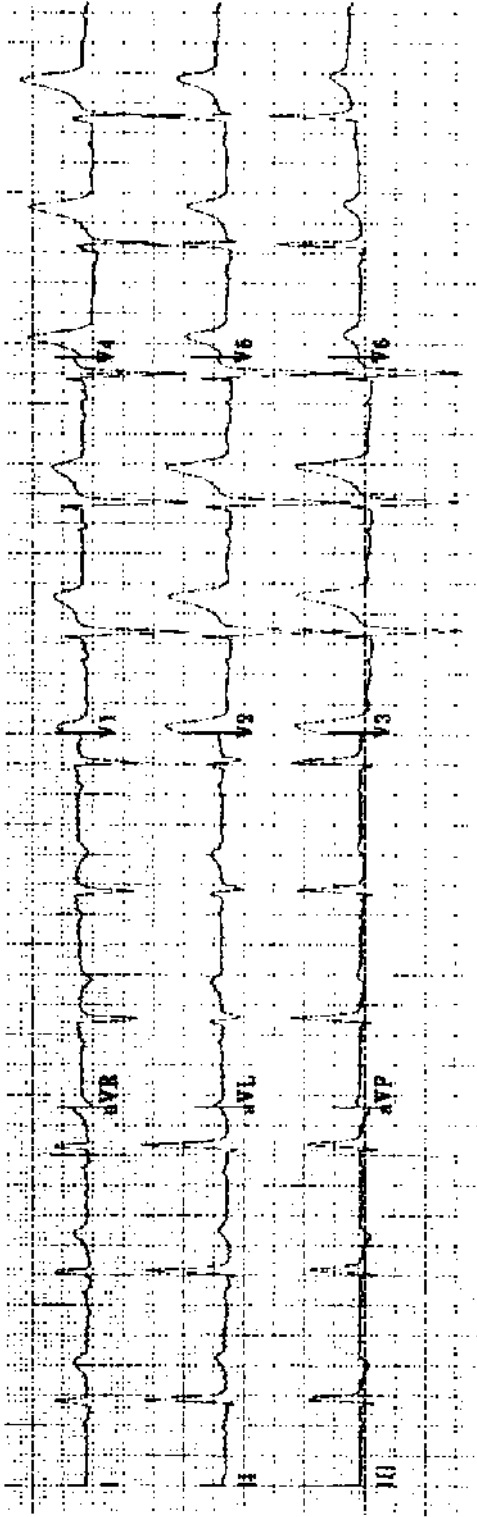
Practice ECG 16 A 73-year-old woman with blood pressure 150/75 and no history of heart disease. Should she be treated for isolated systolic hypertension?



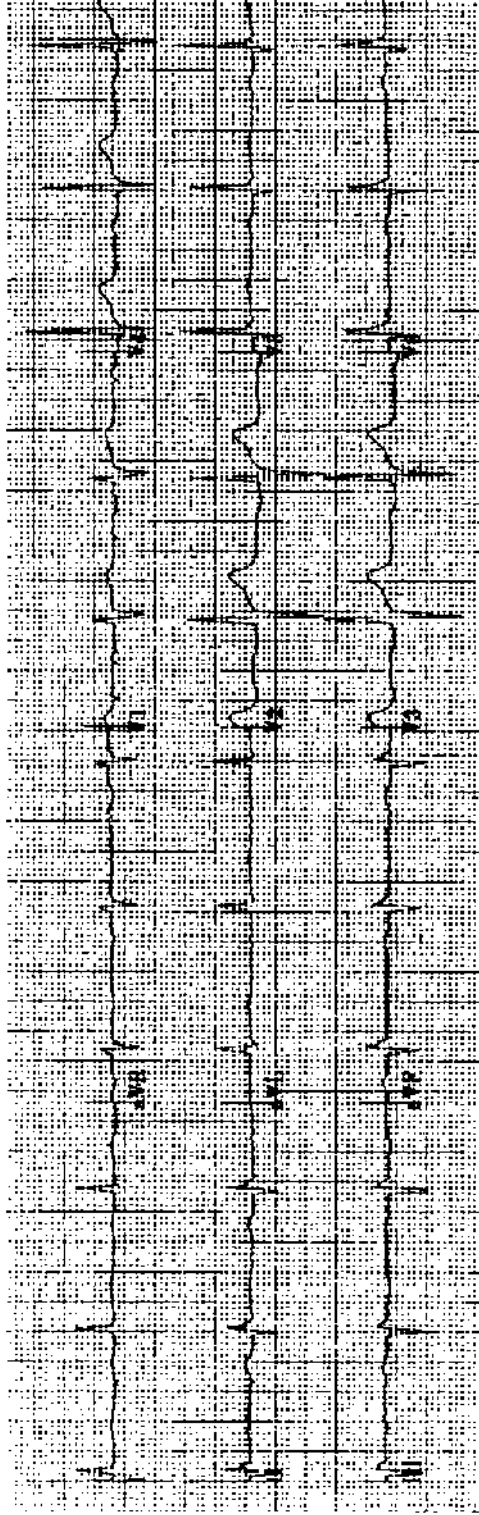
Practice ECG 17 A 46-year-old man; routine exam. Normal or abnormal?



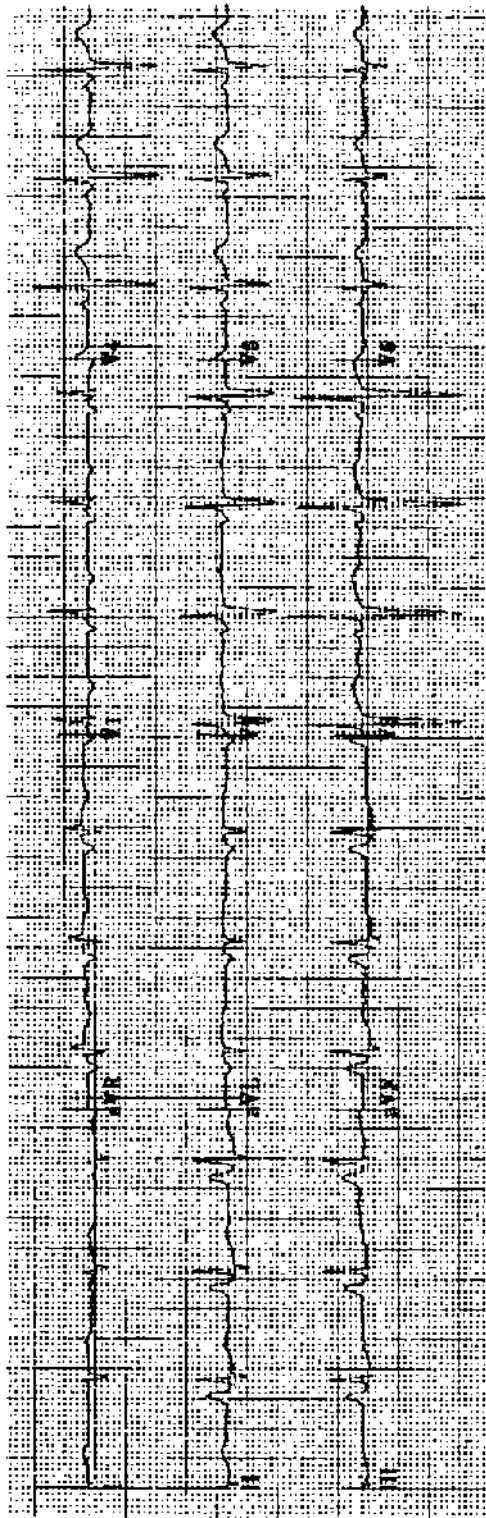
Practice ECG 18 An 89-year-old woman with dizziness when she stands.



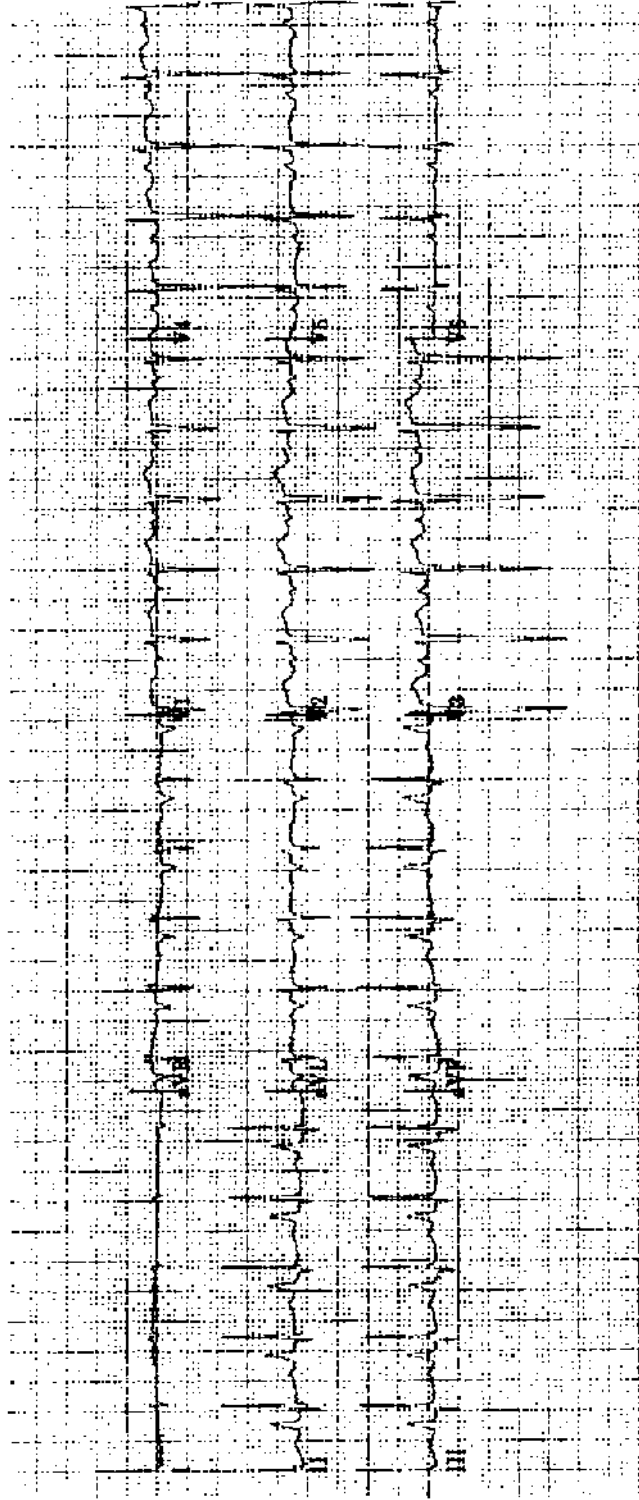
Practice ECG 19 A 74-year-old man; no clinical data provided.



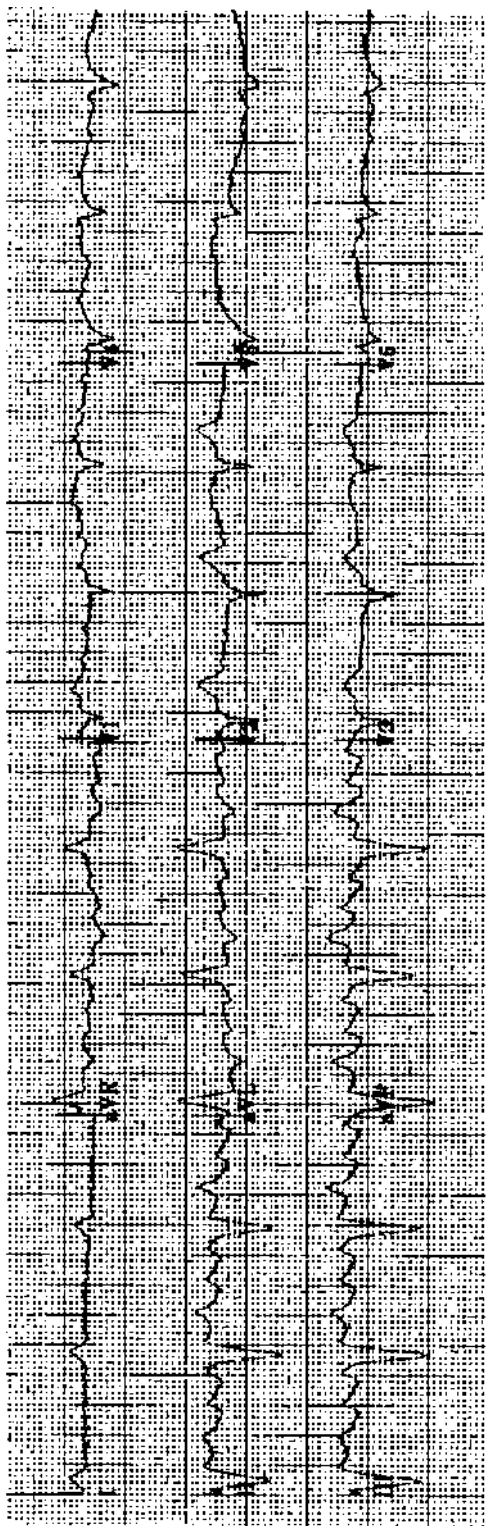
Practice ECG 20 A 76-year-old man with history of MI and mild heart failure. Does this ECG tell you anything about the patient's coronary anatomy?



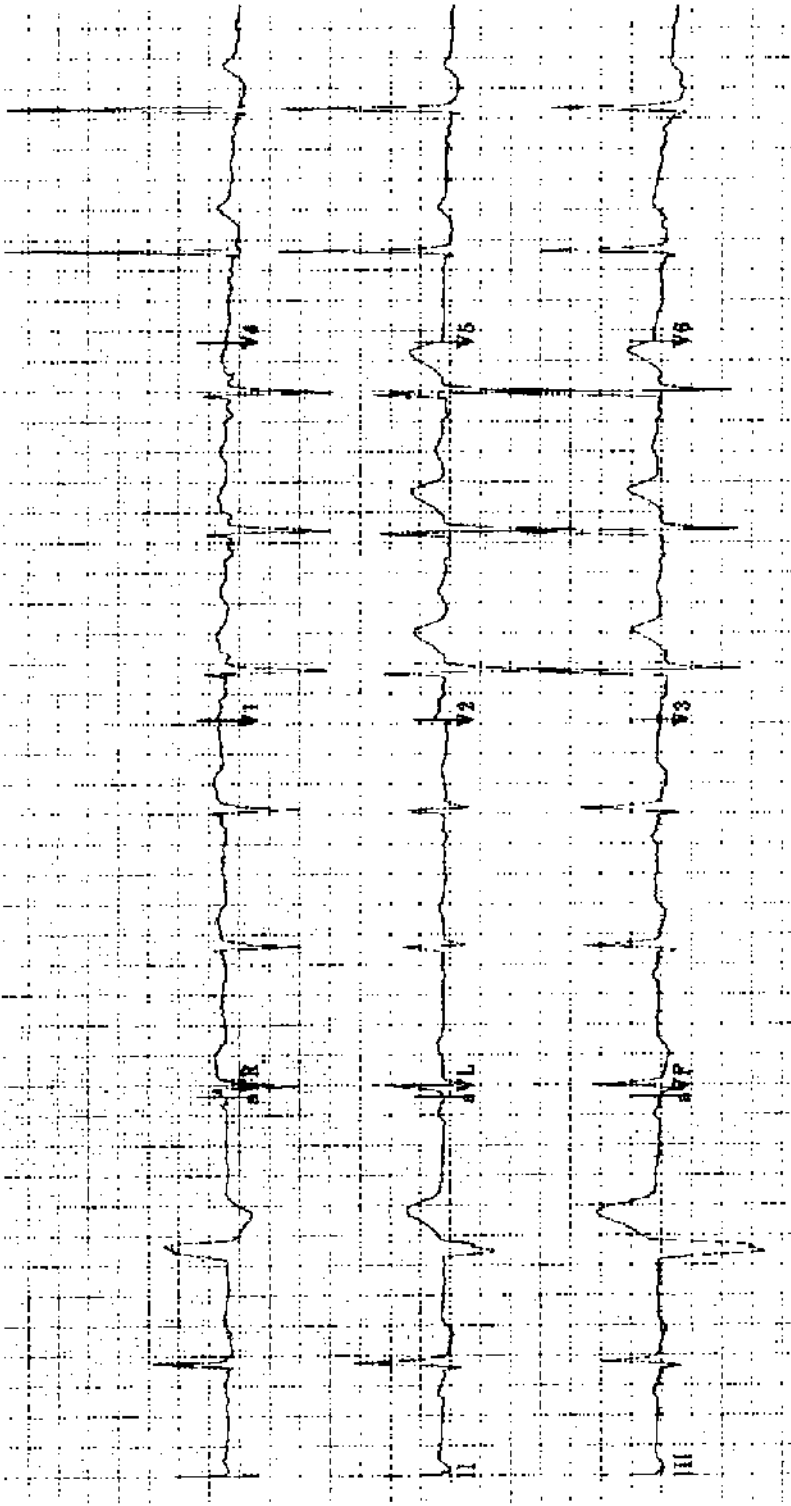
Practice ECG 21 A 59-year-old woman with peripheral edema, jugular venous distension, and a loud systolic murmur that intensifies with inspiration.



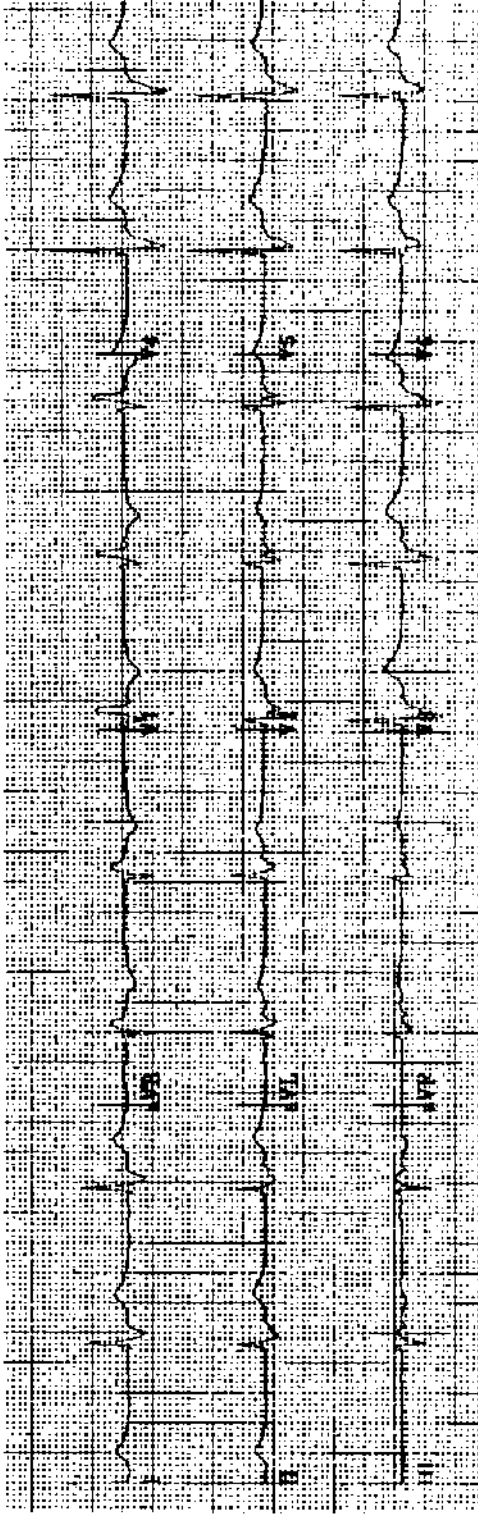
Practice ECG 22 A 56-year-old woman admitted through the emergency room. Any guess about the nature of her acute illness?



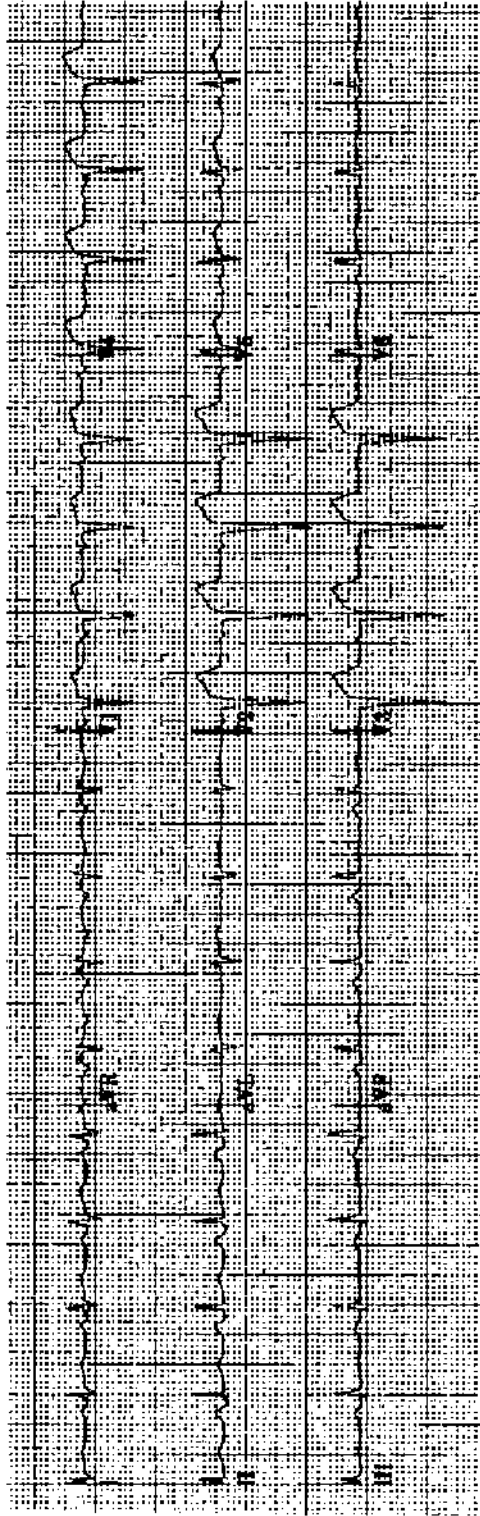
Practice ECG 23 A 70-year-old man with a remote history of fainting spells. Now in the emergency room with dyspnea and fever.



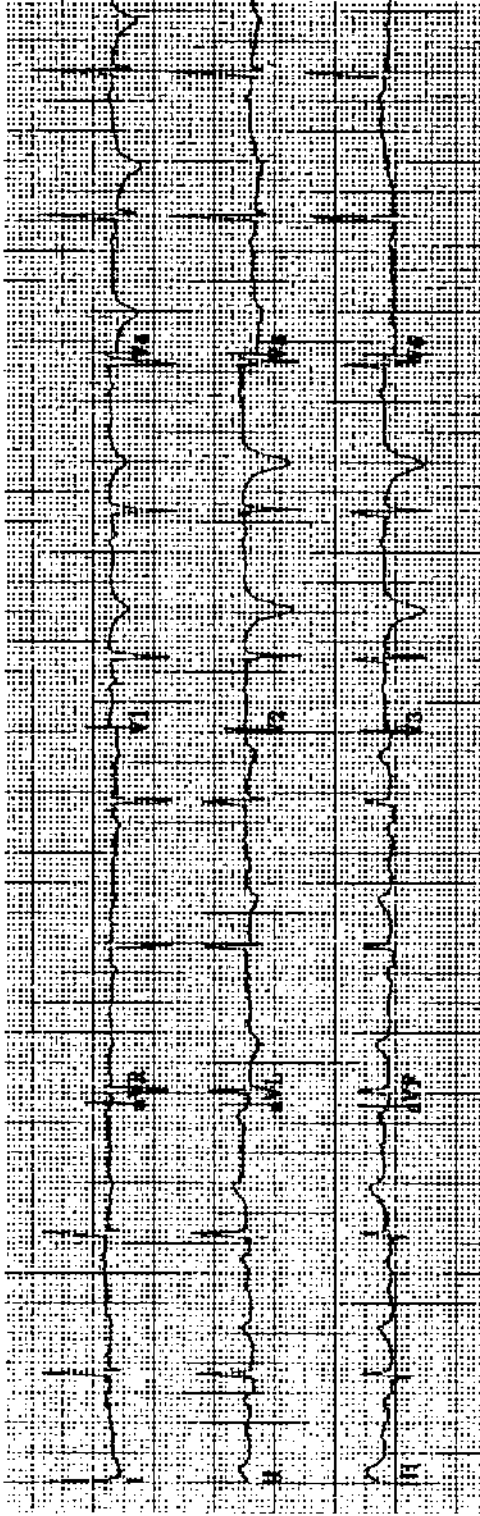
Practice ECG 24 A 75-year-old man with a systolic murmur and heart failure. What is the dominant valvular lesion?



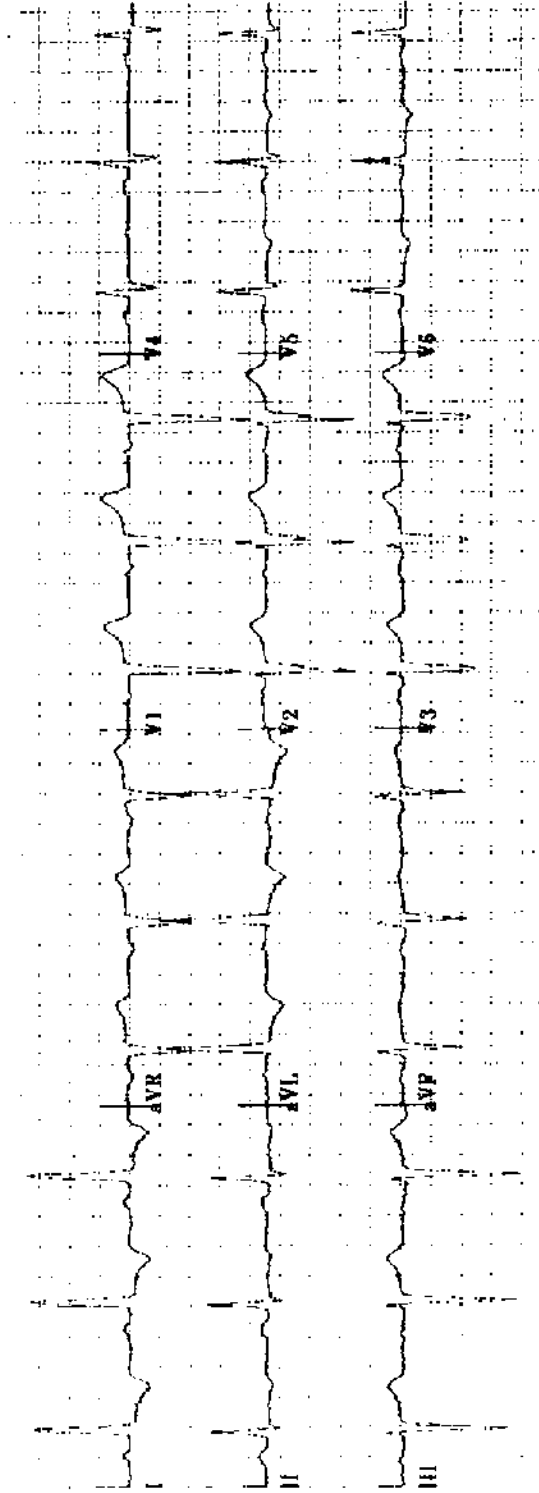
Practice ECG 25 An 80-year-old man treated with diuretics and digoxin. What lab work is needed?



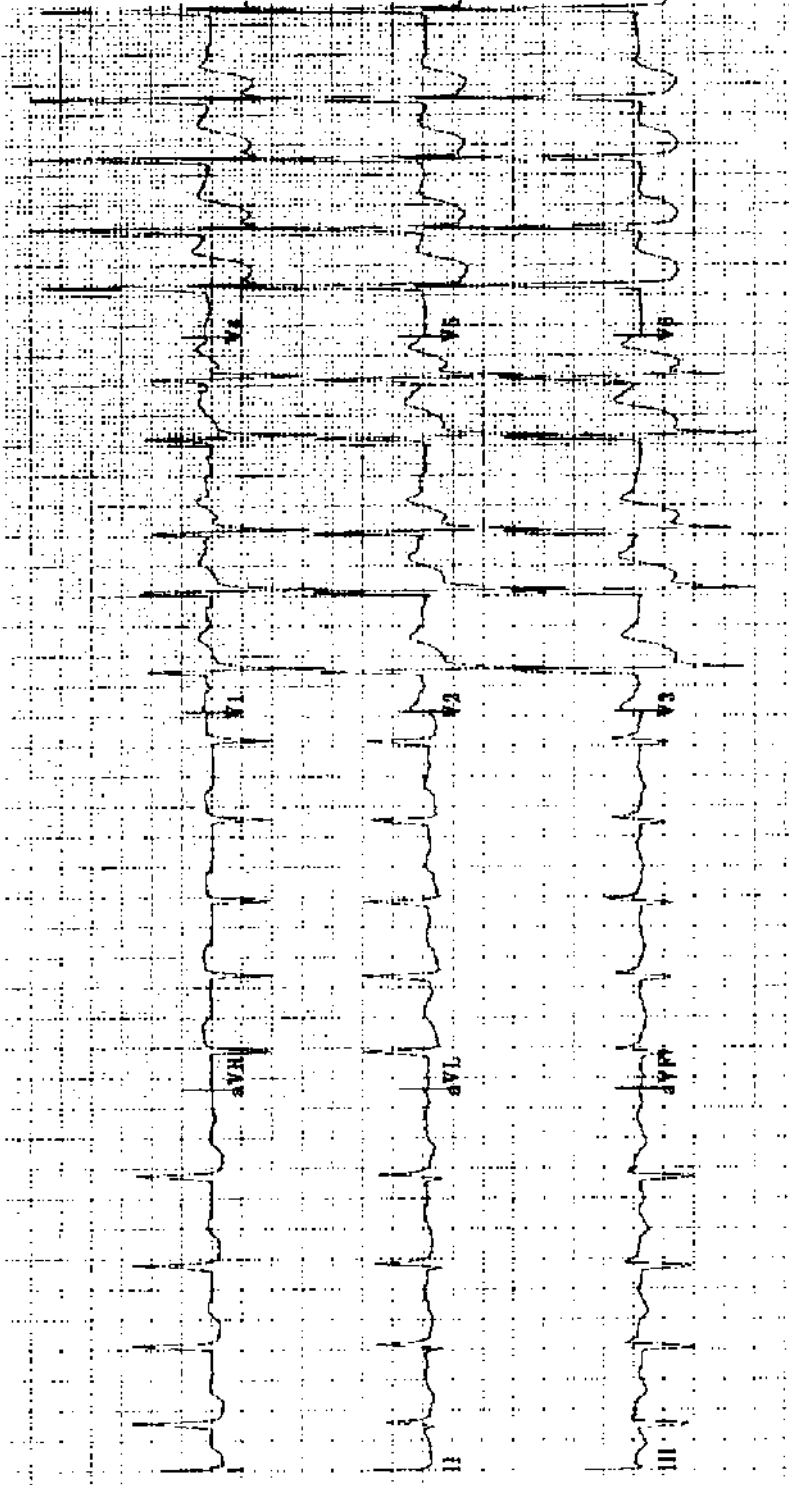
Practice ECG 26 A 52-year-old man who had a 20-hour siege of indigestion a month earlier. He has severe fatigue. The cardiologist has ordered an echocardiogram. Why?



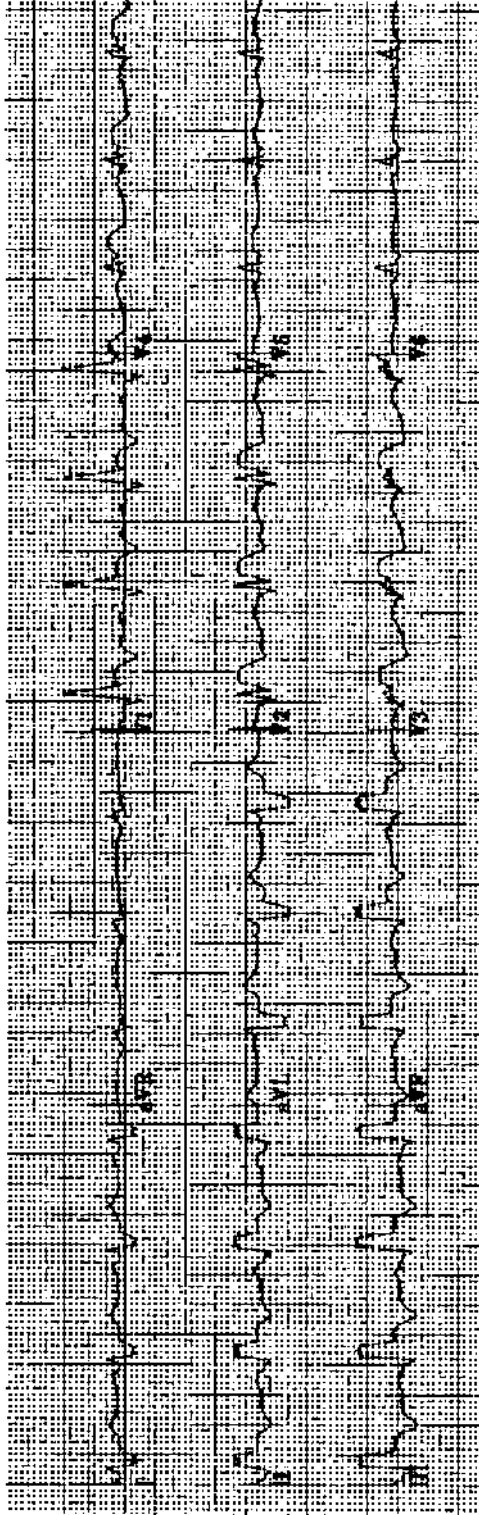
Practice ECG 27 A 71-year-old woman in the emergency room. A long episode of chest pain was relieved before her arrival by nitroglycerine. Is angiography indicated? What would it show?



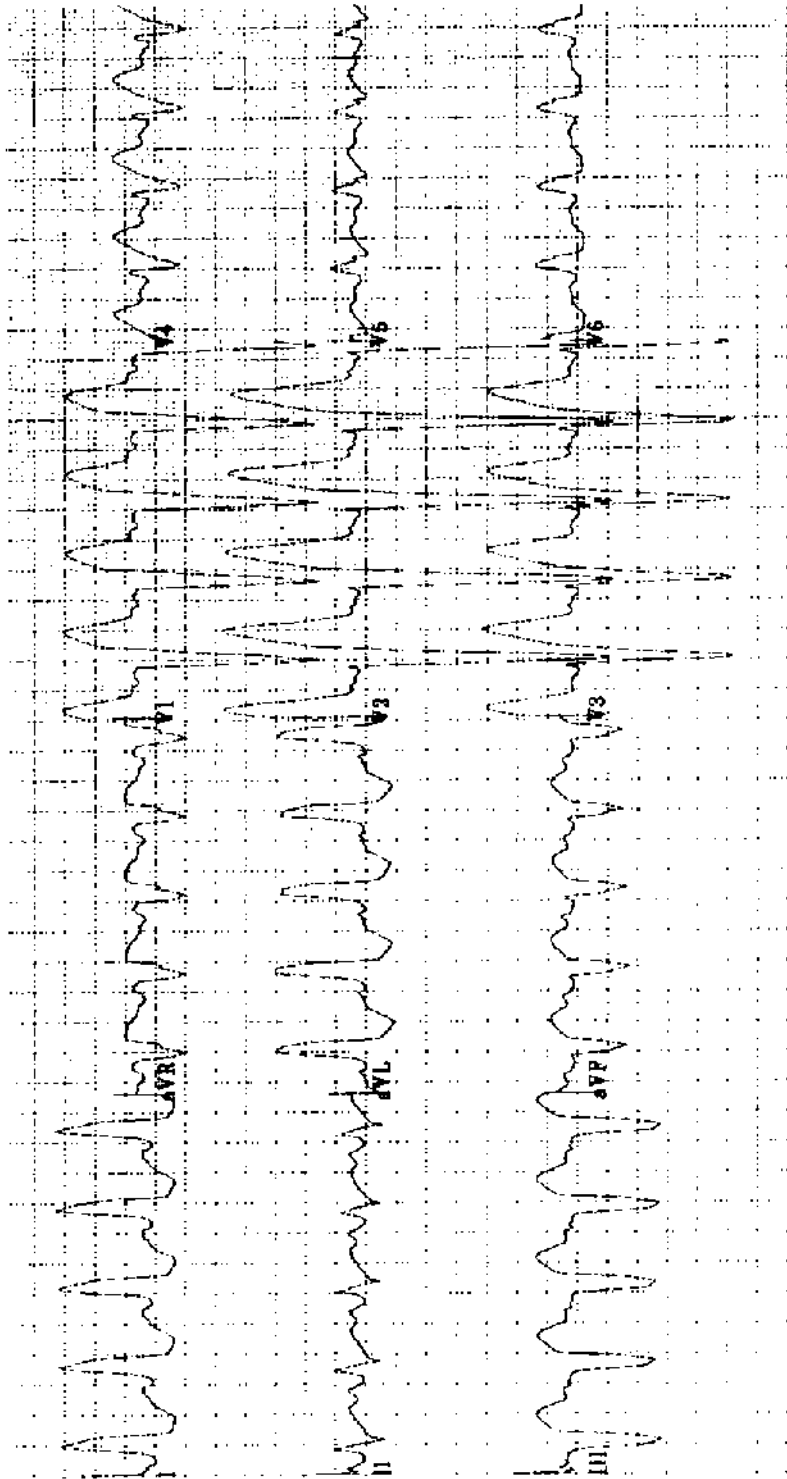
Practice ECG 28 A 79-year-old woman with mild hypertension.



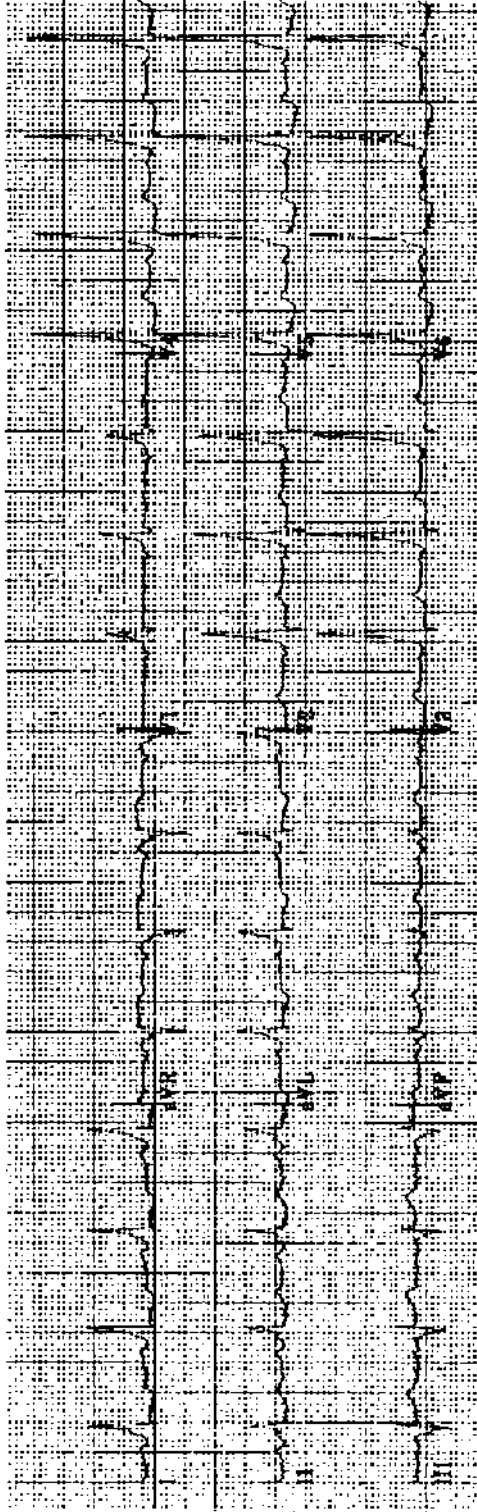
Practice ECG 29 A 74-year-old woman with a history of atrial fibrillation, diabetes, hypertension, obesity, and MI. Now in the emergency room with pulmonary edema.



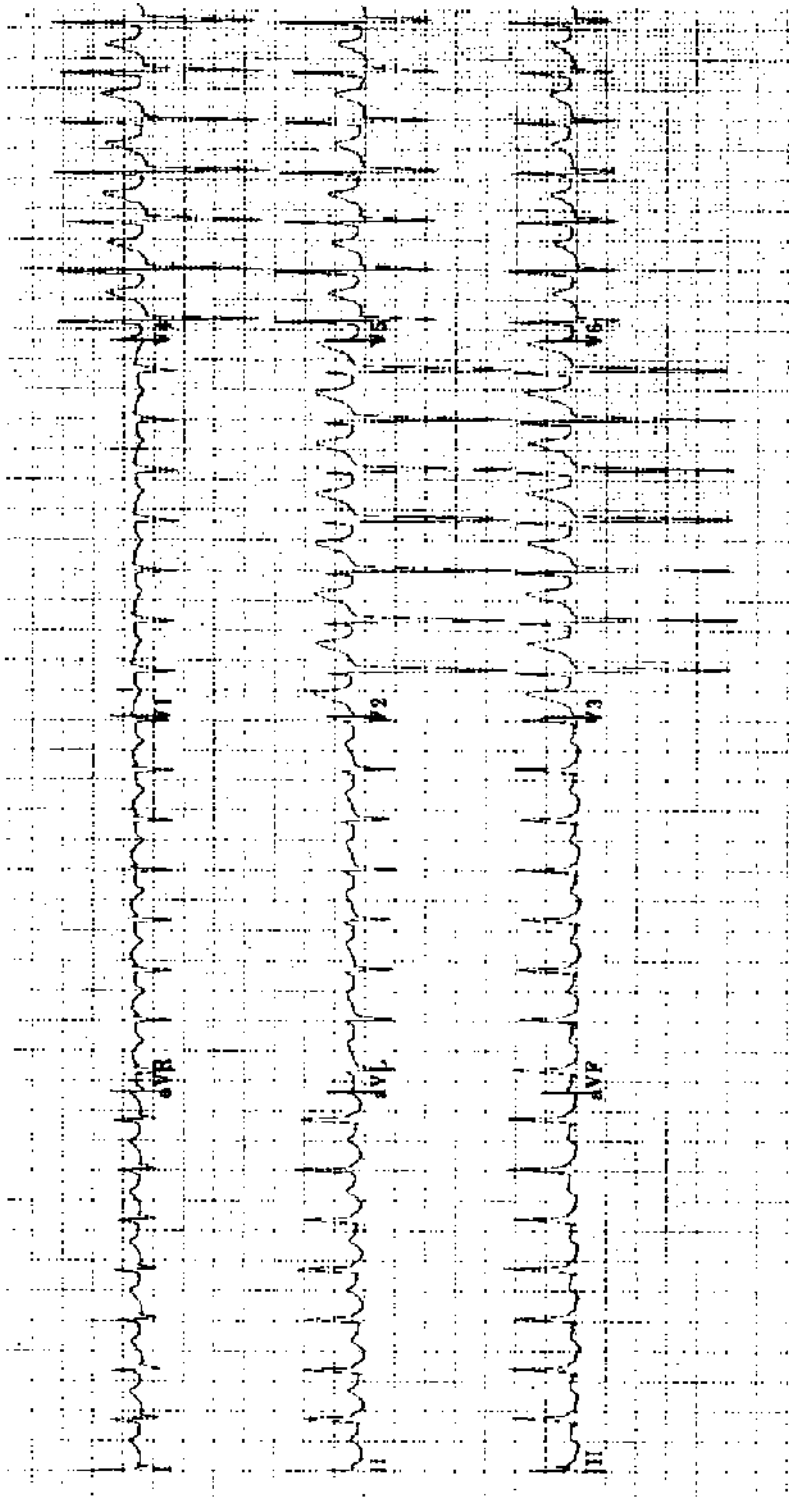
Practice ECG 30 An 85-year-old man with chest pain. There is a history of MI. What is his prognosis?



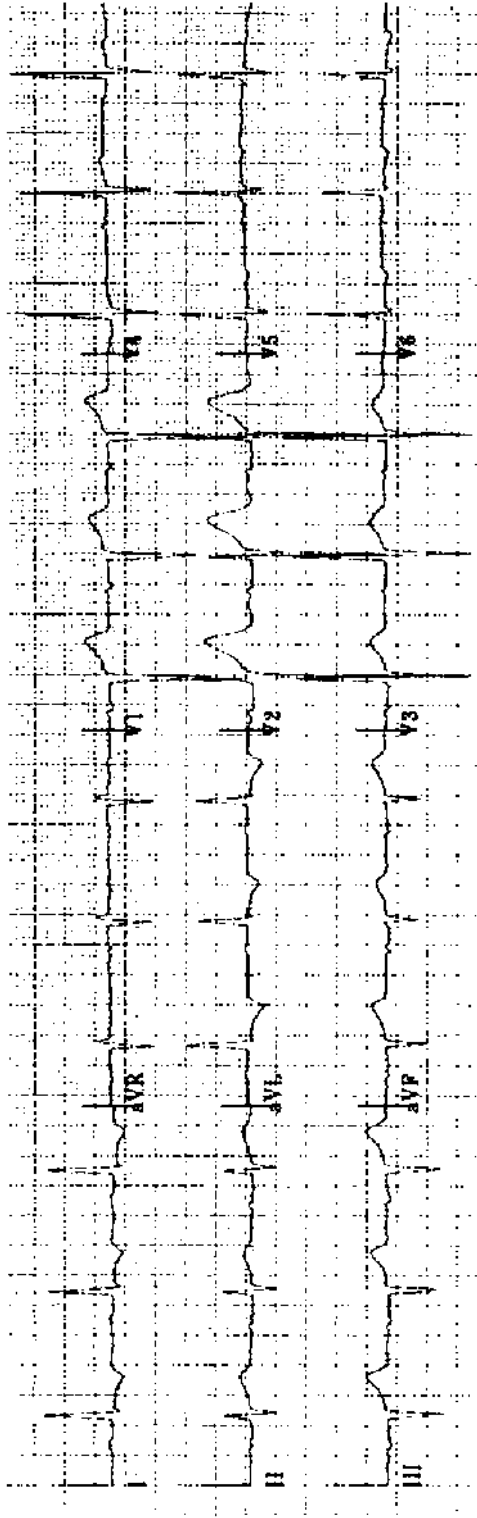
Practice ECG 31 A 61-year-old woman with poorly controlled hypertension.



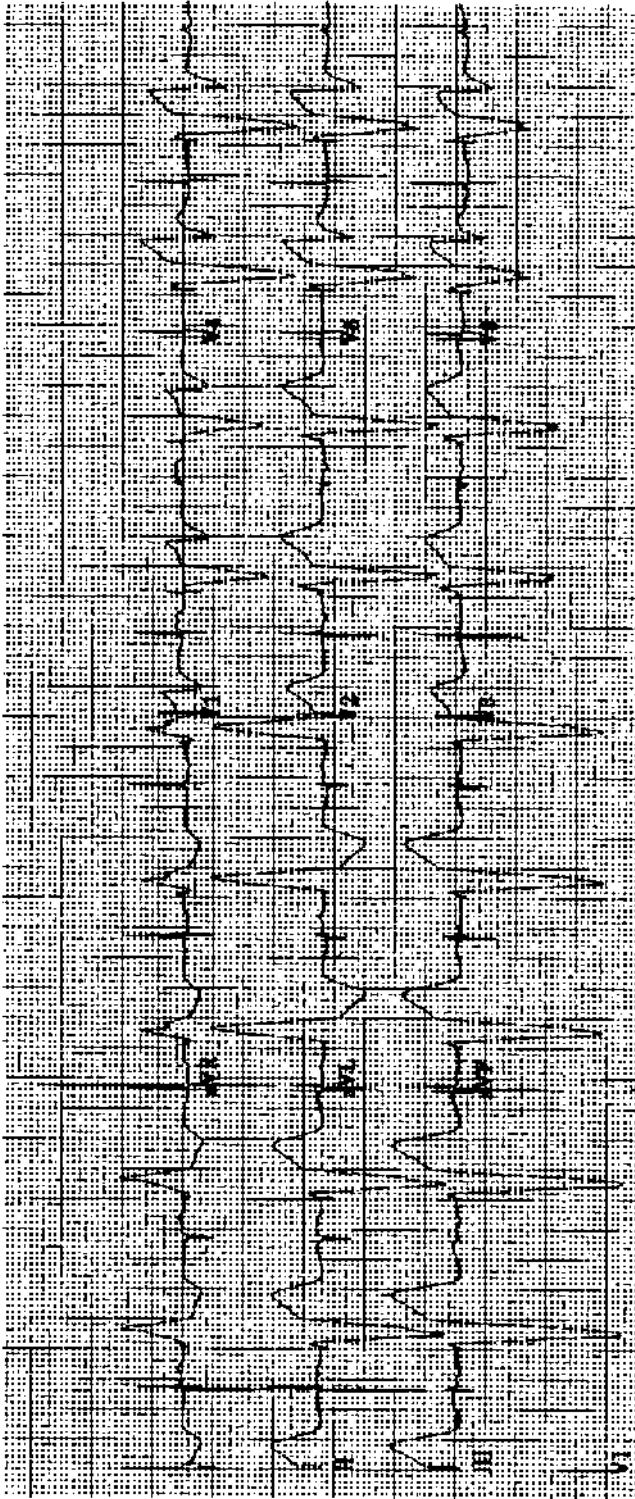
Practice ECG 32 A 42-year-old man with intermittent palpitations since childhood. His doctor is concerned about his conduction abnormality and a silent heart attack.



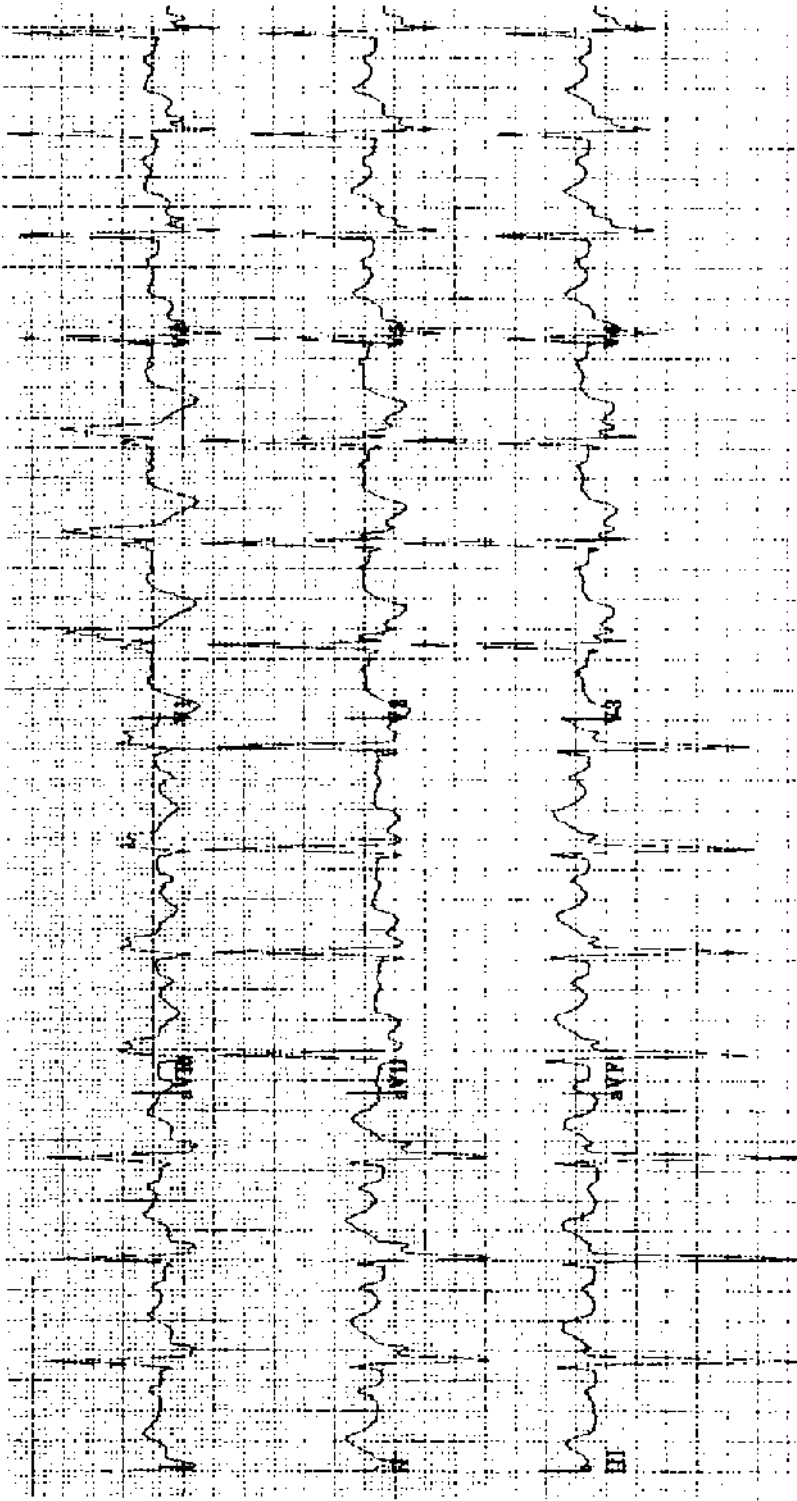
Practice ECG 33 A 38-year-old woman with palpitations and dizziness.



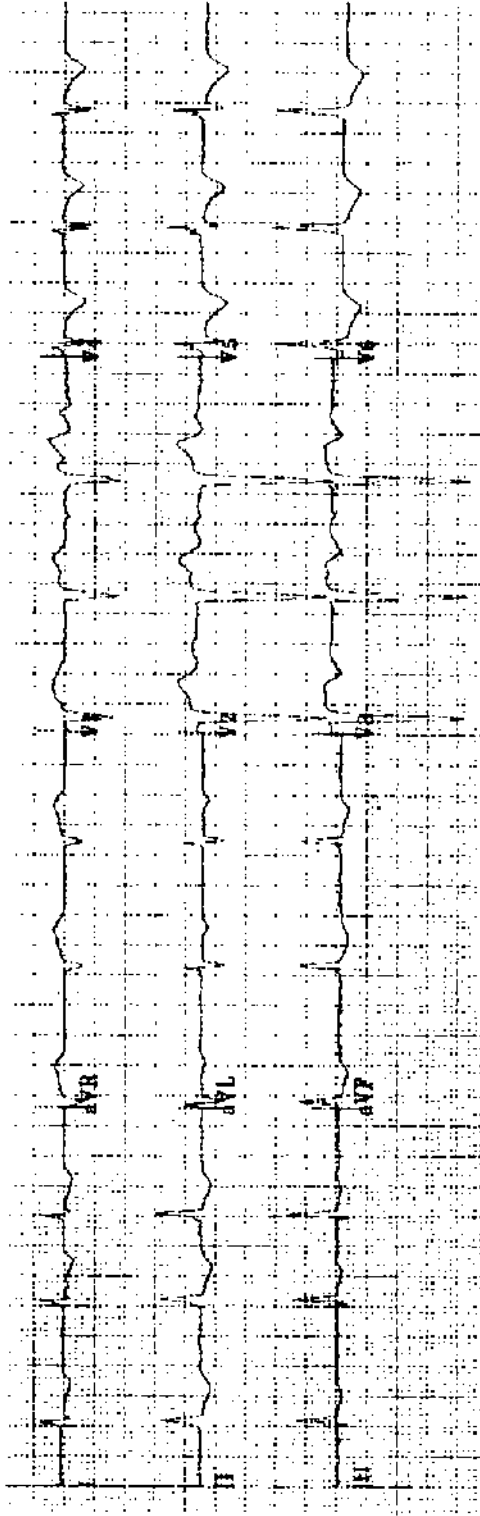
Practice ECG 34 An 81-year-old woman in the emergency room with chest pain. What are the treating physician's next steps? Would you consider thrombolytic therapy?



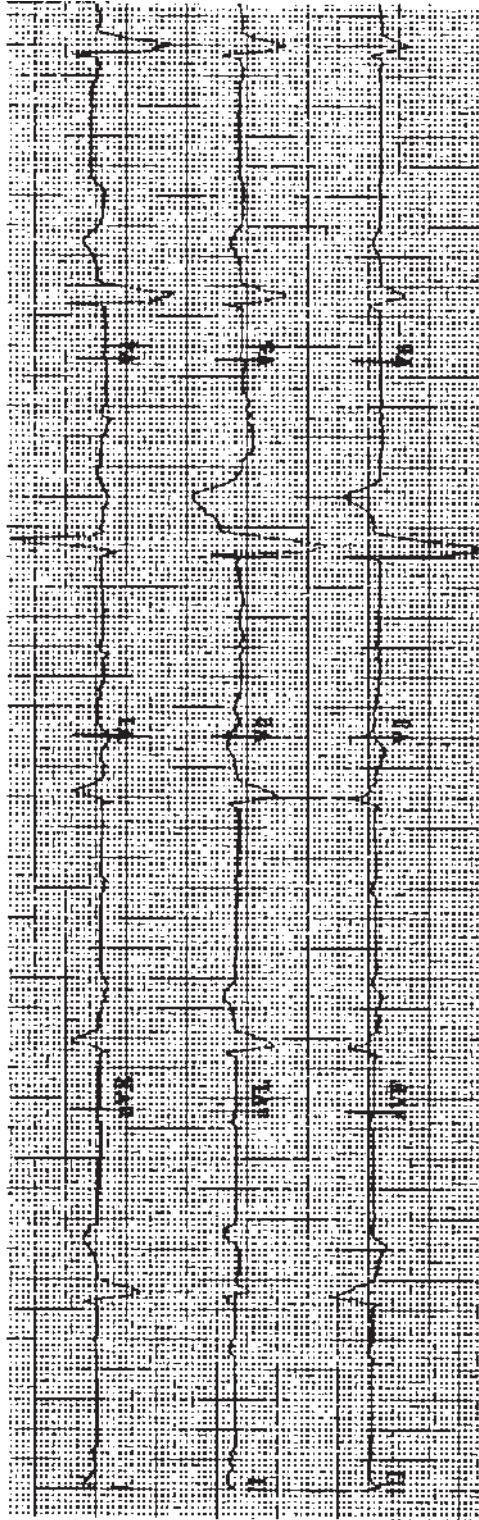
Practice ECG 35 A 73-year-old man; no history provided.



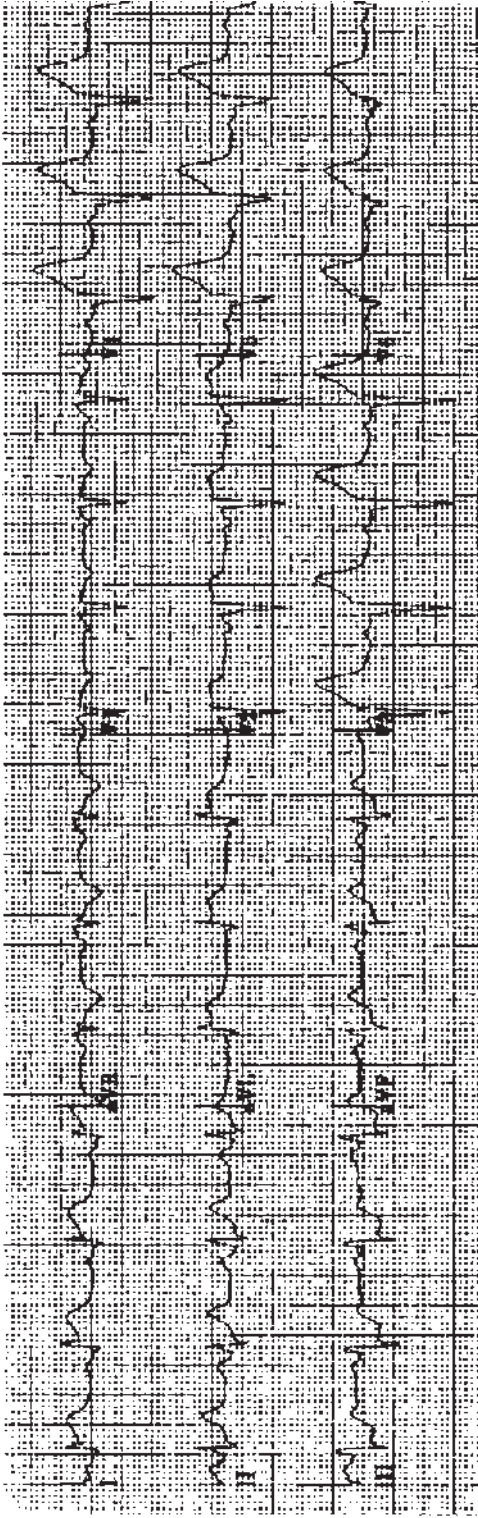
Practice ECG 36 A 65-year-old woman with a long history of borderline hypertension. What does this ECG tell you about control of her blood pressure?



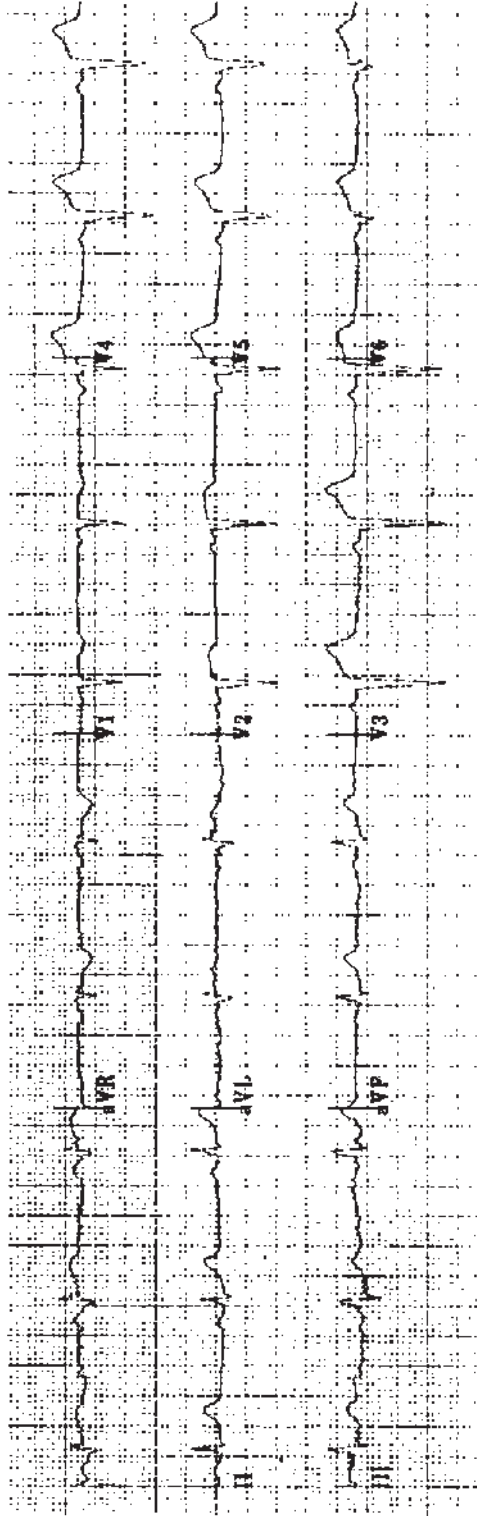
Practice ECG 37 An 86-year-old woman, annual ECG.



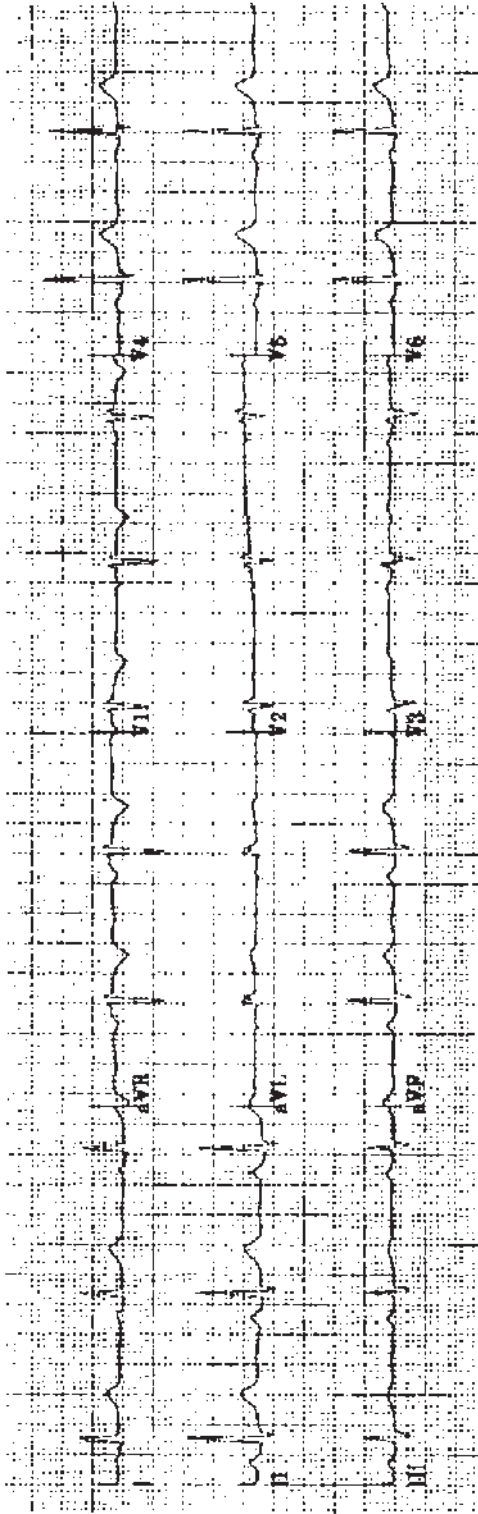
Practice ECG 38 An 82-year-old man with fatigue and ankle edema for 2 weeks.



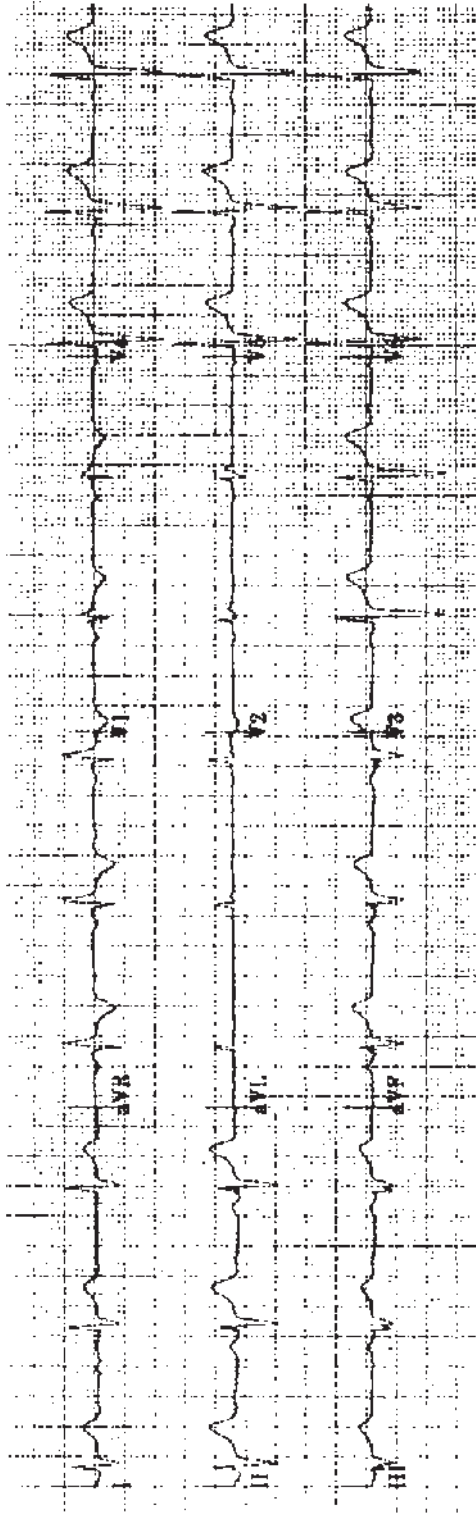
Practice ECG 39 A 62-year-old man in the emergency room of a community hospital. Before arrival, he had chest pain for 2 hours, then relief. Pain has now recurred. Is it too late for reperfusion therapy?



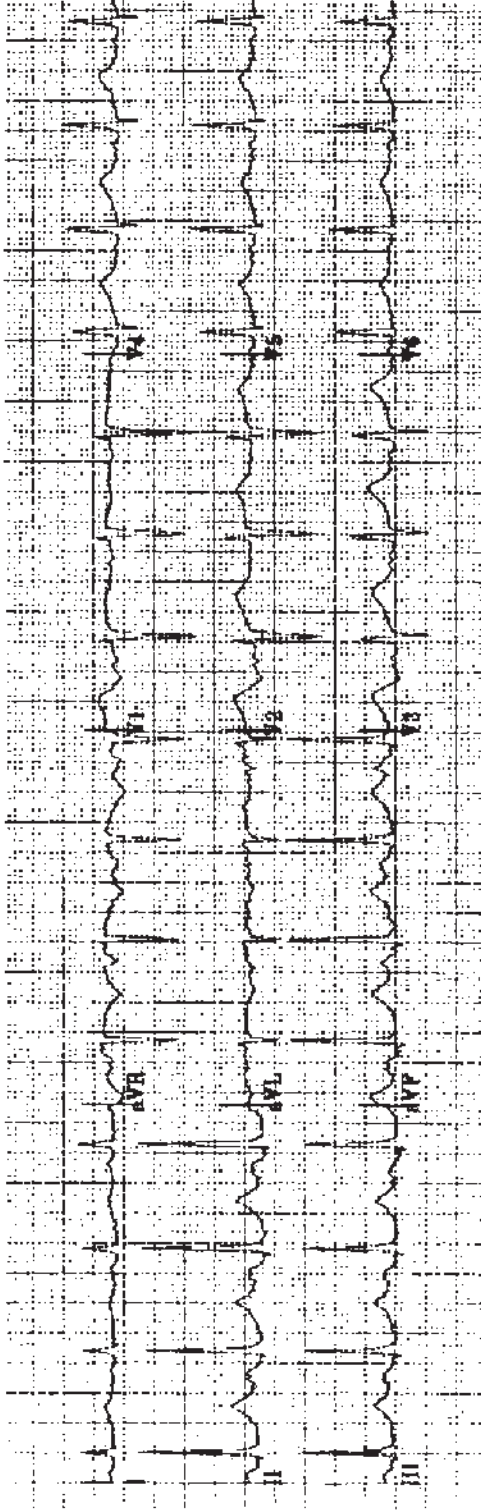
Practice ECG 40 Same patient (No. 39), 2 hours after treatment with tissue plasminogen activator.



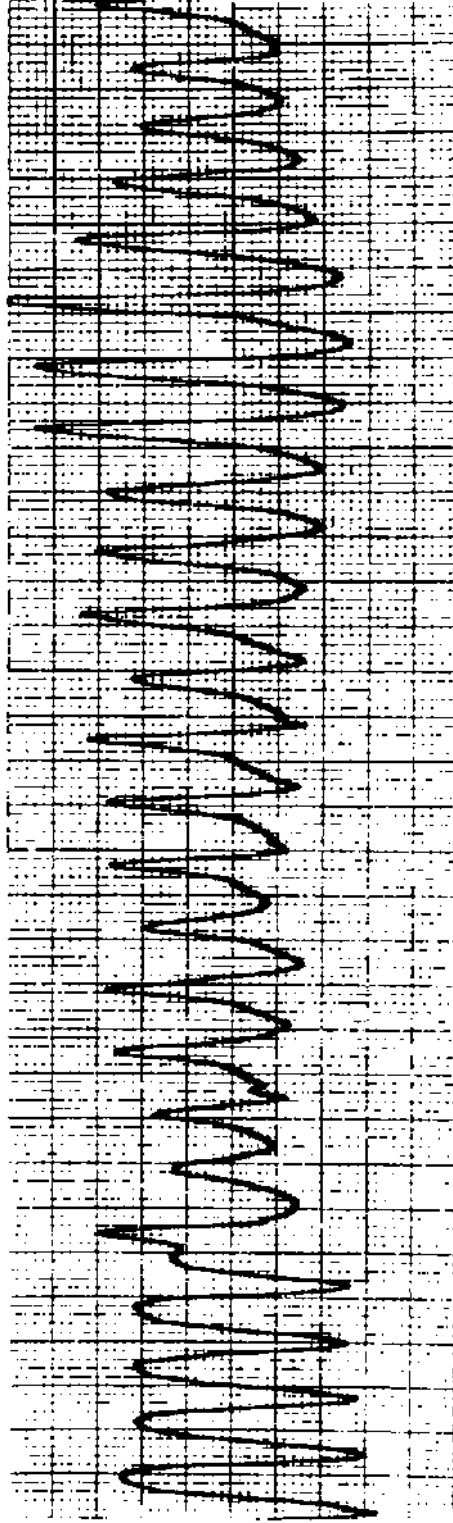
Practice ECG 41 A 26-year-old with no symptoms. Which diagnostic test is needed?



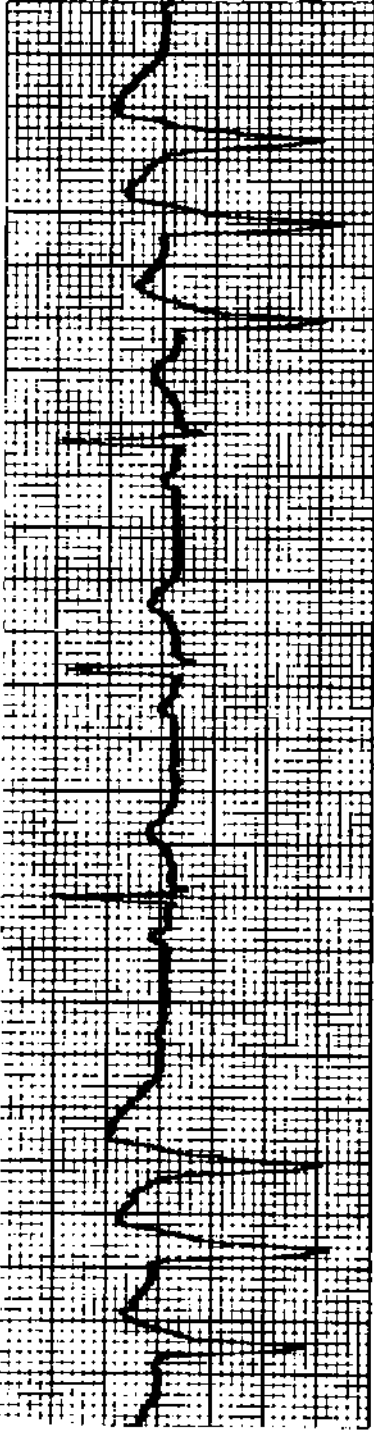
Practice ECG 42 A 32-year-old man with fixed splitting of the second heart sound and a loud murmur. What is the illness?



Practice ECG 43 A 40-year-old man in the emergency room following an episode of syncope. He has been treated with erythromycin and antihistamines for a respiratory illness.



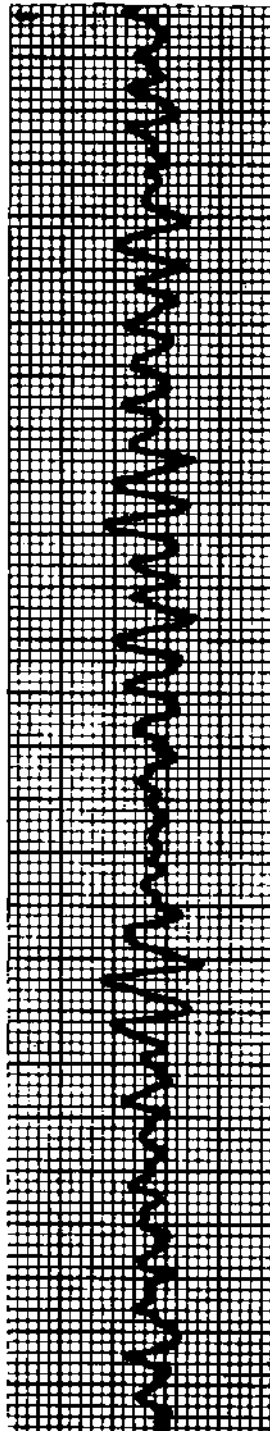
Practice ECG 44 Telemetry recording the same patient (No. 43) 4 hours later. During the arrhythmia, he lost consciousness.



A.

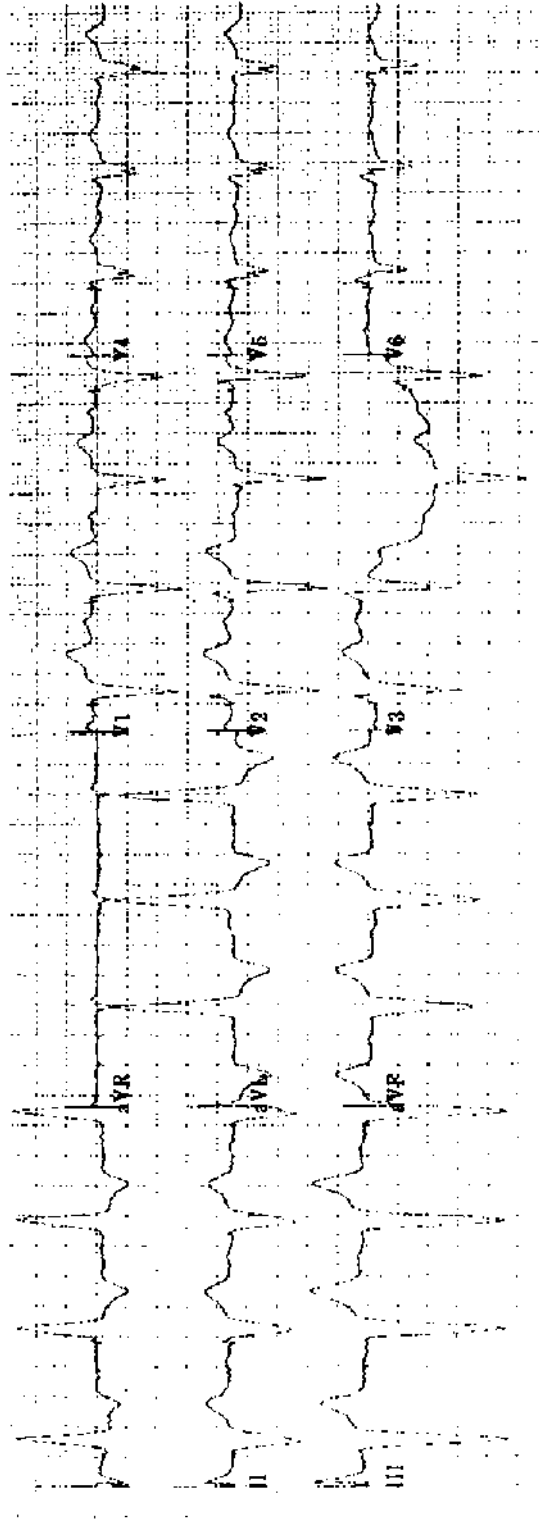


B.

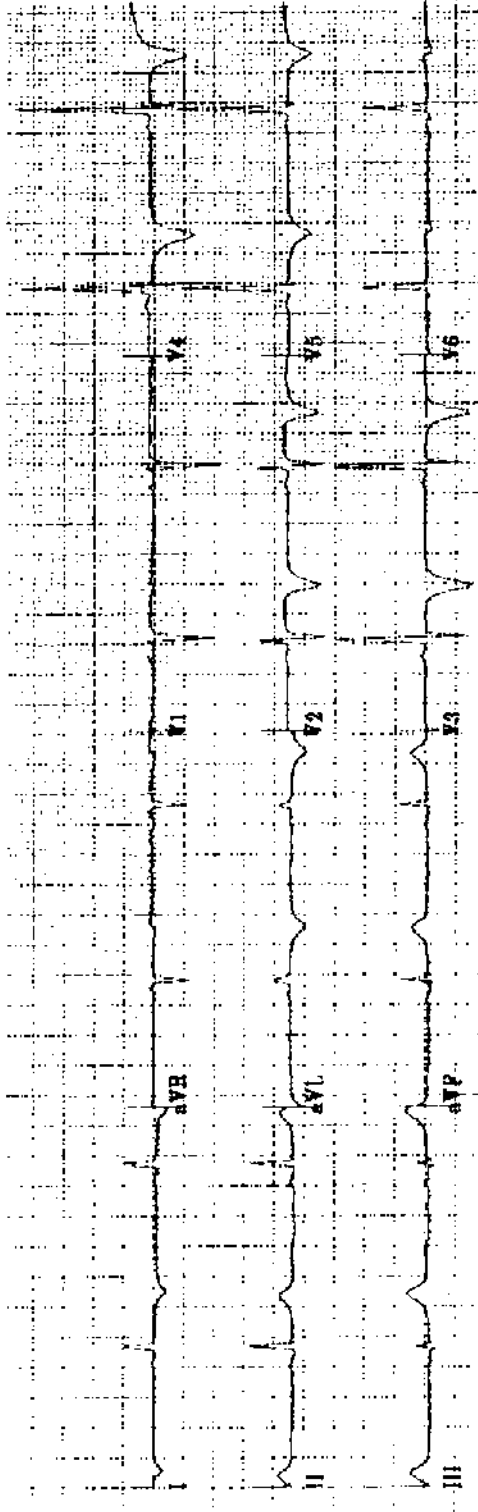


C.

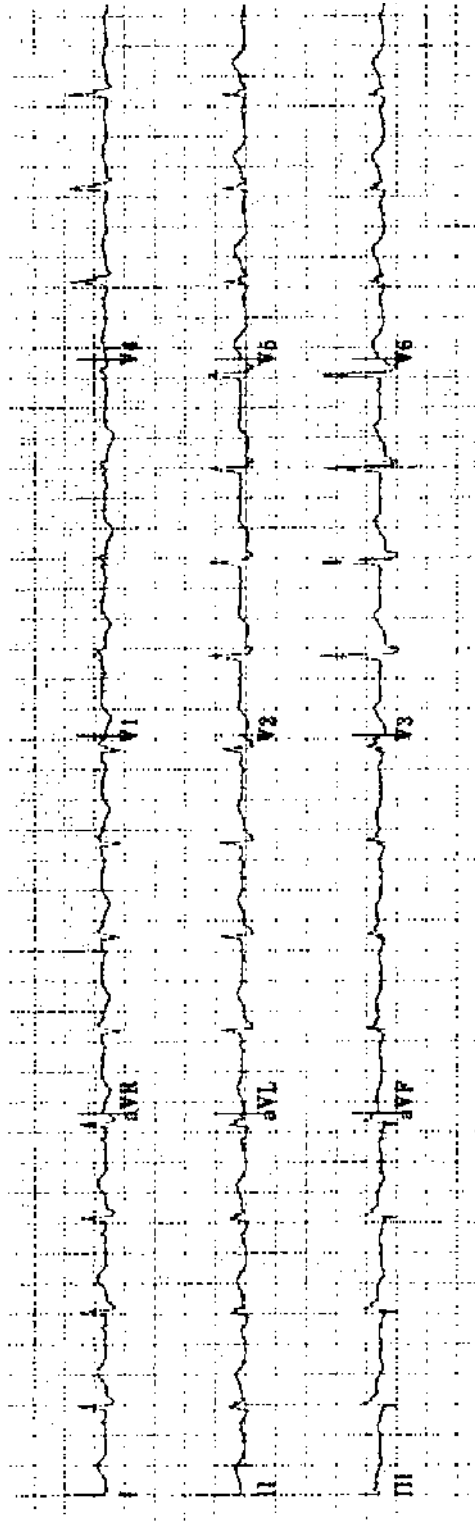
Practice ECG 45 Rhythm strips from a 52-year-old woman with cardiomyopathy and episodic dizziness. During the third tracing, she lost consciousness.



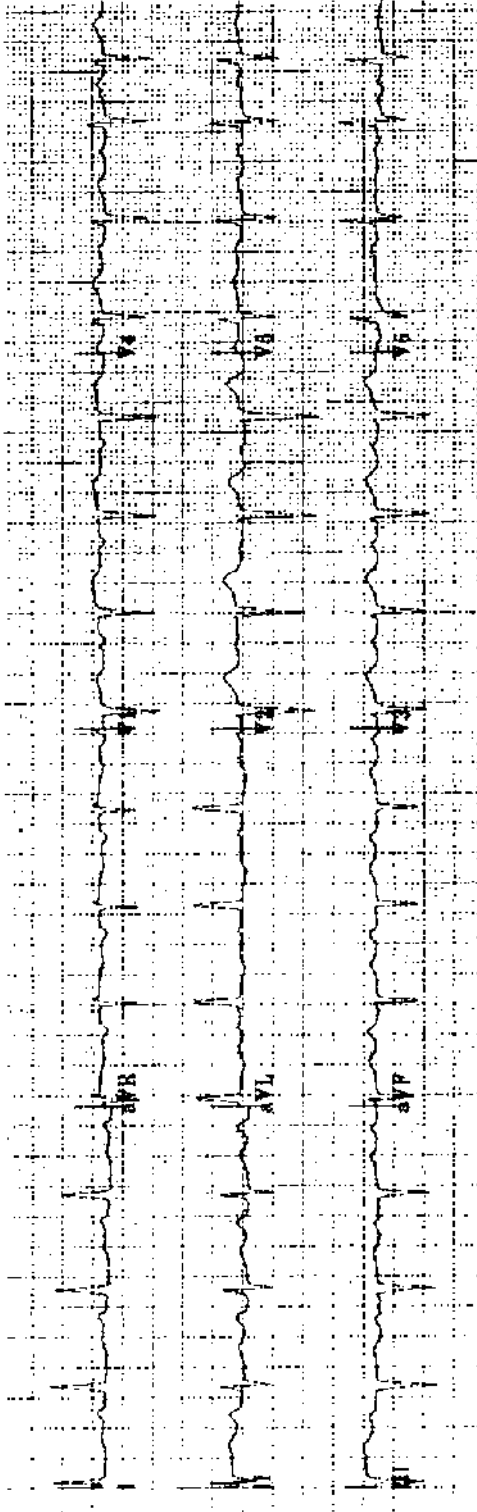
Practice ECG 46 An 87-year-old woman with a history of dizzy spells.



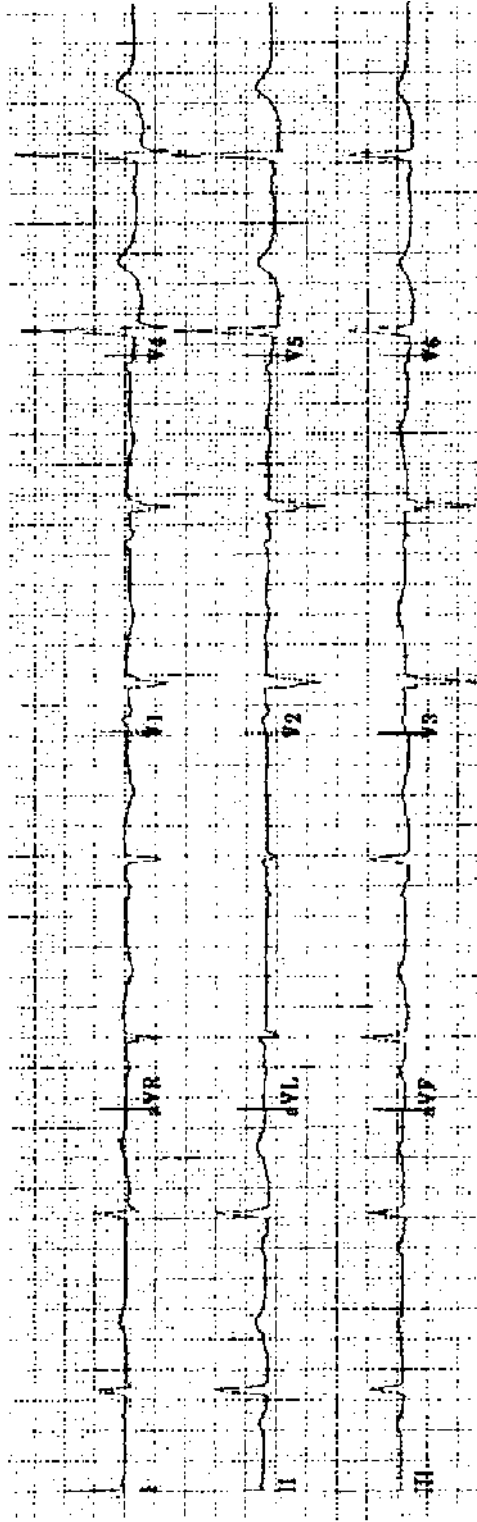
Practice ECG 47 A 45-year-old man after a 45-minute episode of chest pain.




Practice ECG 48 A 68-year-old woman after indigestion of 9 hours duration. What treatment is indicated?



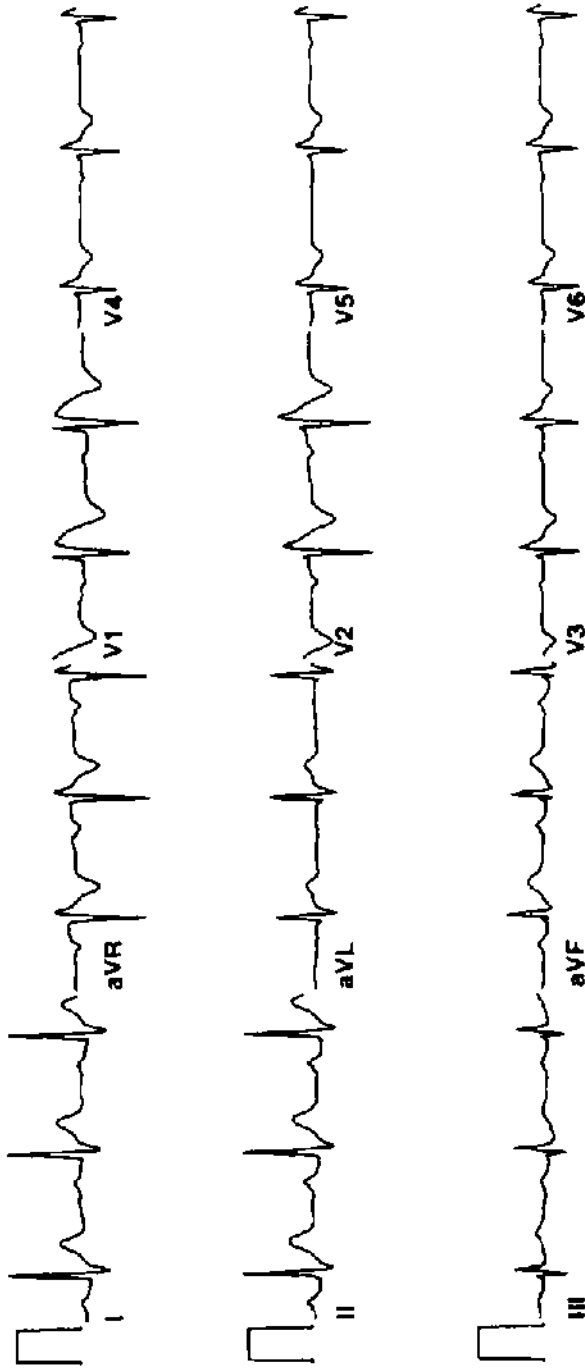
Practice ECG 49 A 76-year-old woman with diabetes; yearly examination.



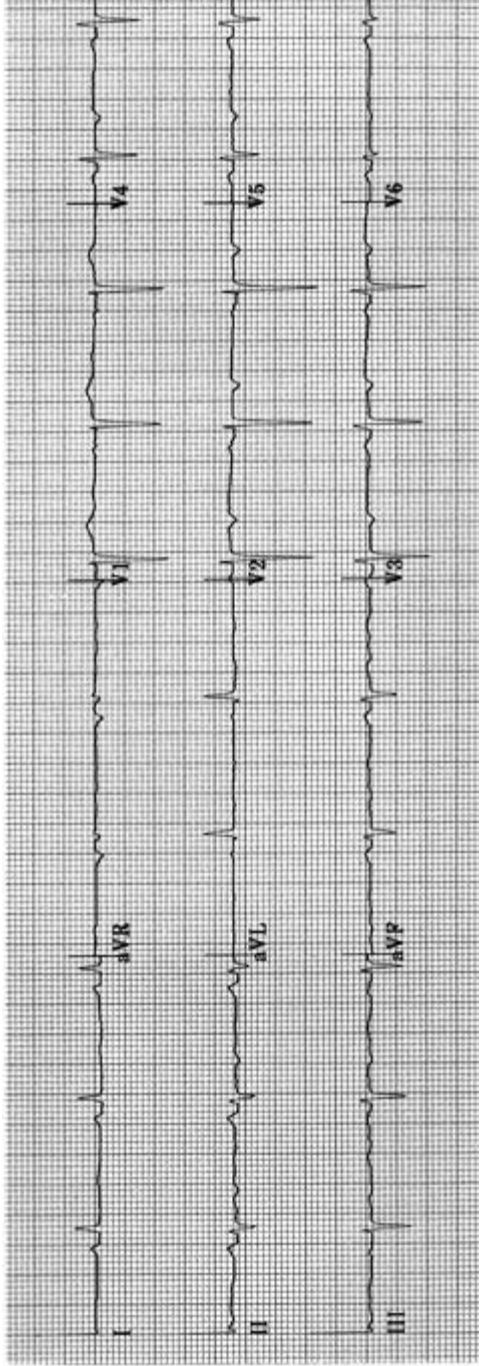
Practice ECG 50 A 75-year-old man who takes heart pills.



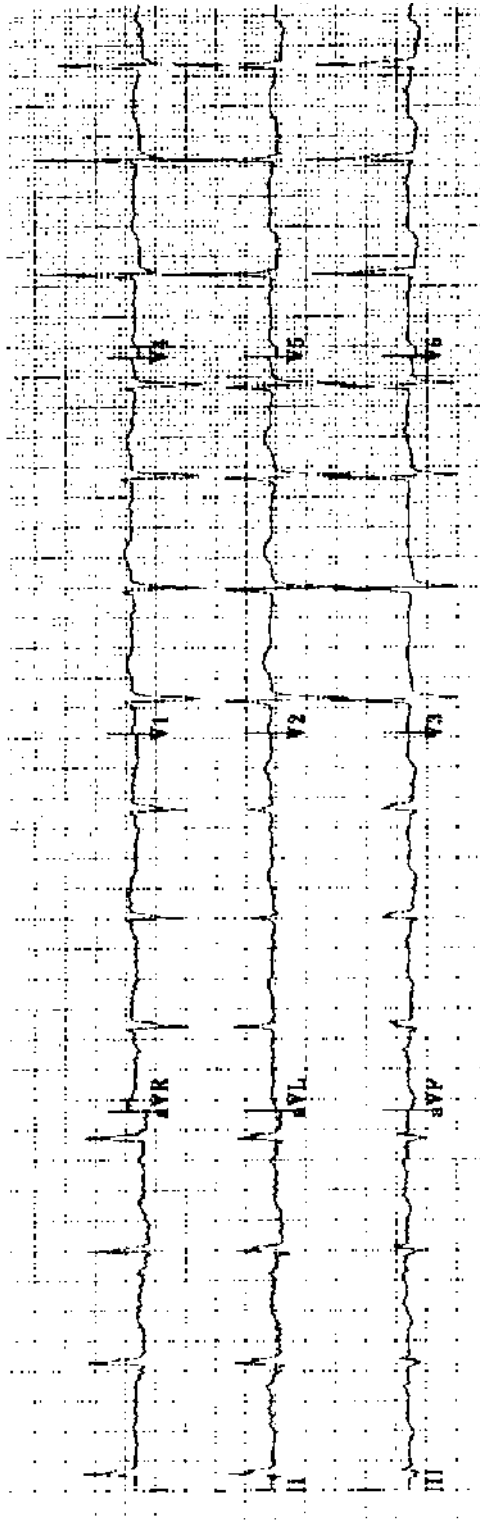
Practice ECG 51 An 82-year-old woman with mild heart failure.



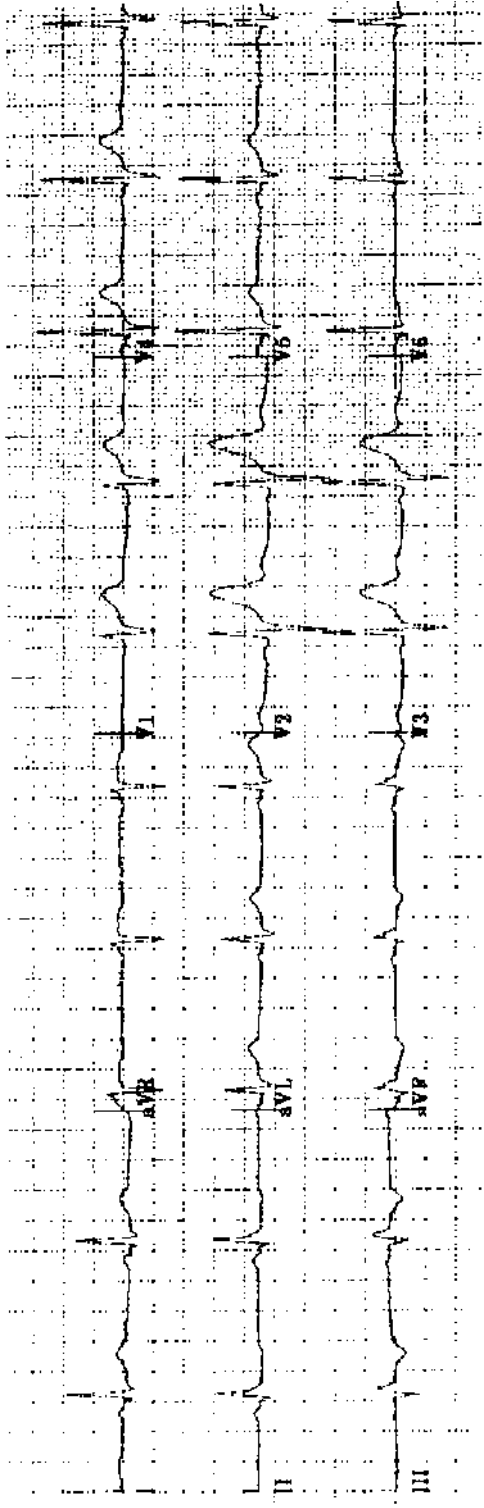
Practice ECG 52 A 40-year-old man with syncope.




Practice ECG 53 A 69-year-old man with a history of heart failure.



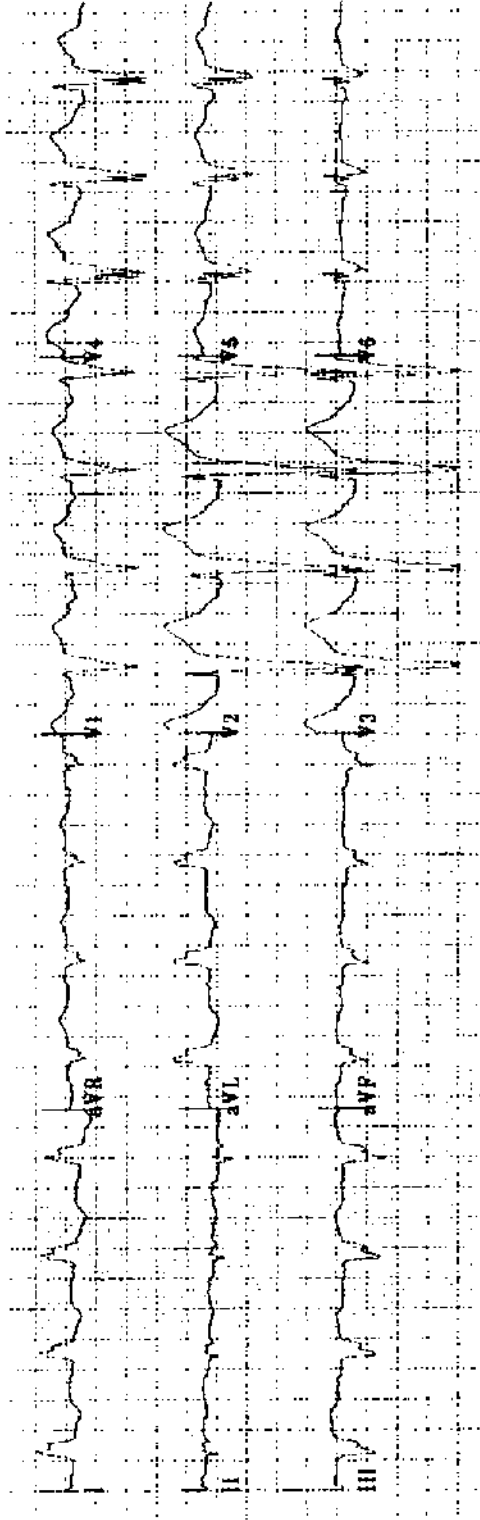
Practice ECG 54 A 70-year-old woman with a remote history of MI and a history of atrial fibrillation.




Practice ECG 55 A 60-year-old man; no clinical data provided.



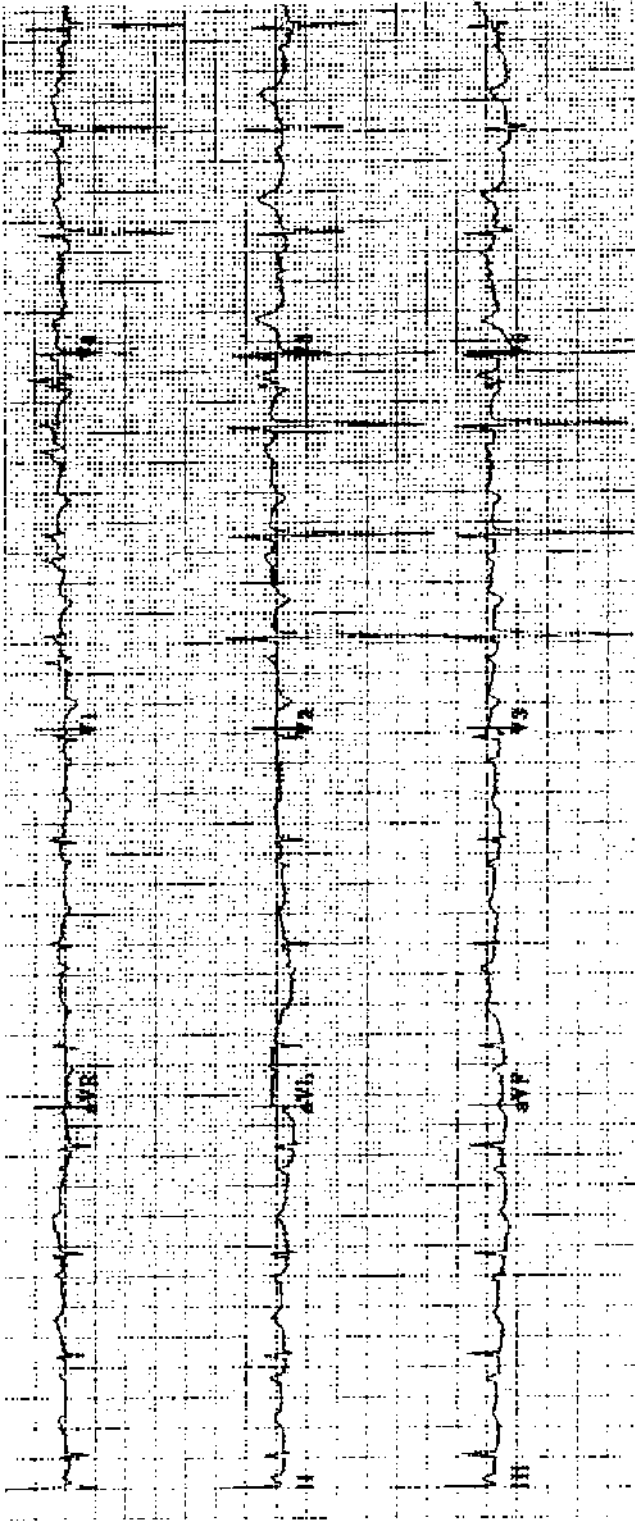
Practice ECG 56 An 81-year-old woman in excellent health.



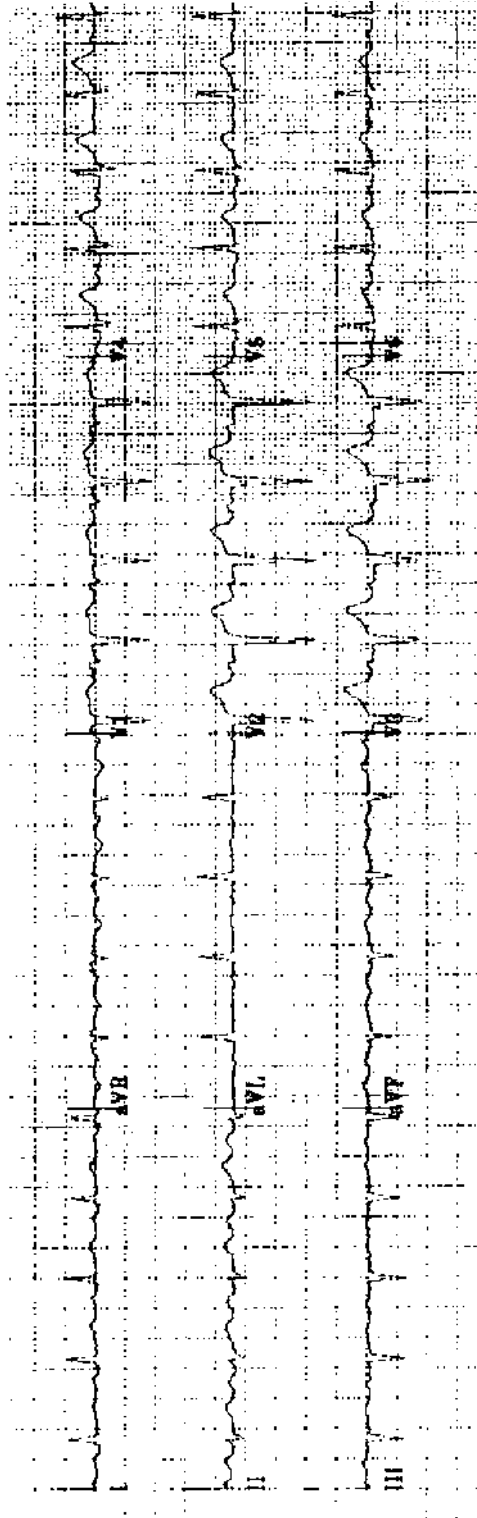
Practice ECG 57 A 72-year-old man with a history of arrhythmias.



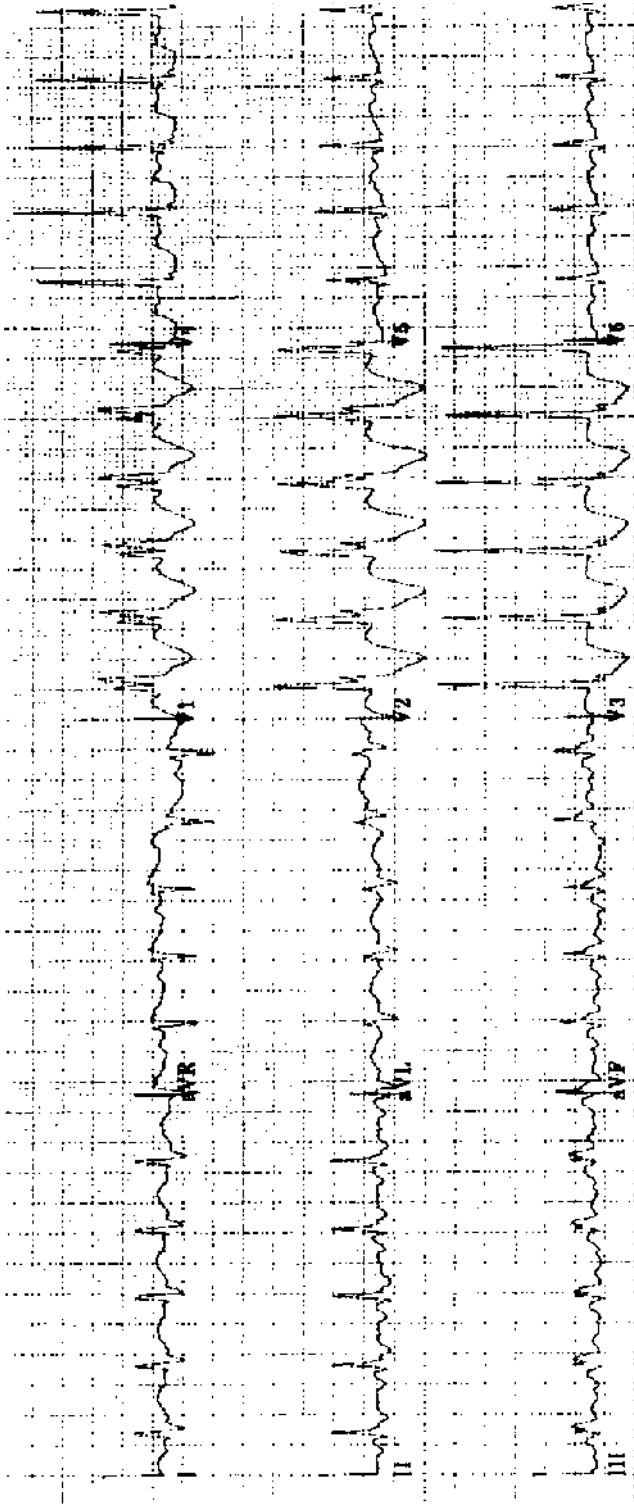
Practice ECG 58 A 31-year-old woman sent to a clinic because her ECG showed a heart attack. She had no history of MI. On exam there was a heart murmur.



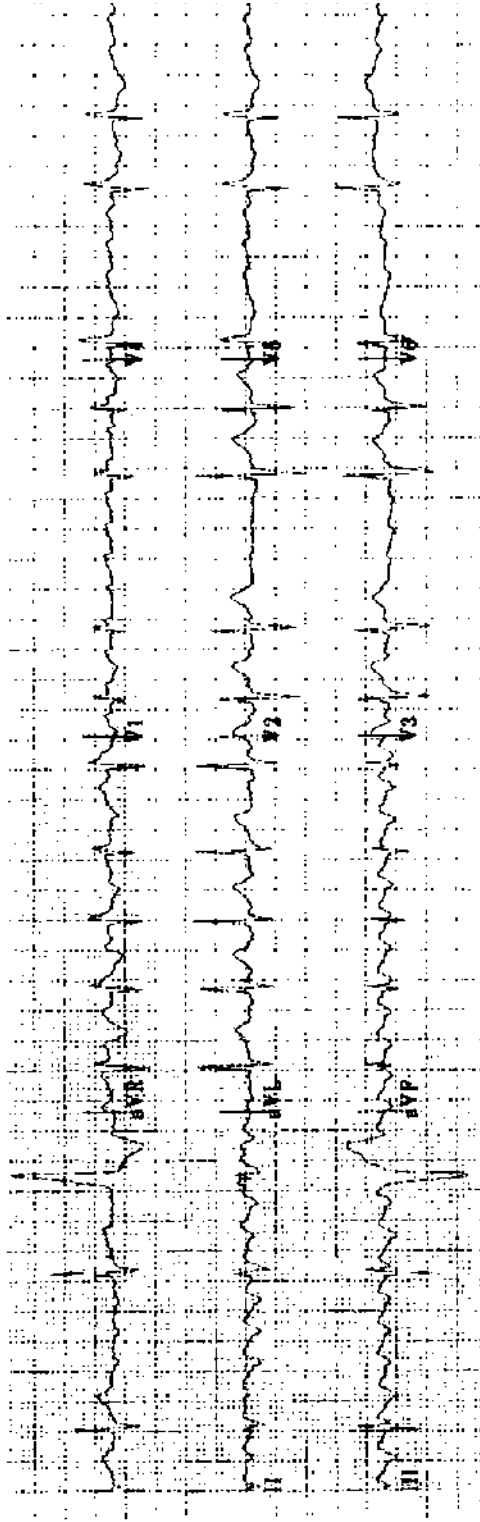
Practice ECG 59 A 64-year-old woman with emphysema and ankle edema.



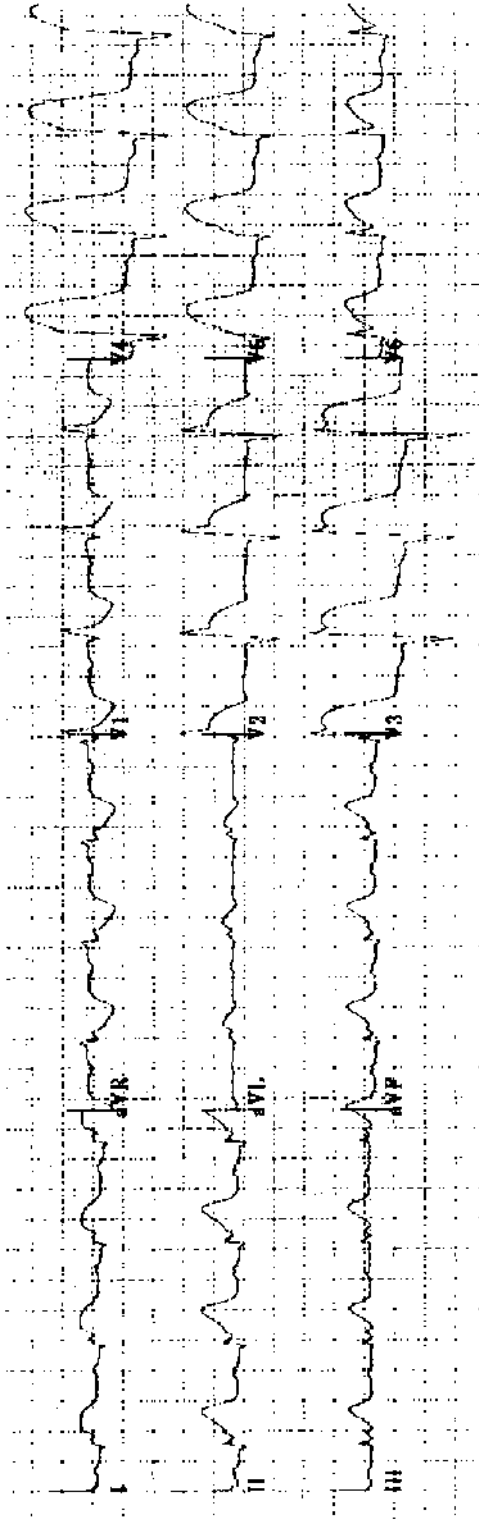
Practice ECG 60 A 69-year-old man with easy fatigue and exertional dyspnea.



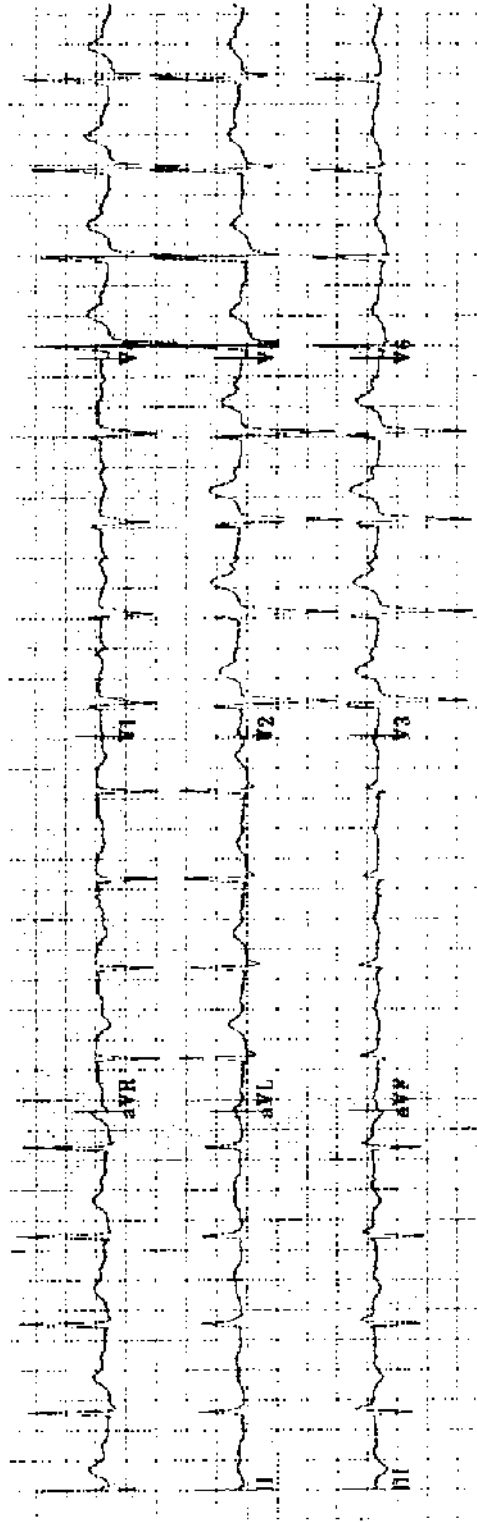
Practice ECG 61 A 75-year-old man with pulmonary edema.



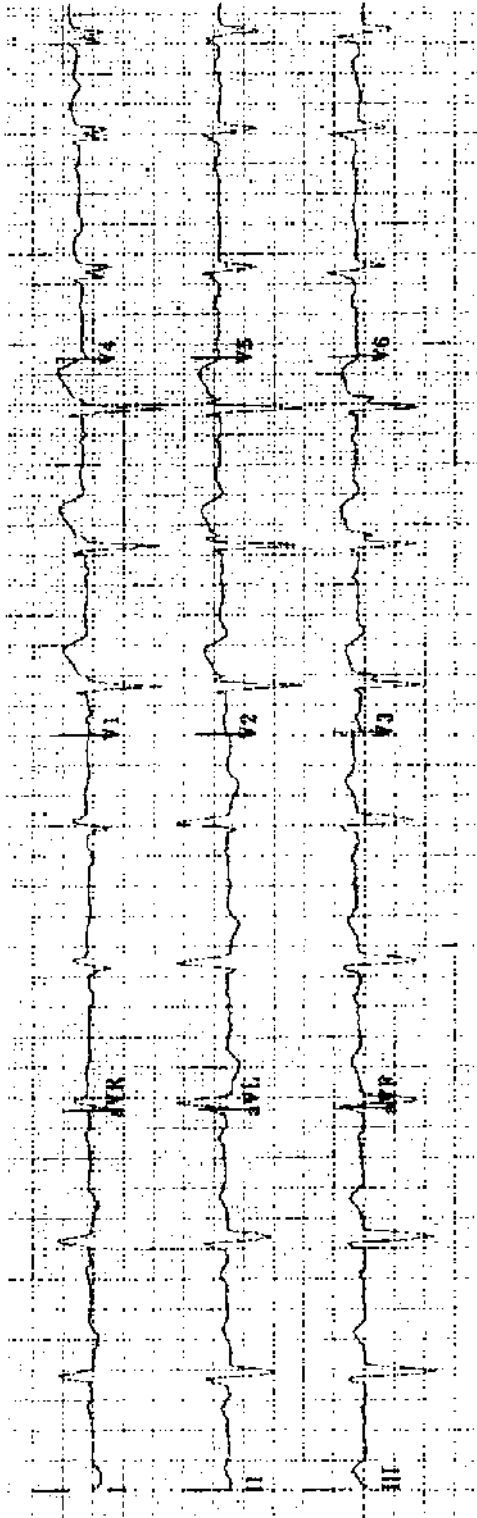
Practice ECG 62 An 83-year-old man with a long history of irregular pulse. He is on digoxin. Does he need additional drug therapy?



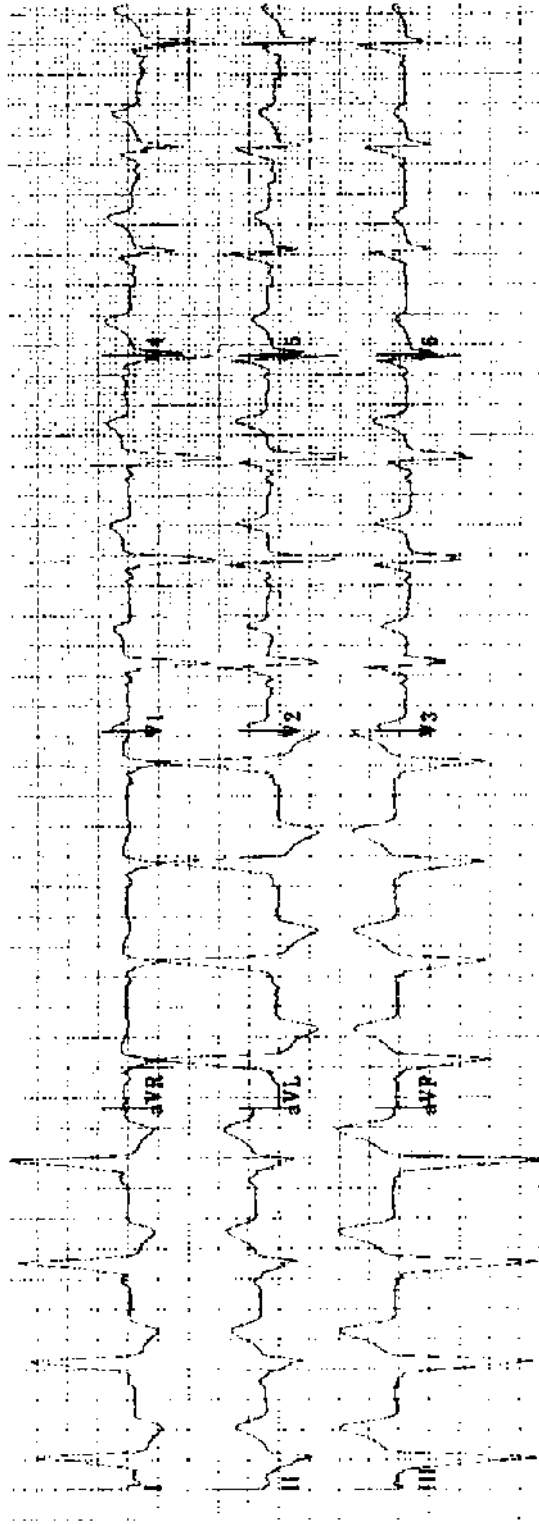
Practice ECG 63 A 59-year-old man in the emergency room.



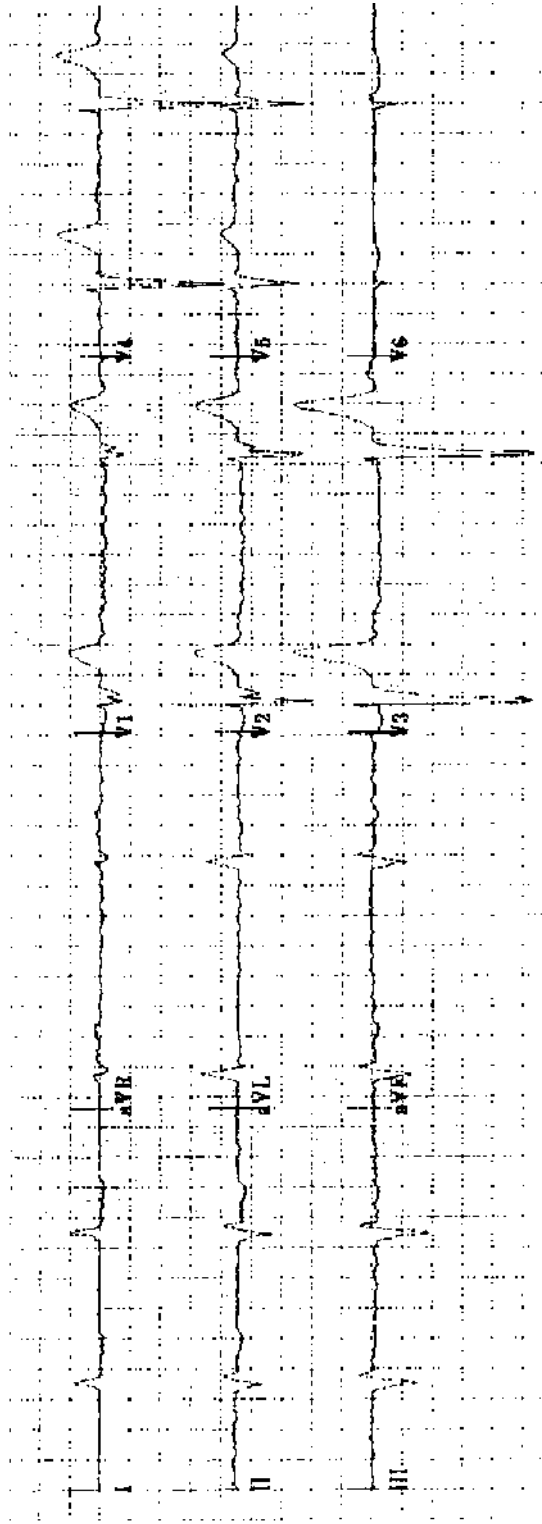
Practice ECG 64 An 82-year-old man on digoxin sent from the nursing home with confusion and blurred vision.



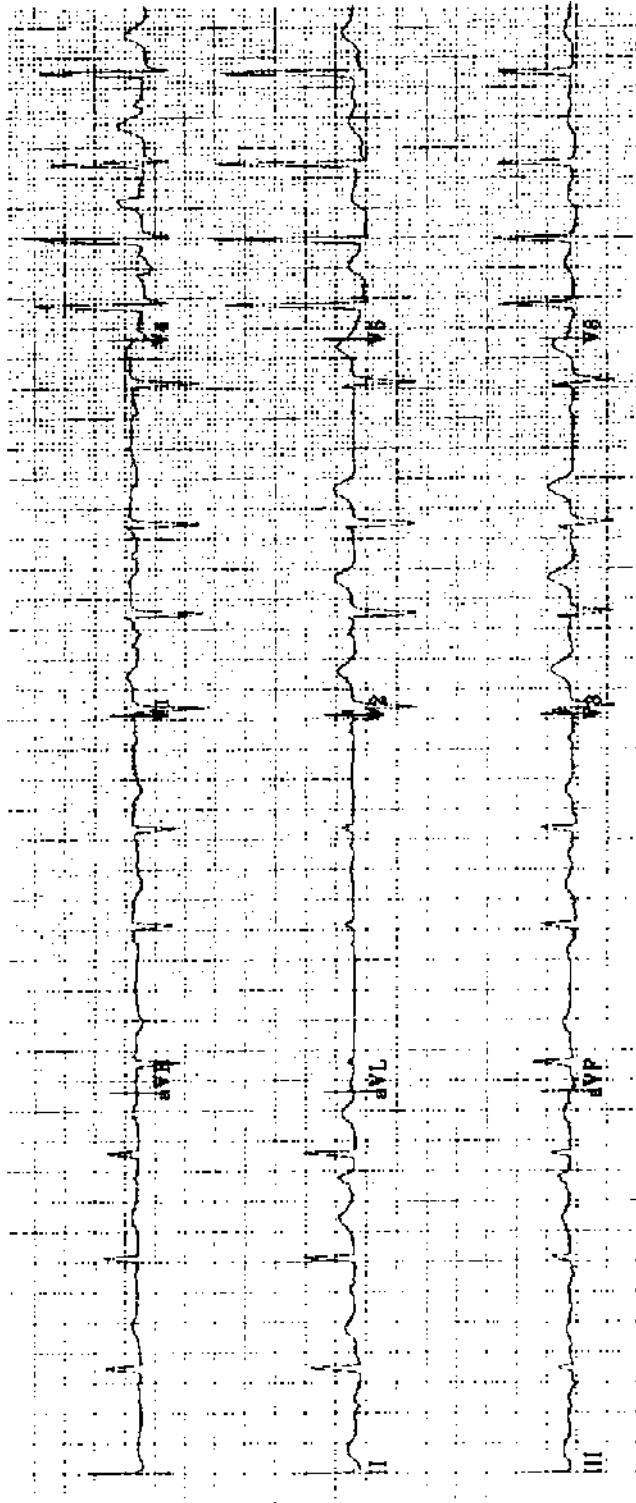
Practice ECG 65 A 66-year-old man with a history of vague, nonspecific chest pain and a positive stress test.




Practice ECG 66 A 26-year-old woman with palpitations. Her ECG was normal the day after this tracing was obtained.



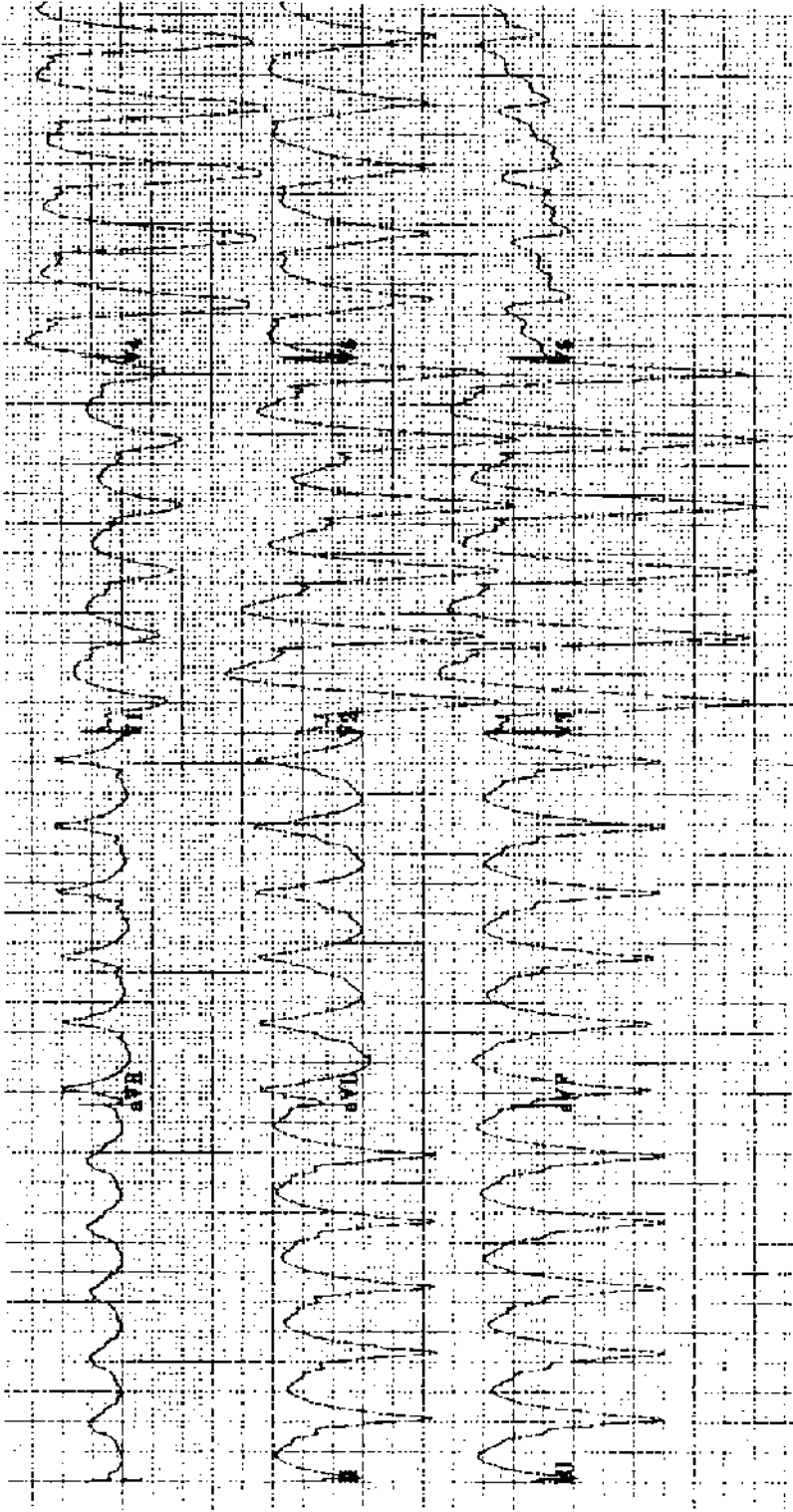
Practice ECG 67 An 86-year-old man with dizzy spells for 1 week, on no medicine. What should his doctor do?



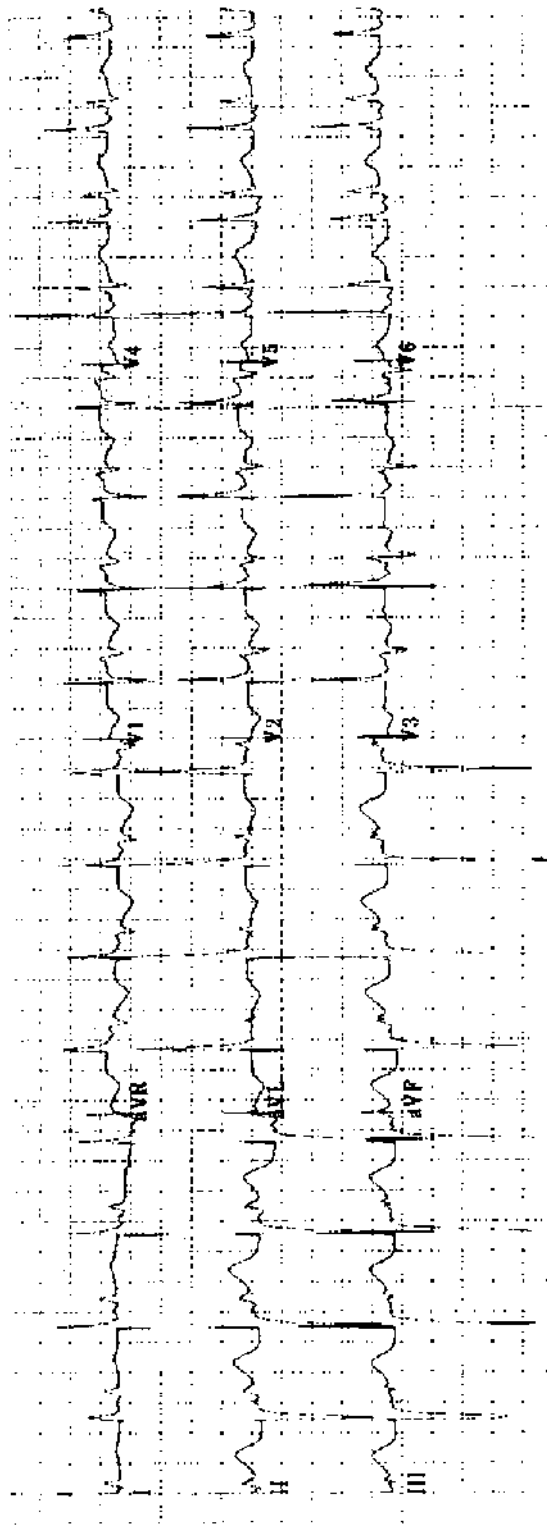
Practice ECG 68 An 85-year-old woman with mild heart failure, on digoxin.



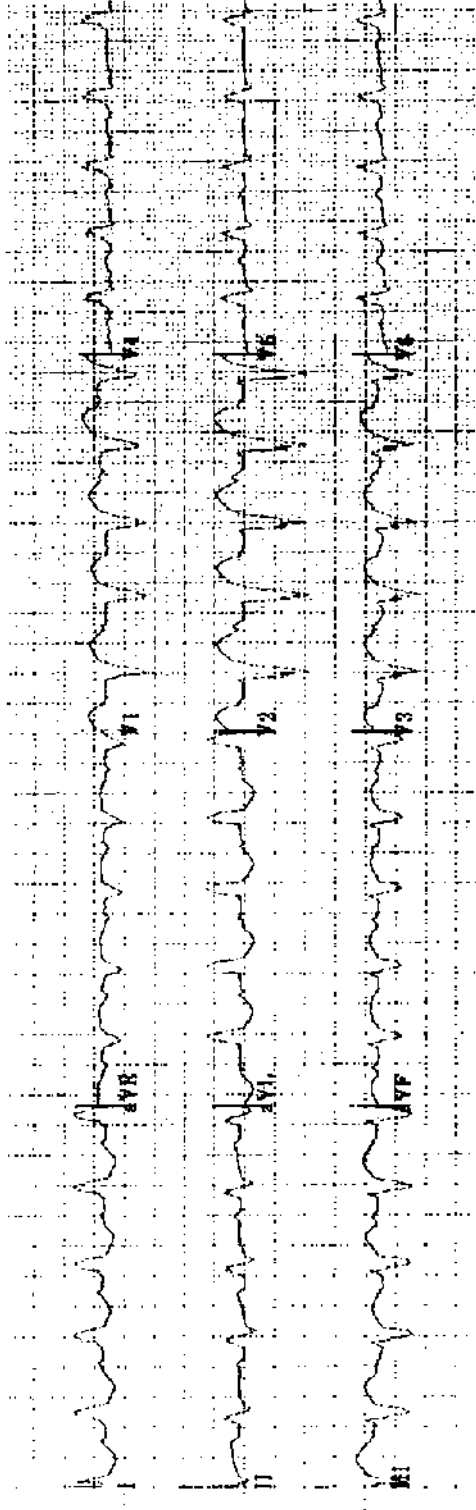
Practice ECG 69 A 70-year-old woman with ankle edema on two diuretics and potassium supplements.



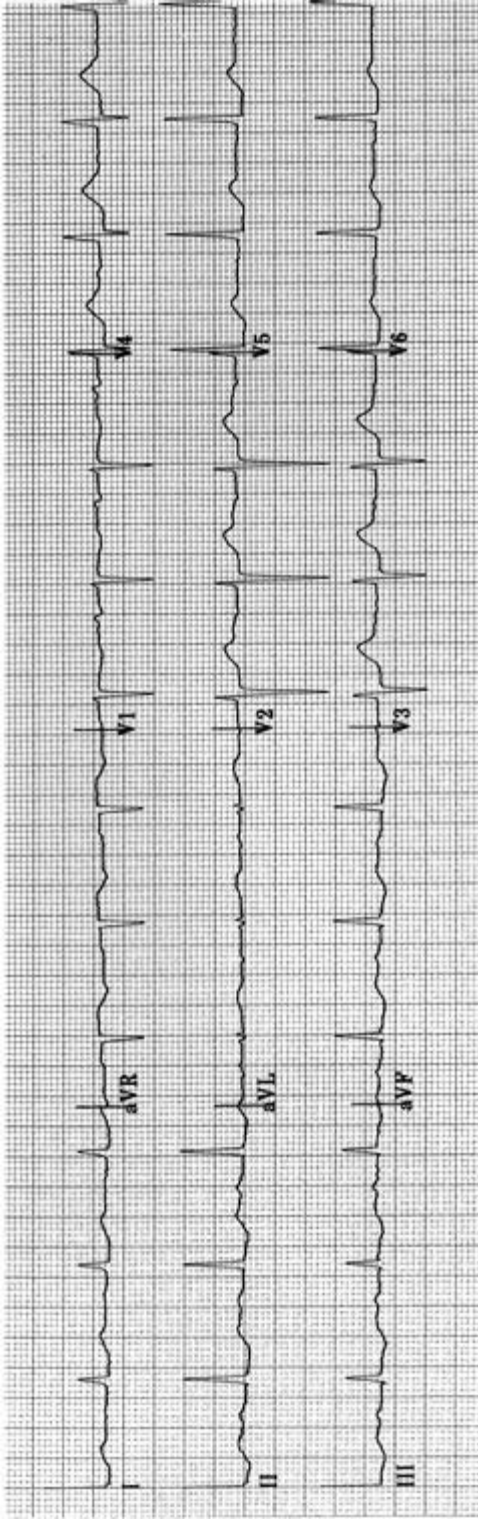
Practice ECG 70 A 77-year-old man in the emergency room with pounding in his chest.



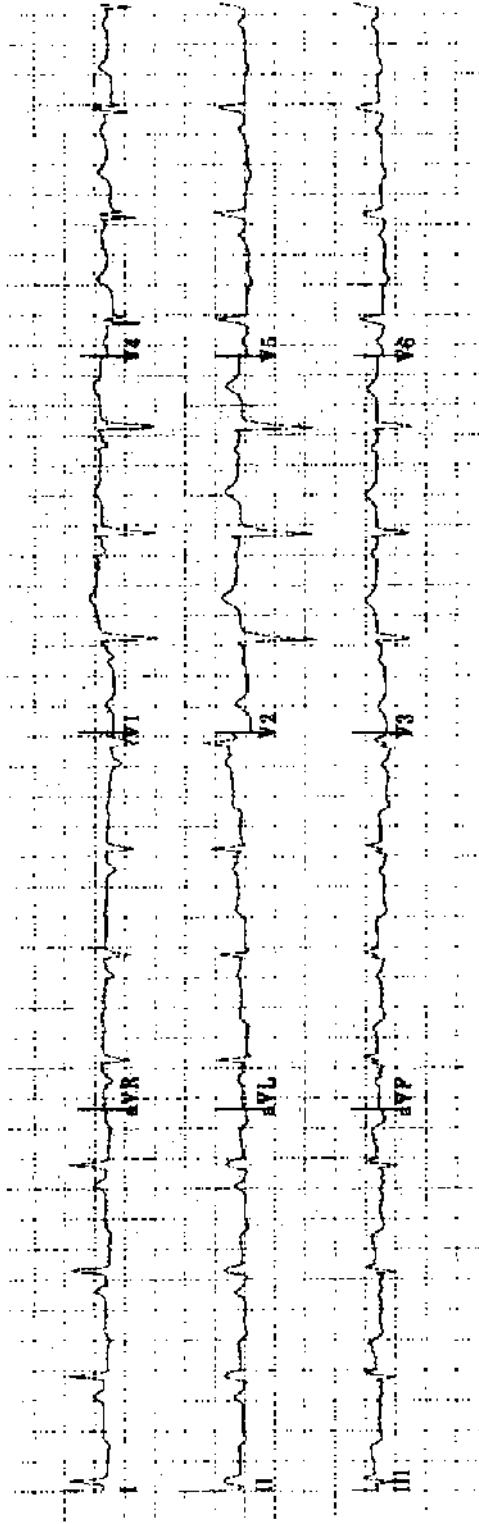
Practice ECG 71 An 81-year-old woman with chest pain.



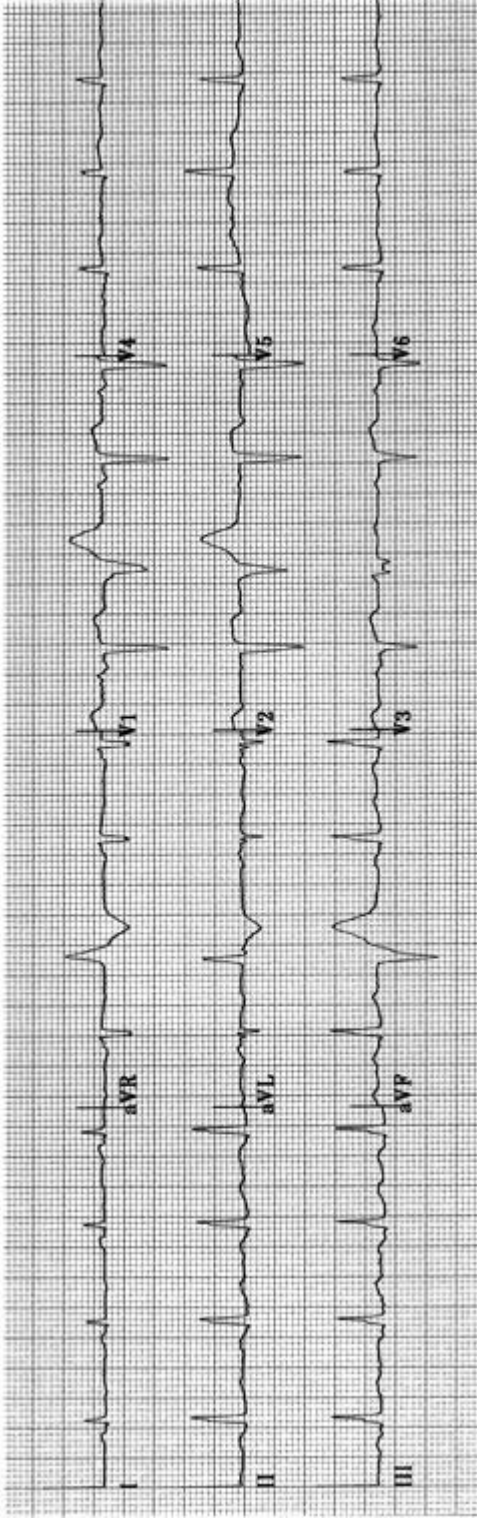
Practice ECG 72 A 78-year-old woman, postoperative ECG. The preoperative tracing showed mild intraventricular conduction defect.



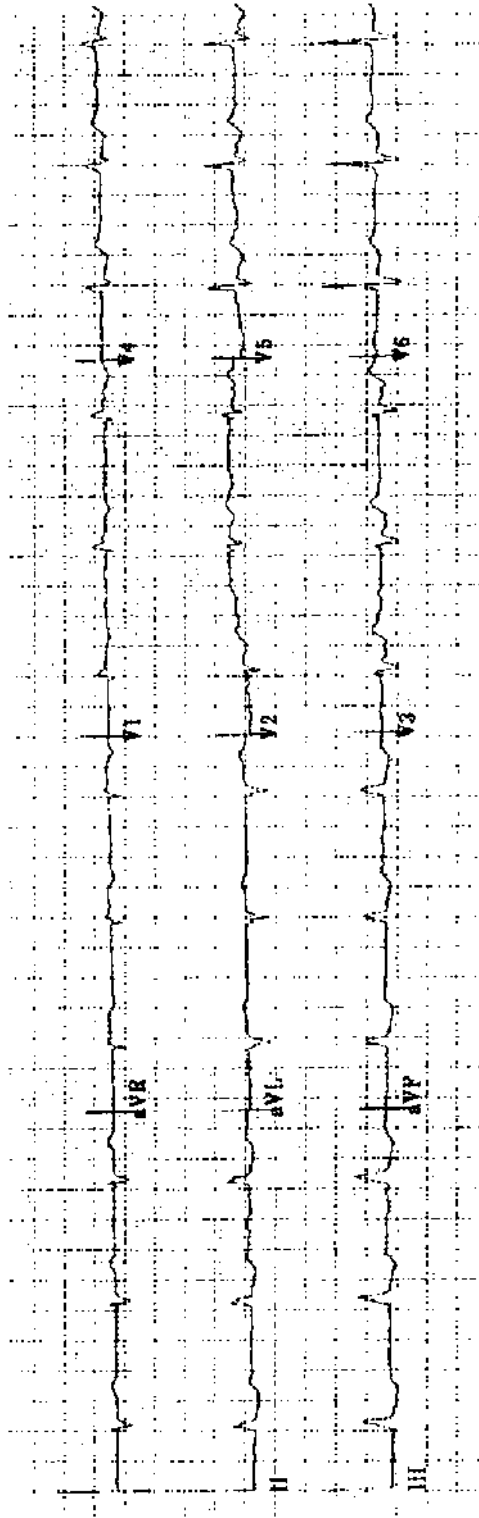
Practice ECG 73 A 54-year-old woman with a history of paroxysmal atrial fibrillation.



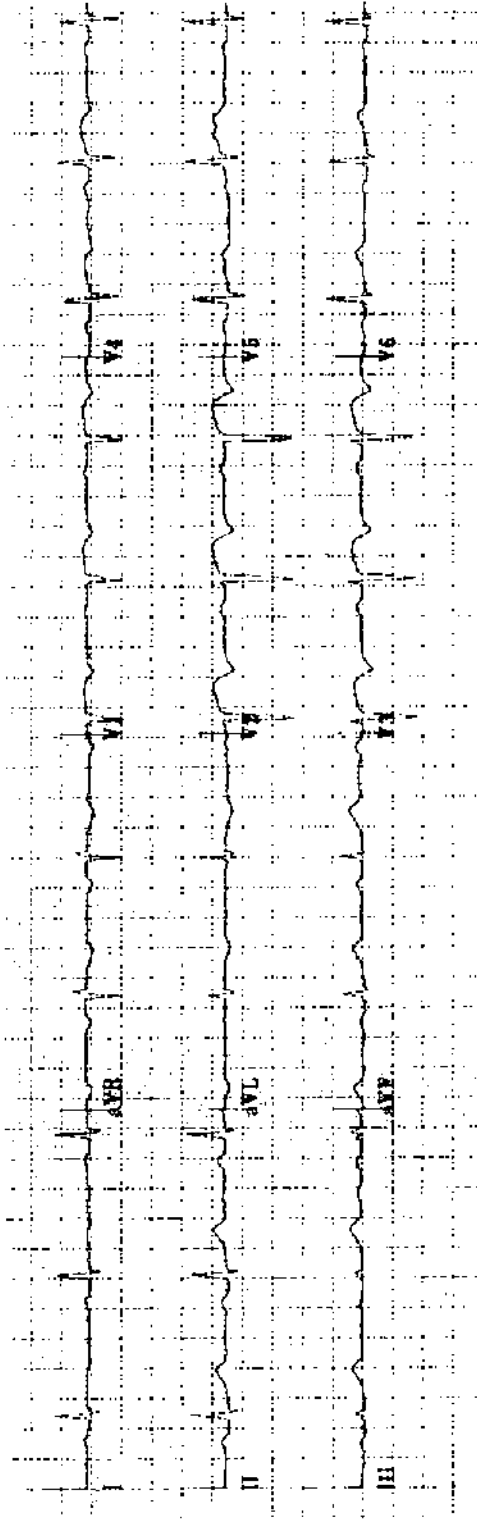
Practice ECG 74 A 72-year-old woman with chest pain of 2 hours duration. What is the correct treatment?



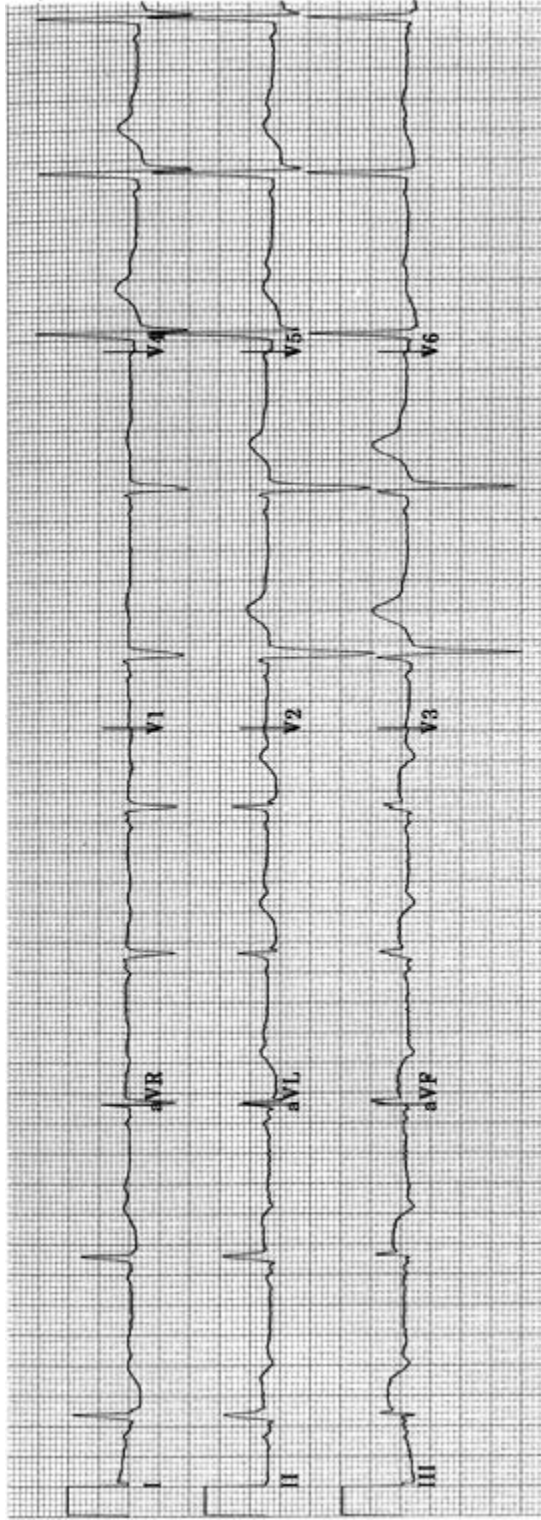
Practice ECG 75 An 80-year-old woman with previous MI. What is the origin of the ectopic beats?



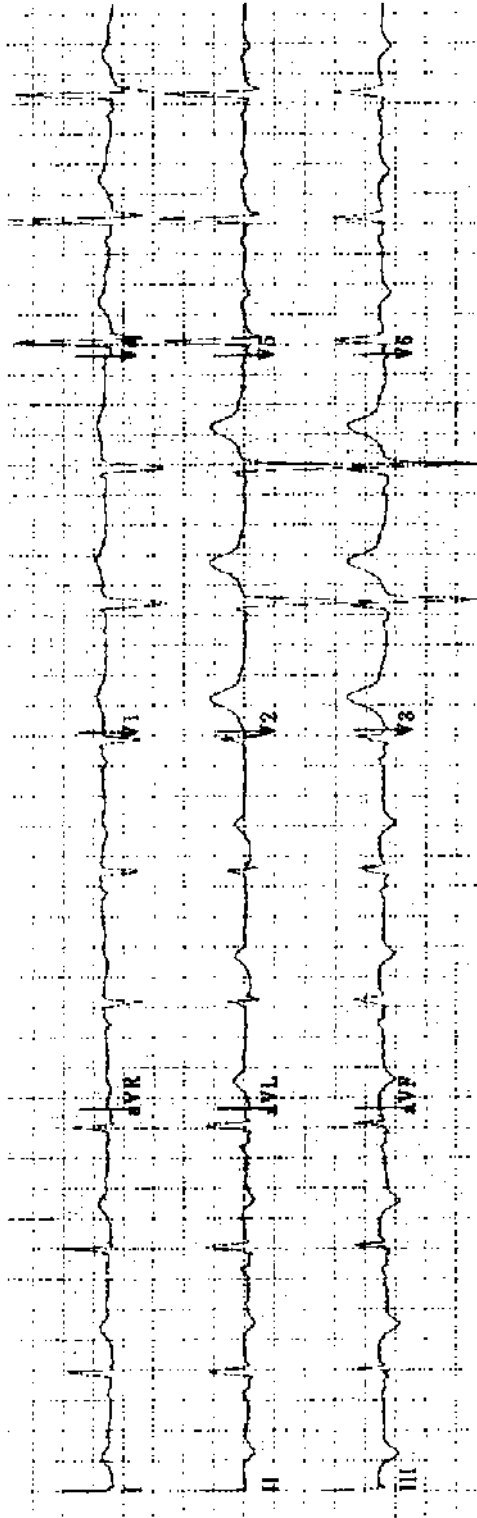
Practice ECG 76 A 64-year-old woman with chronic cough, dyspnea, and ankle edema. She still smokes two packs of cigarettes a day.



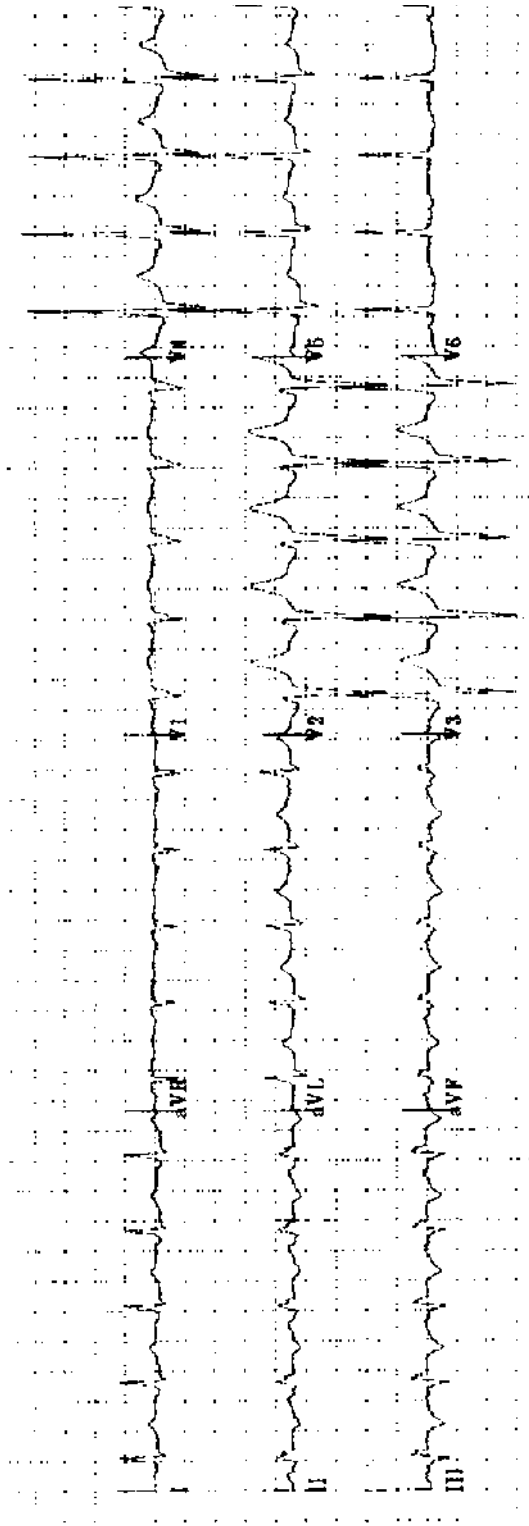
Practice ECG 77 A 67-year-old woman transferred because of a 1-hour episode of chest pain on the previous day.



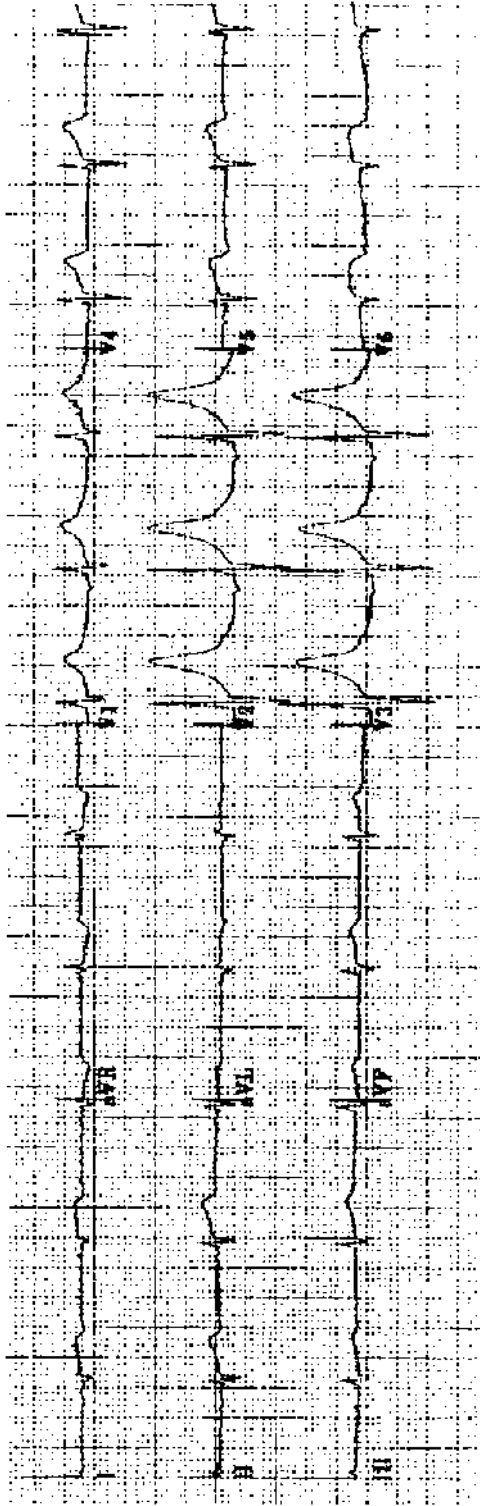
Practice ECG 78 A 39-year-old farmer whose wife drove him to the local emergency room with chest pain that began 30 minutes earlier. He is 70 miles from the regional cardiac center. What is the appropriate treatment?




Practice ECG 79 Same patient (No. 78), about 1 hour later. Chest pain has resolved. What is the treatment now?



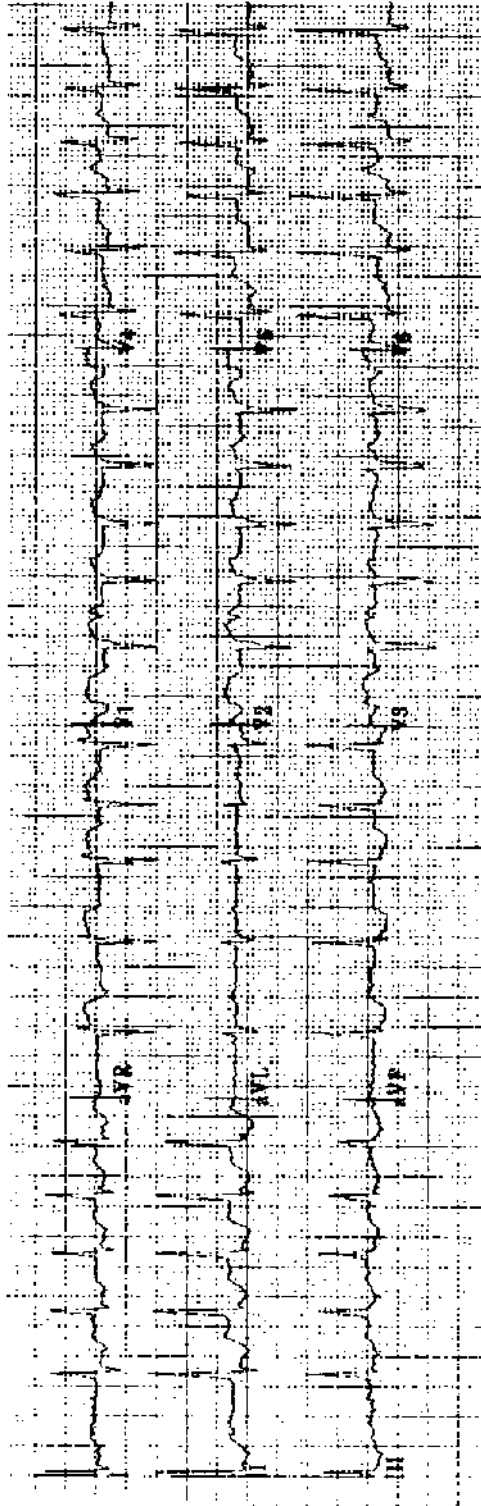
Practice ECG 80 Same patient (No. 78), after 2 days of heparin therapy at the local hospital. He has developed more chest pain, but not quite like what he had at the time of admission.



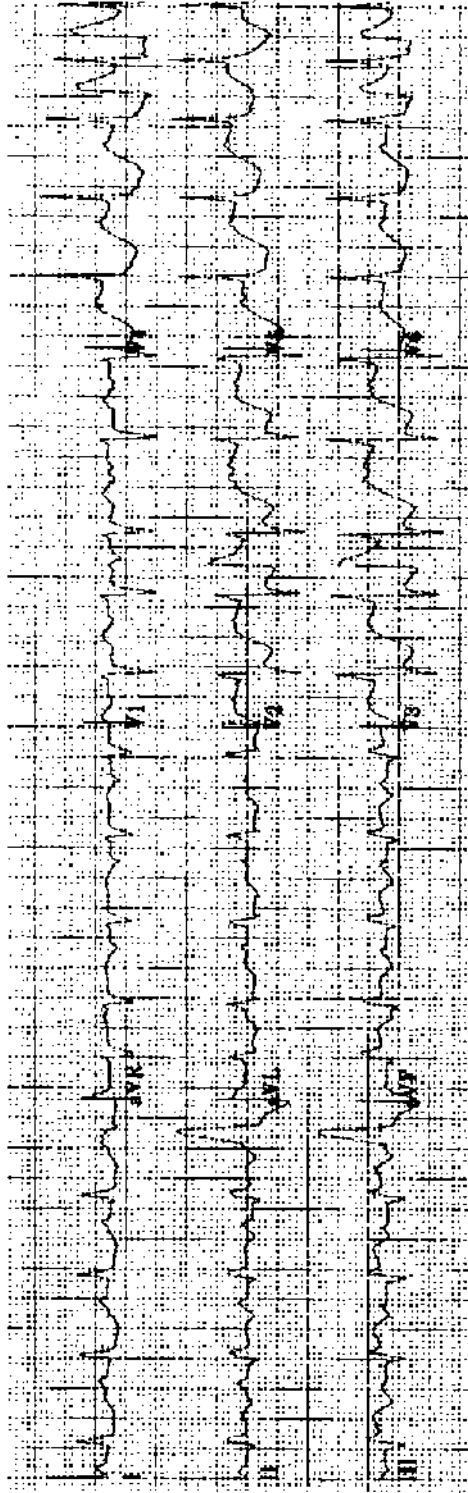
Practice ECG 81 A 46-year-old man with chest pain of 3 hours duration. What treatment would be appropriate?



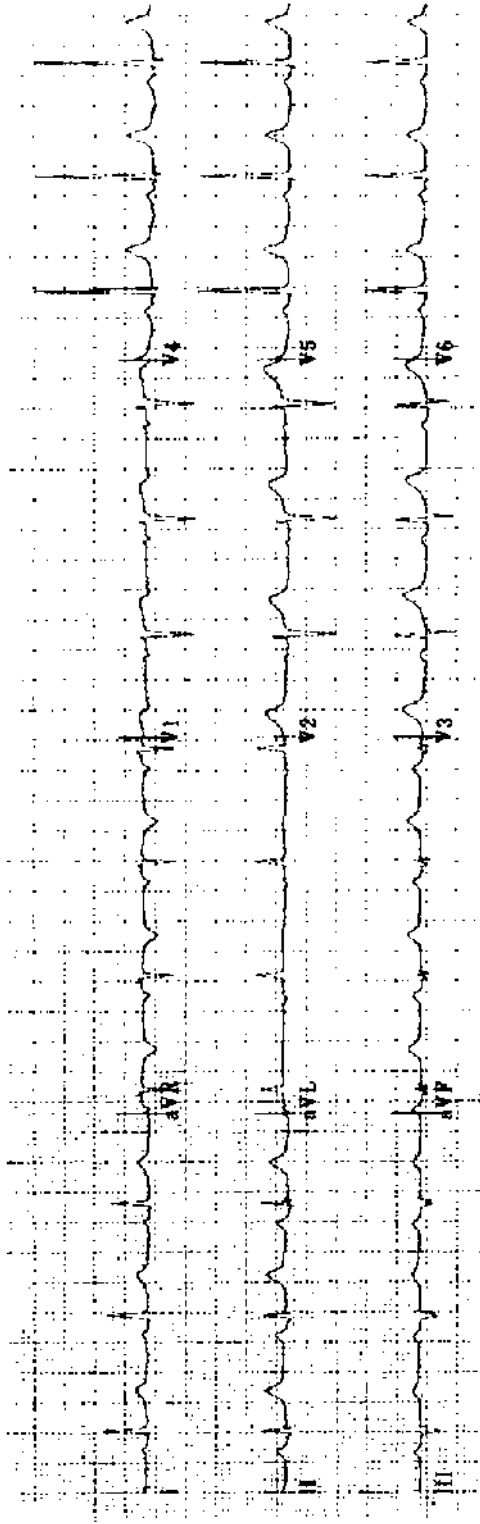
Practice ECG 82 A 60-year-old woman in good health; routine exam.



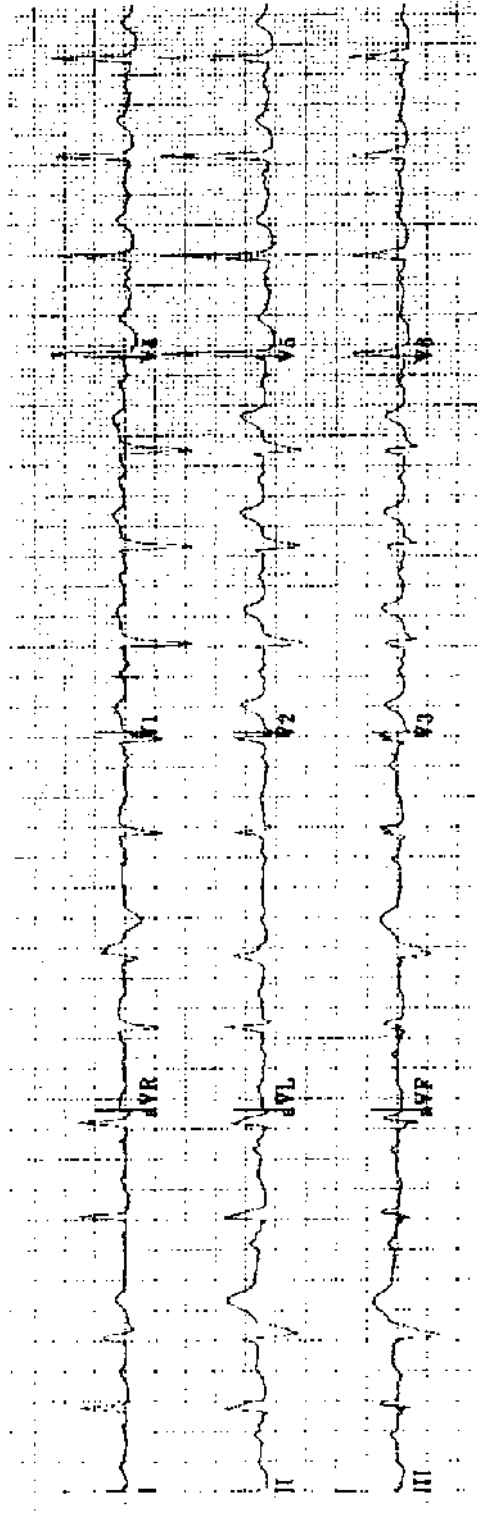
Practice ECG 83 A 75-year-old woman transferred from a nursing home with dyspnea and pleurisy.



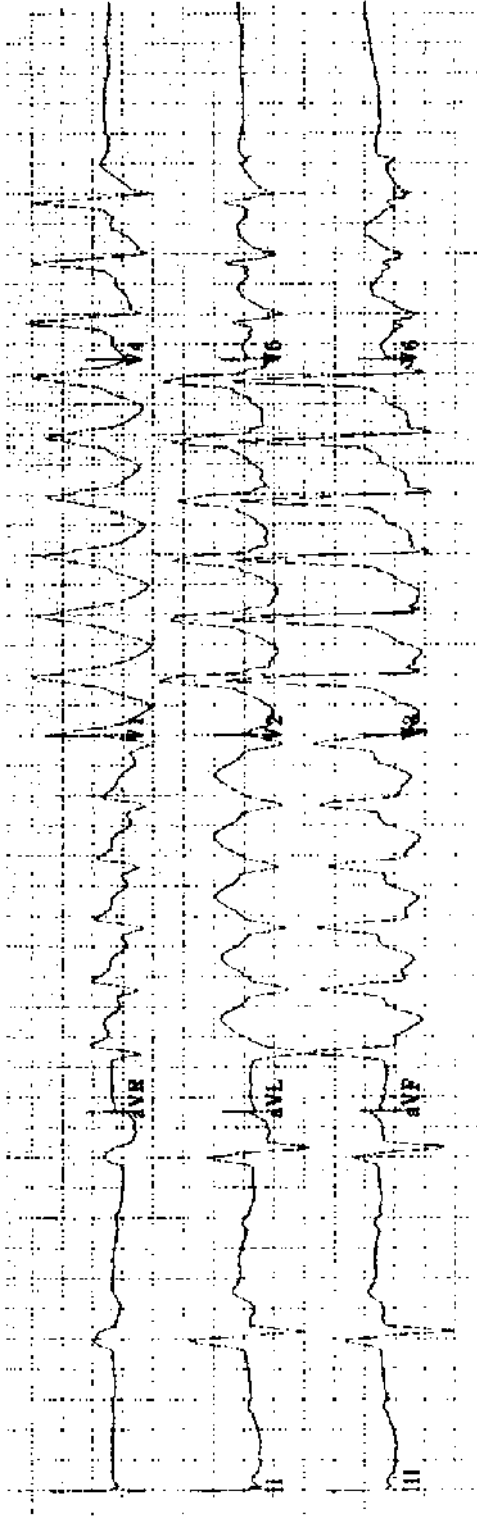
Practice ECG 84 A 74-year-old man in the emergency room with chest pain that began 30 minutes earlier. Is this angina or MI? Is the ischemia anterior or inferior?




Practice ECG 85 A 56-year-old man with no cardiac history; he wants to start a jogging program.



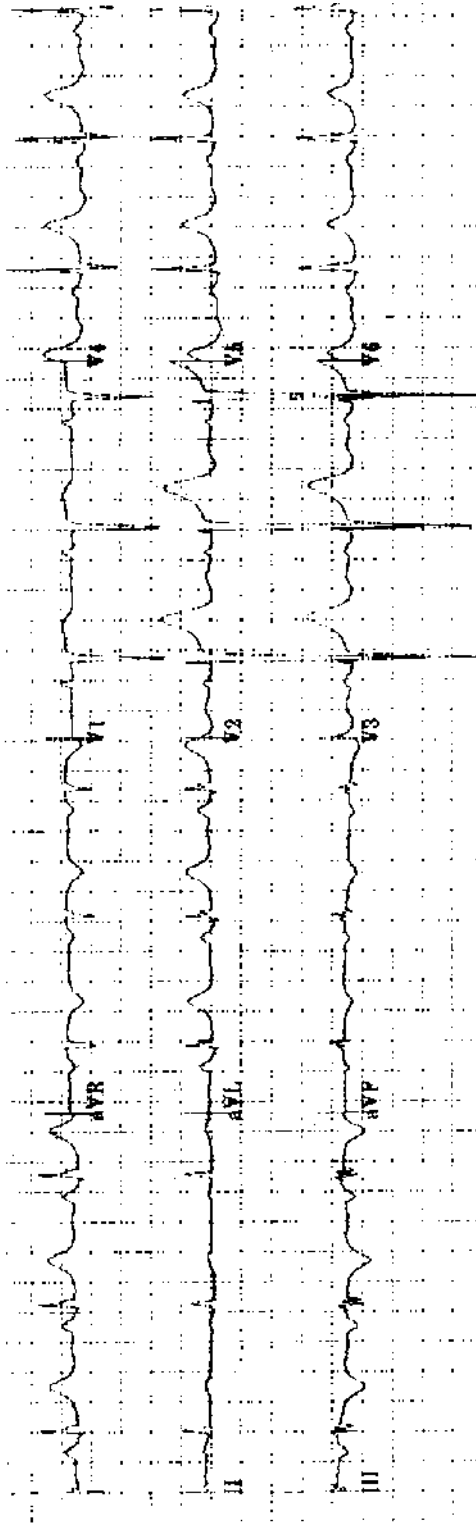
Practice ECG 86 A 57-year-old man treated for hypertension. Is there evidence of hypertensive heart disease?



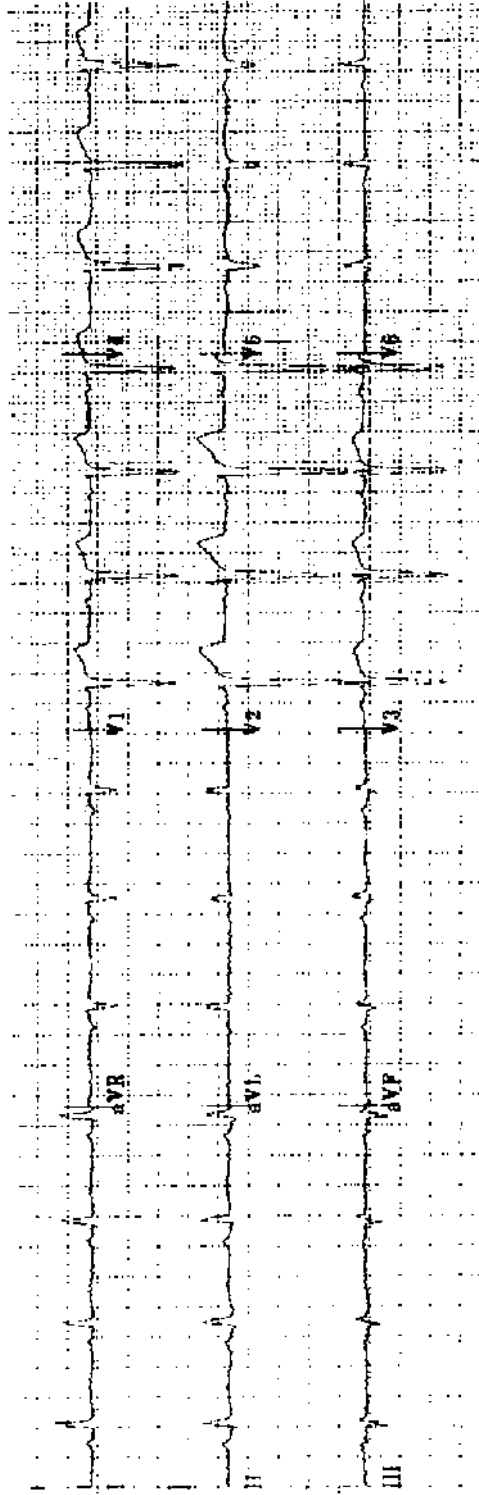
Practice ECG 87 An 82-year-old man with palpitations and dizziness.



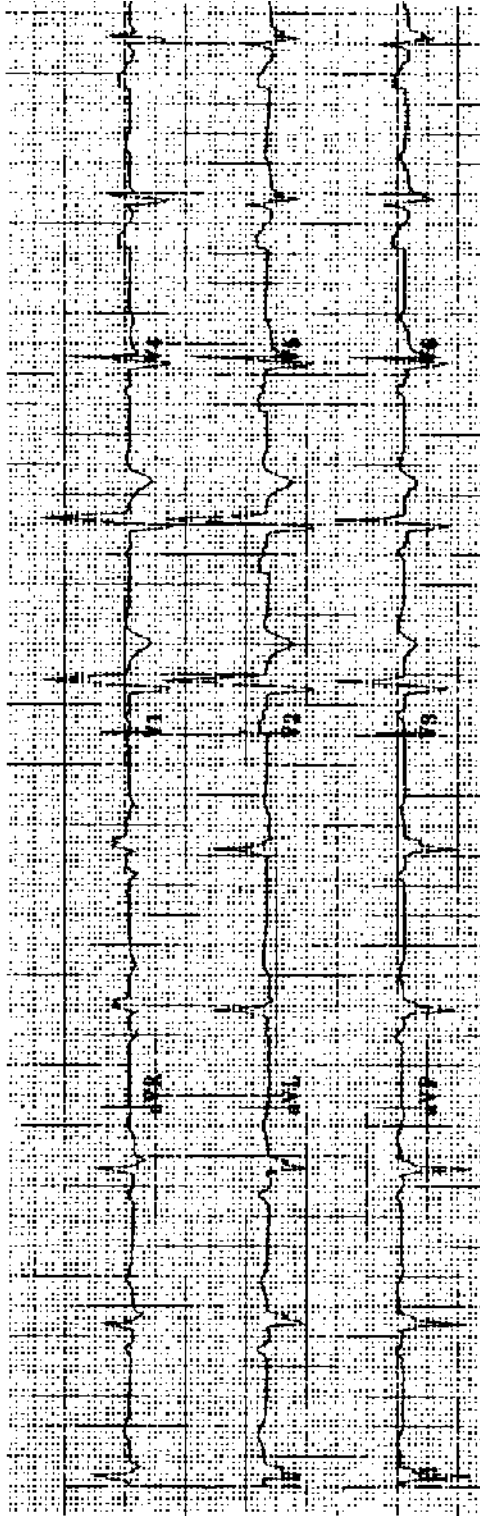
Practice ECG 88 An 80-year-old woman with a history of MI and a pacemaker; routine clinic visit.



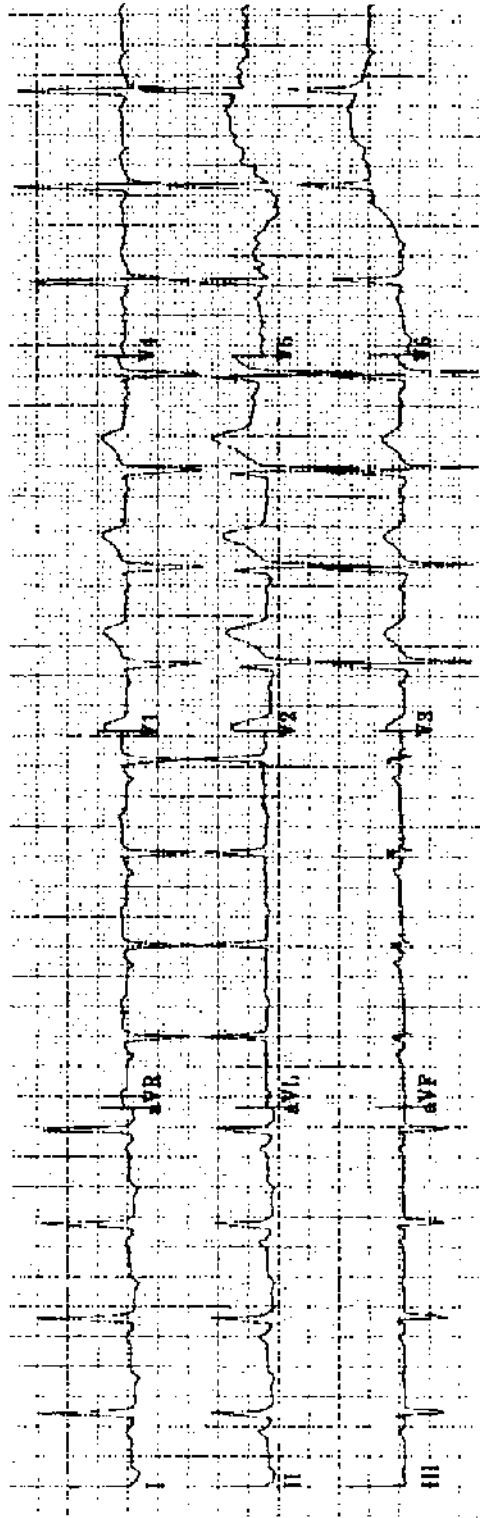
Practice ECG 89 A 59-year-old woman with intermittent indigestion of 2 weeks duration.



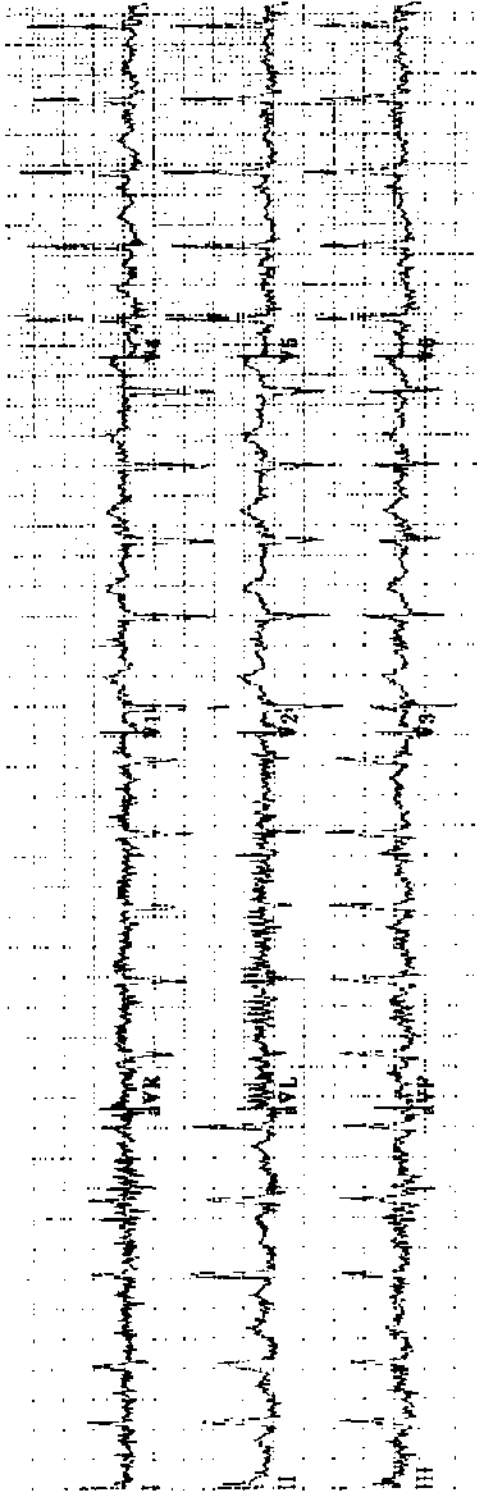
Practice ECG 90 A 48-year-old man with a history of inferior MI. Has he had a second MI?



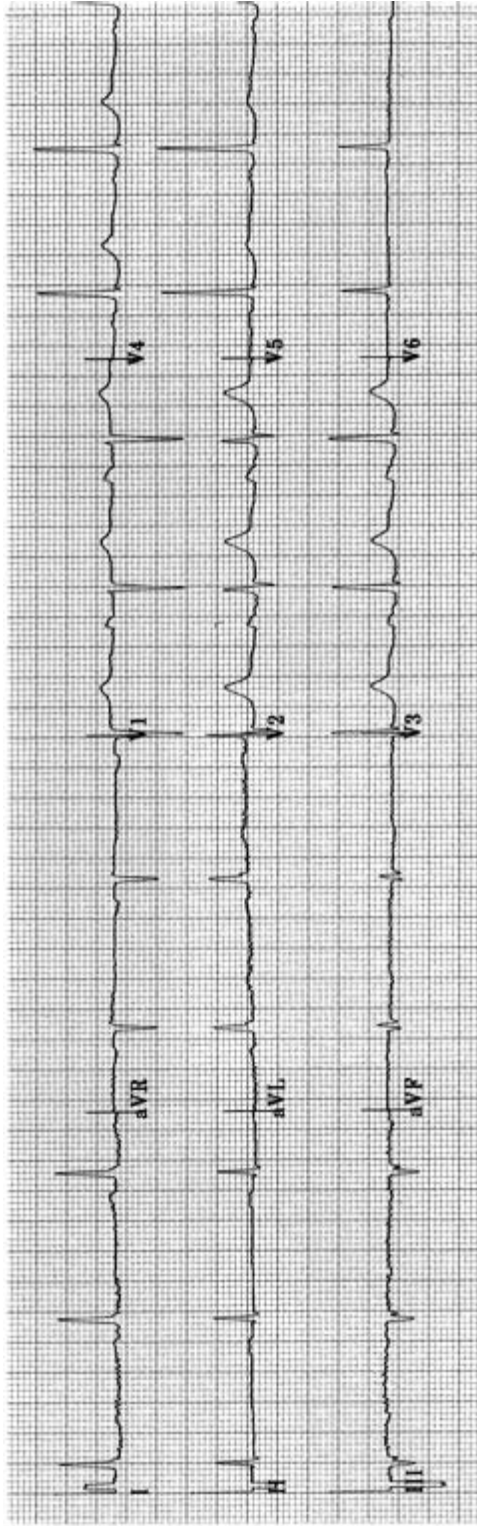
Practice ECG 91 A 50-year-old with a history of MI. Have there been multiple infarctions?



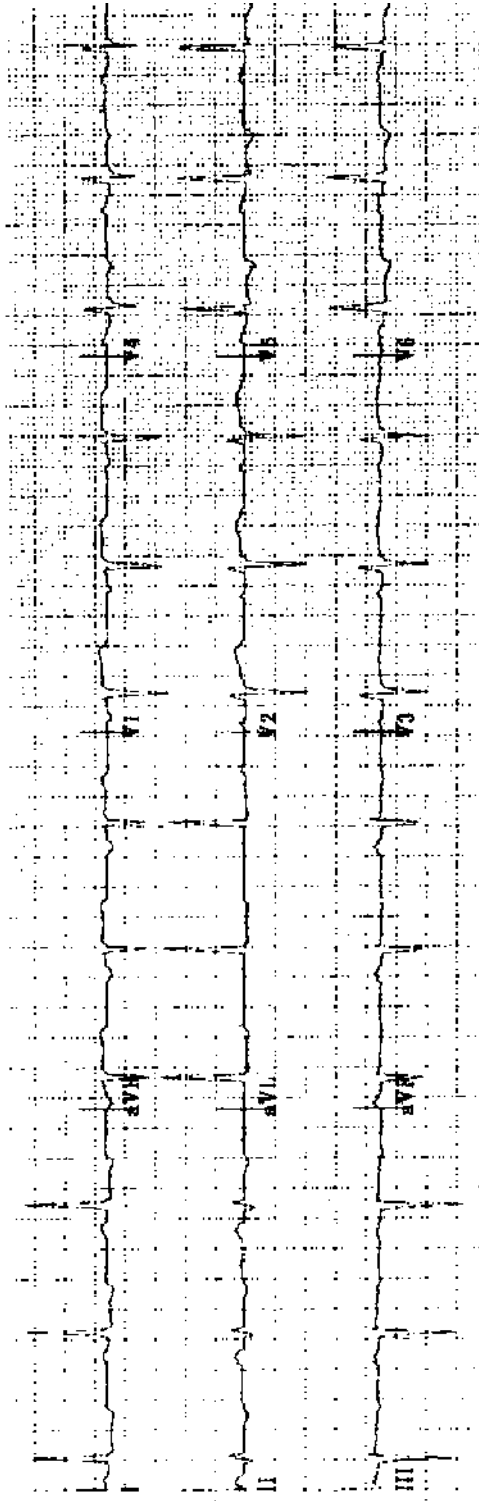
Practice ECG 92 A 56-year-old man; preoperative ECG.



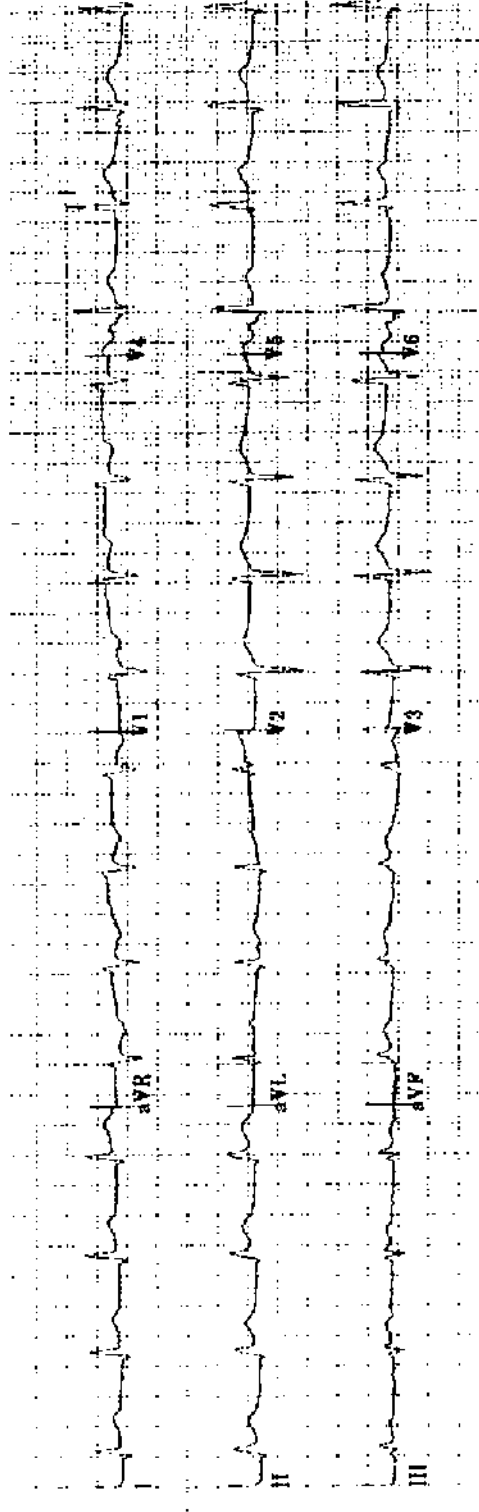
Practice ECG 93 A 65-year-old woman with sepsis.



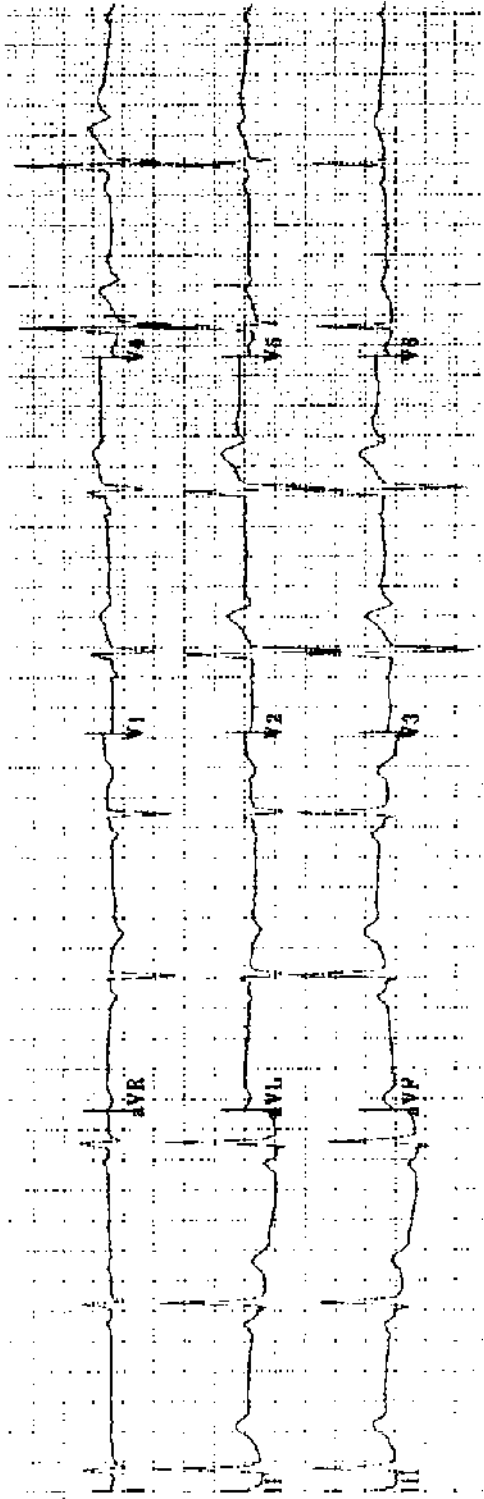
Practice ECG 94 A 52-year-old man sent to cardiology clinic because of an abnormal ECG. He has hypertension but no history of chest pain.



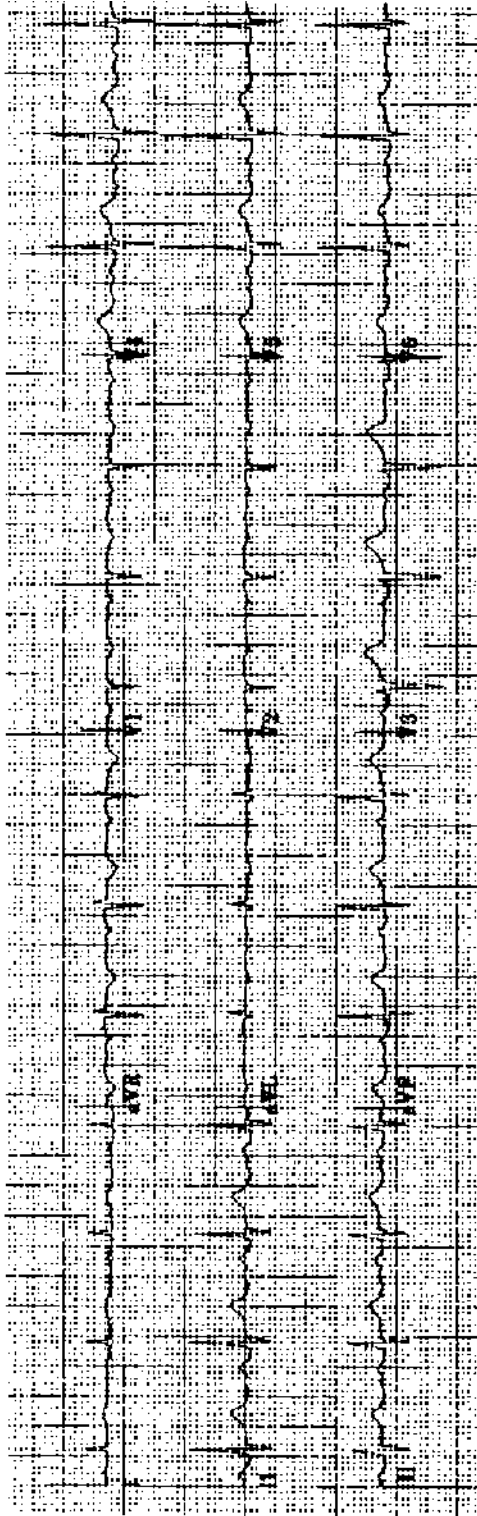
Practice ECG 95 A 63-year-old man; annual exam.



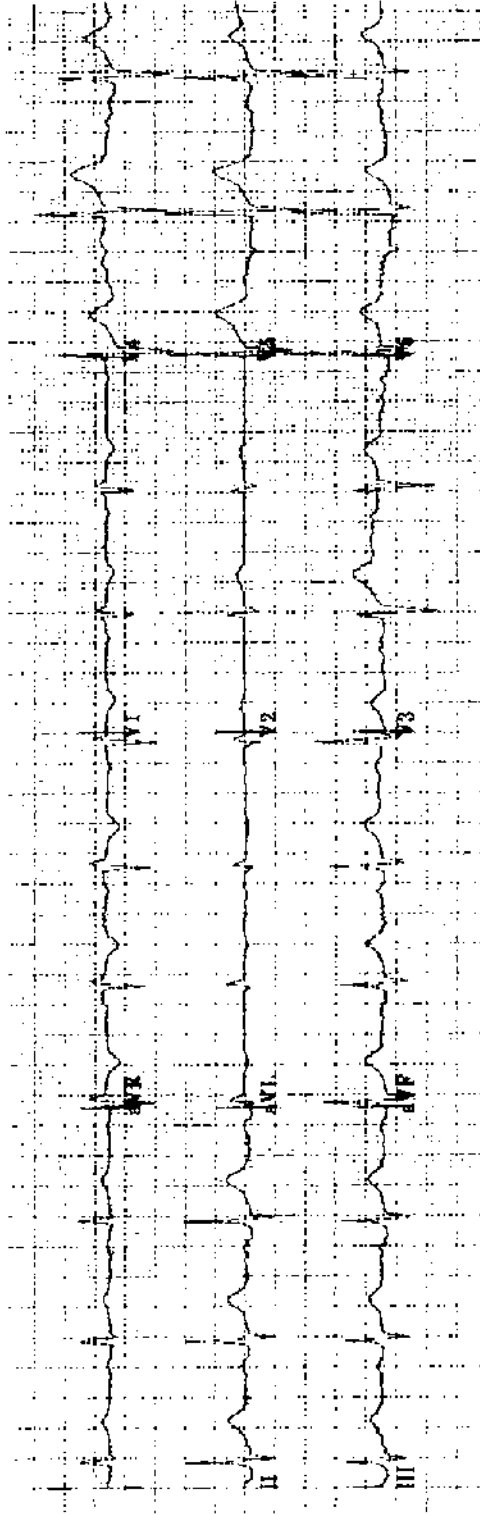
Practice ECG 96 A 71-year-old man with chest pain for 3 hours.



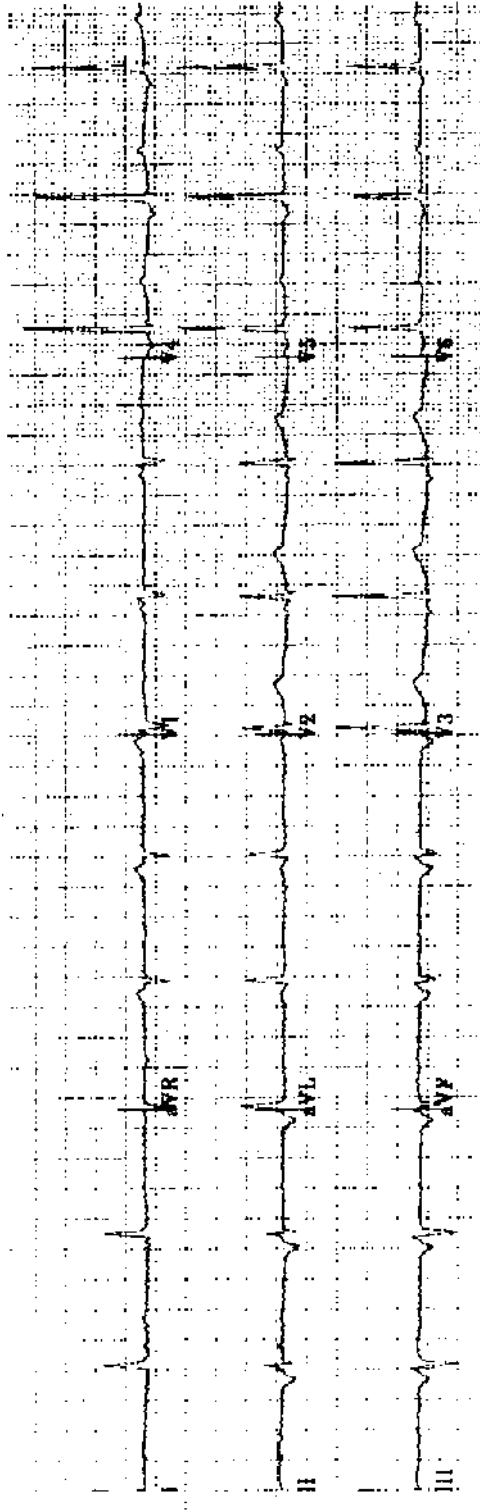
Practice ECG 97 A 58-year-old man; no clinical data provided.



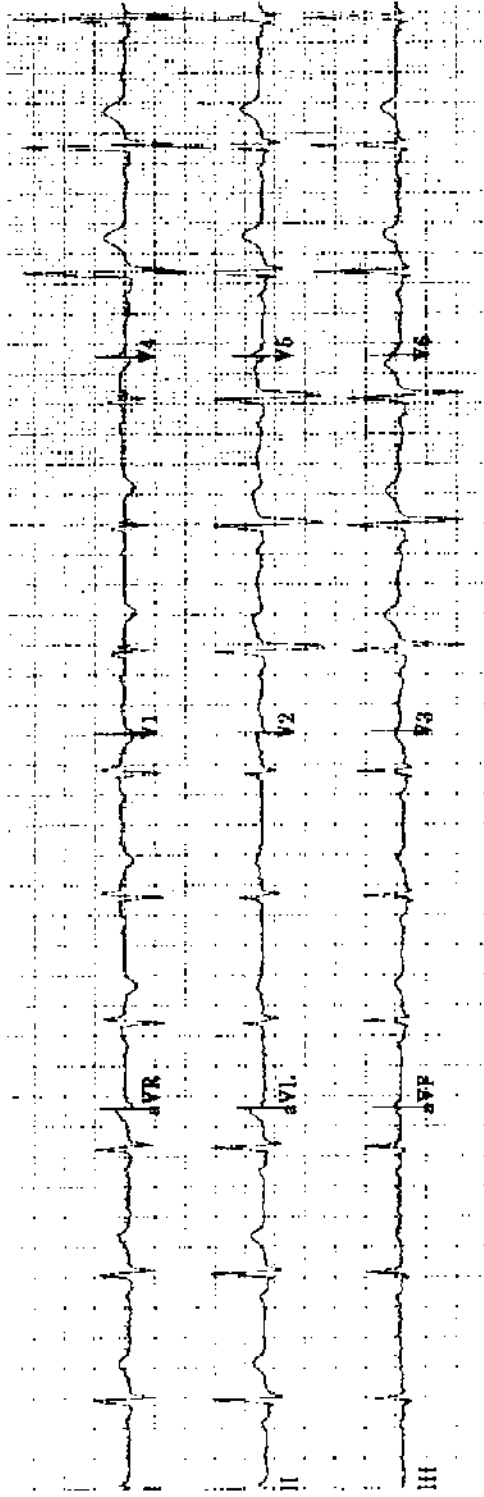
Practice ECG 98 An 81-year-old woman; no clinical data provided.




Practice ECG 99 A 73-year-old man in good health.



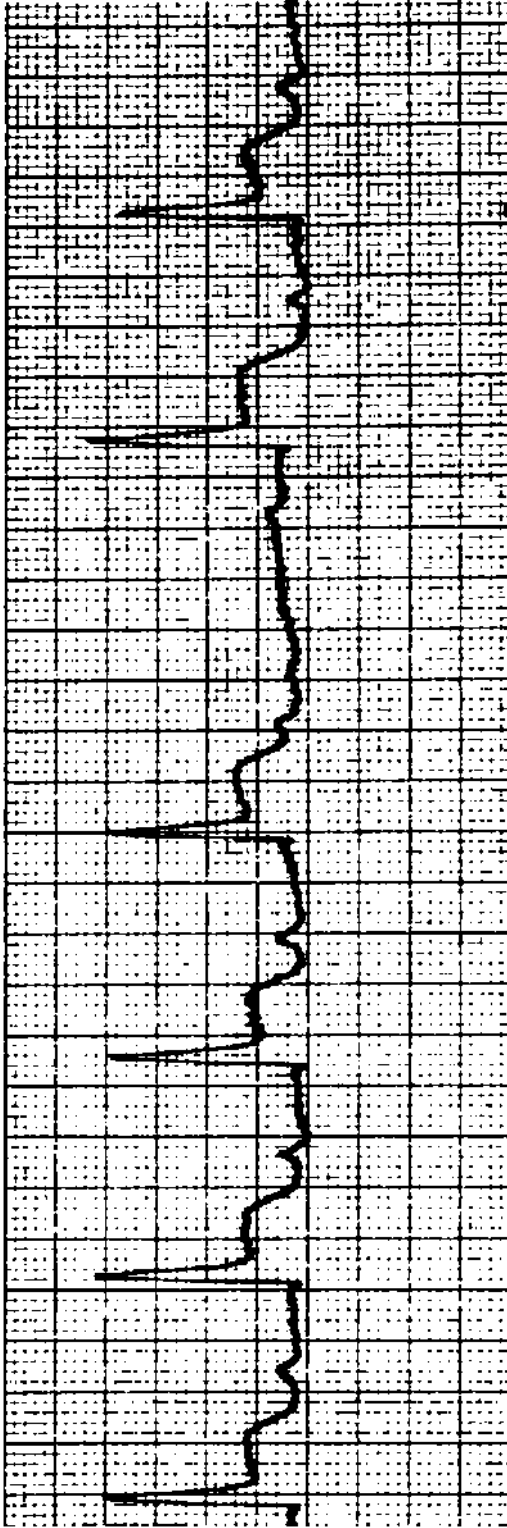
Practice ECG 100 A 63-year-old man; routine examination.



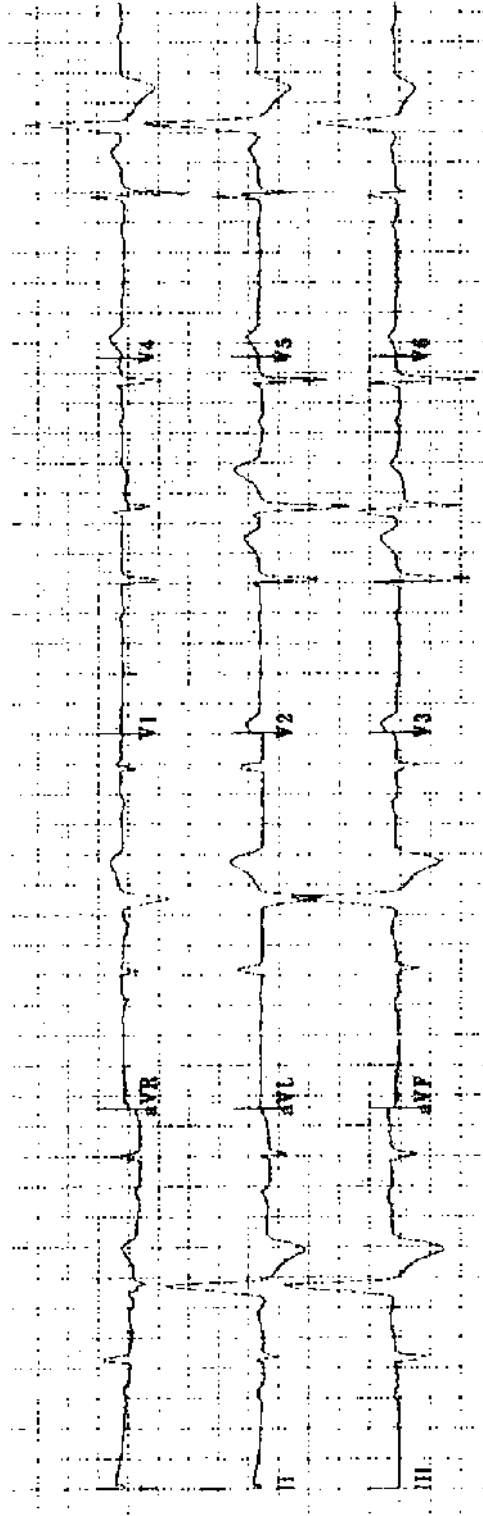
Practice ECG 101 A 46-year-old man; insurance physical.



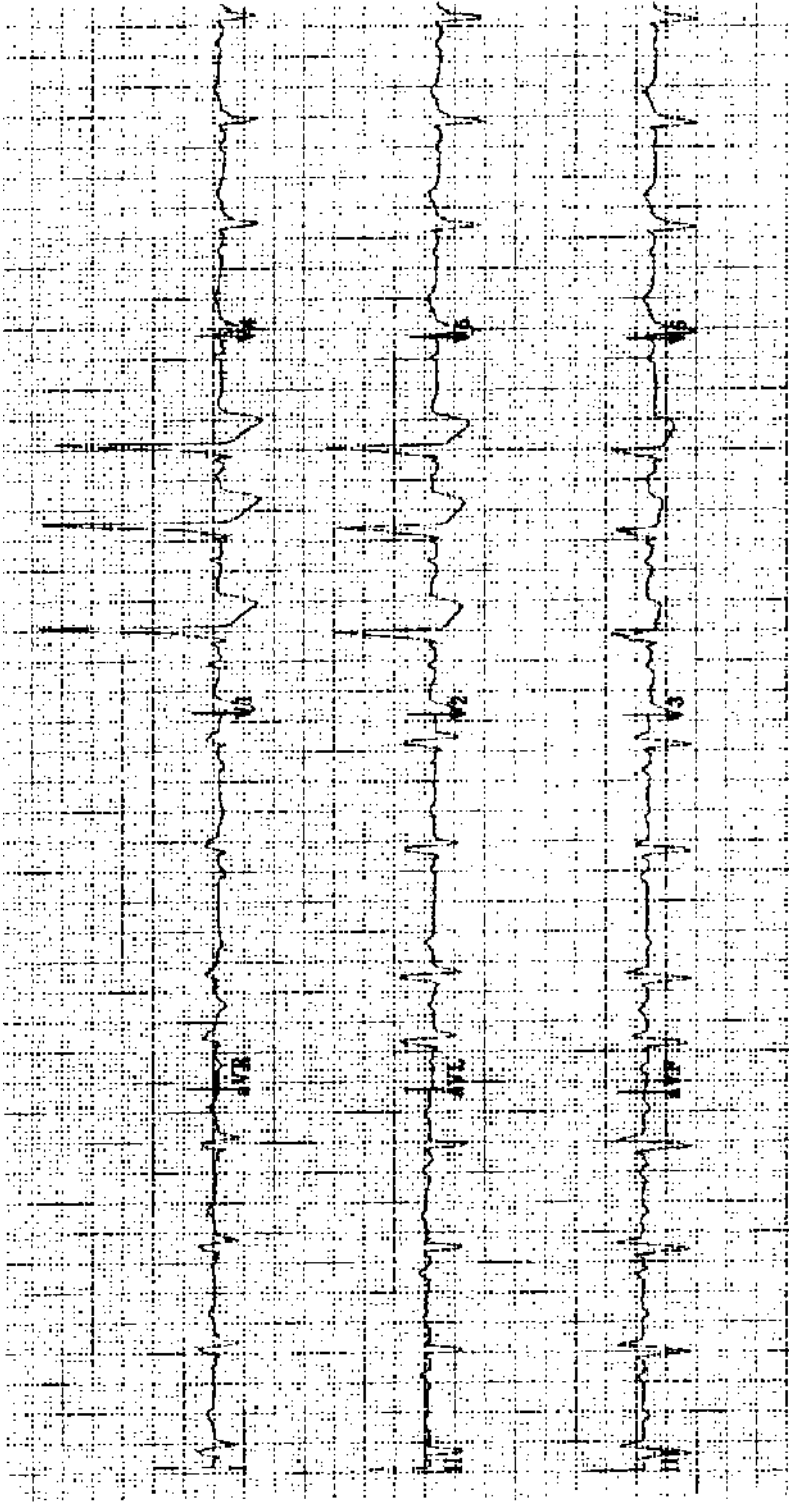
Practice ECG 102 A patient with an irregular pulse.



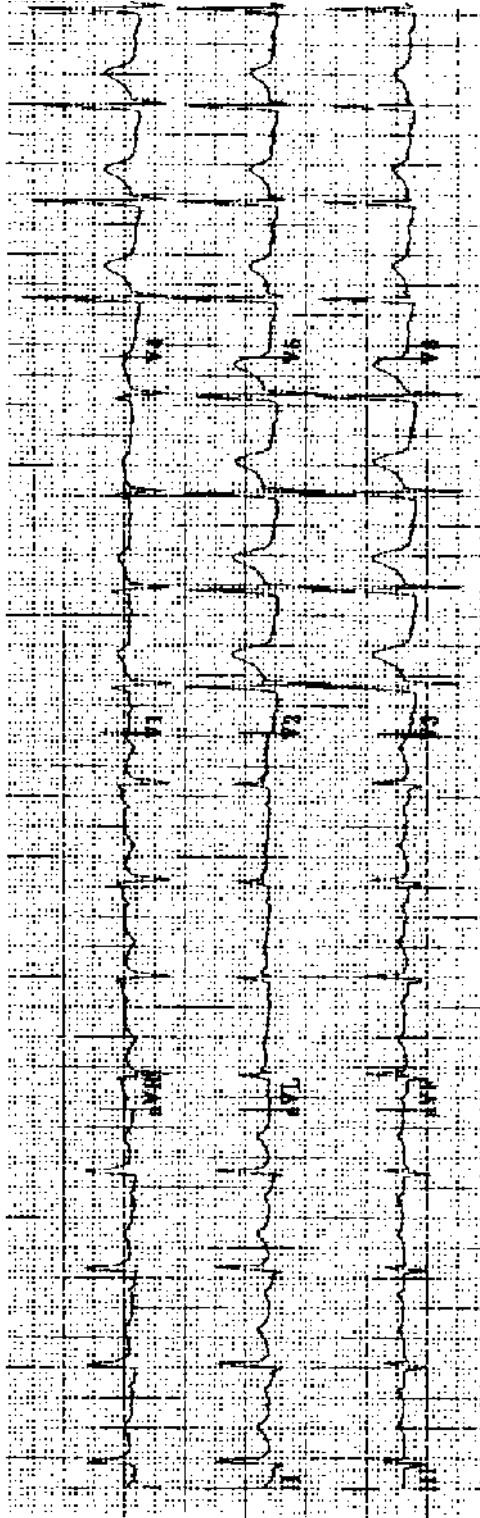
Practice ECG 103 A 68-year-old woman with acute inferior MI. Does she need a temporary pacemaker?



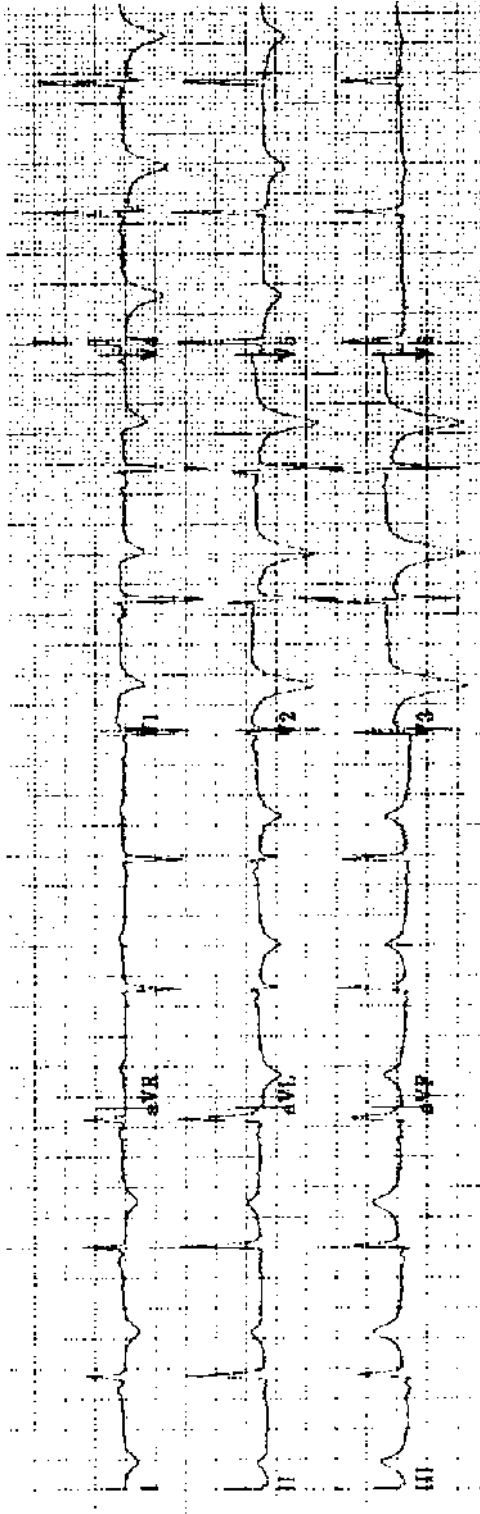
Practice ECG 104 A 55-year-old man with palpitations and a history of MI.



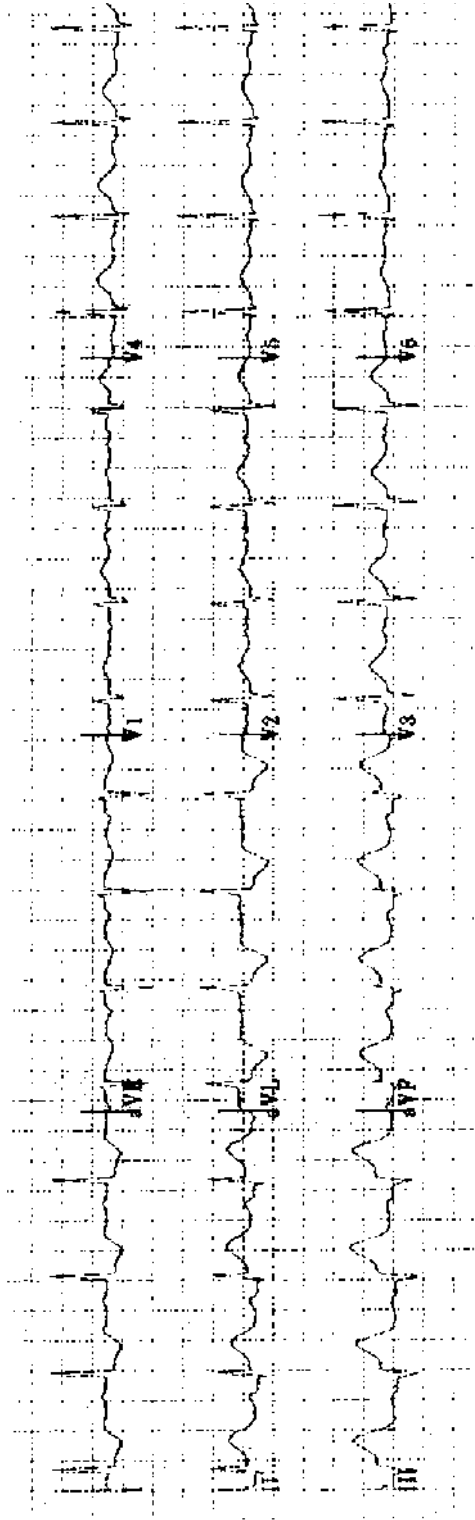
Practice ECG 105 A 75-year-old woman with obstructive lung disease and ankle edema.



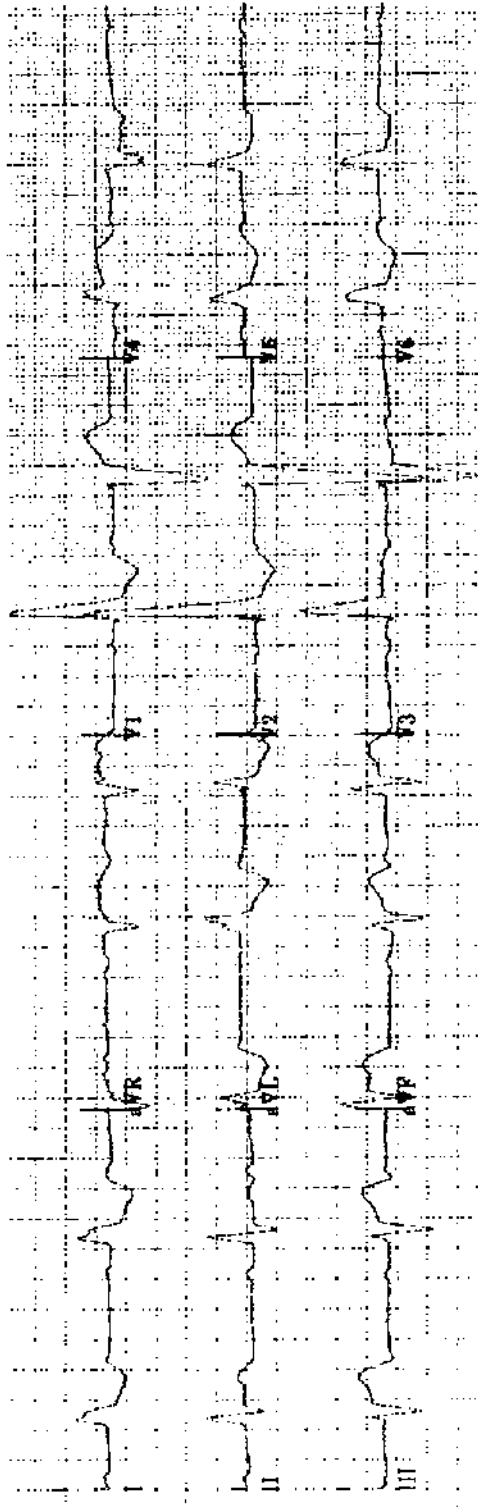
Practice ECG 106 A 54-year-old man with no history of heart disease. He weighs 275 pounds.



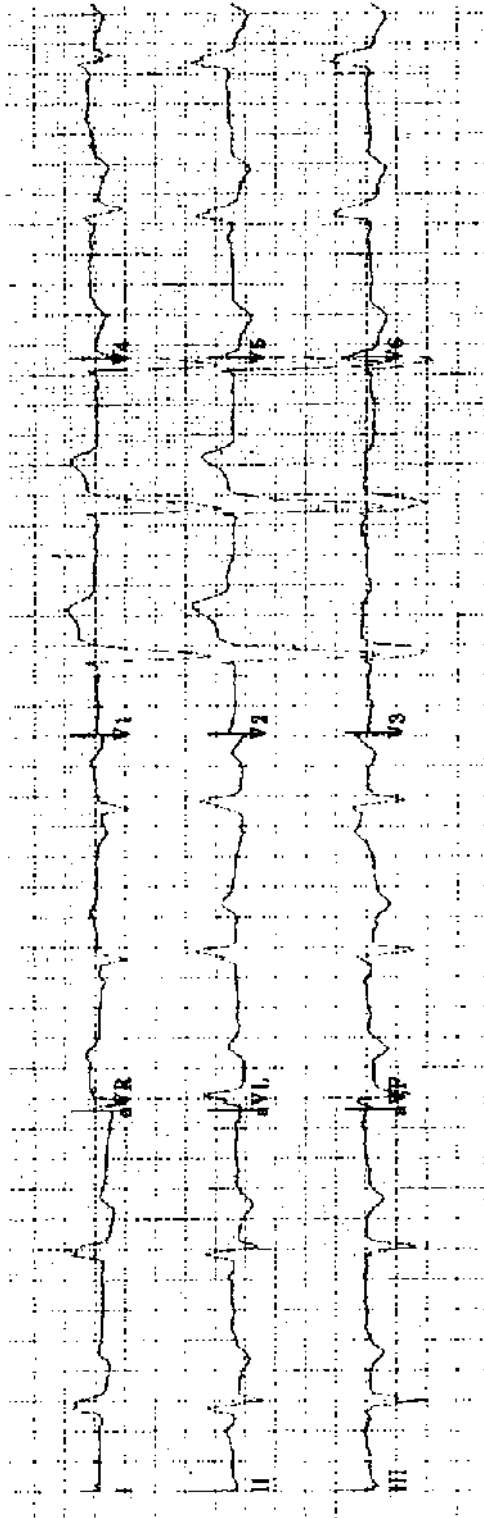
Practice ECG 107 A 53-year-old man had chest pain of 90 minutes duration earlier in the day. Should we consider thrombolytic therapy?



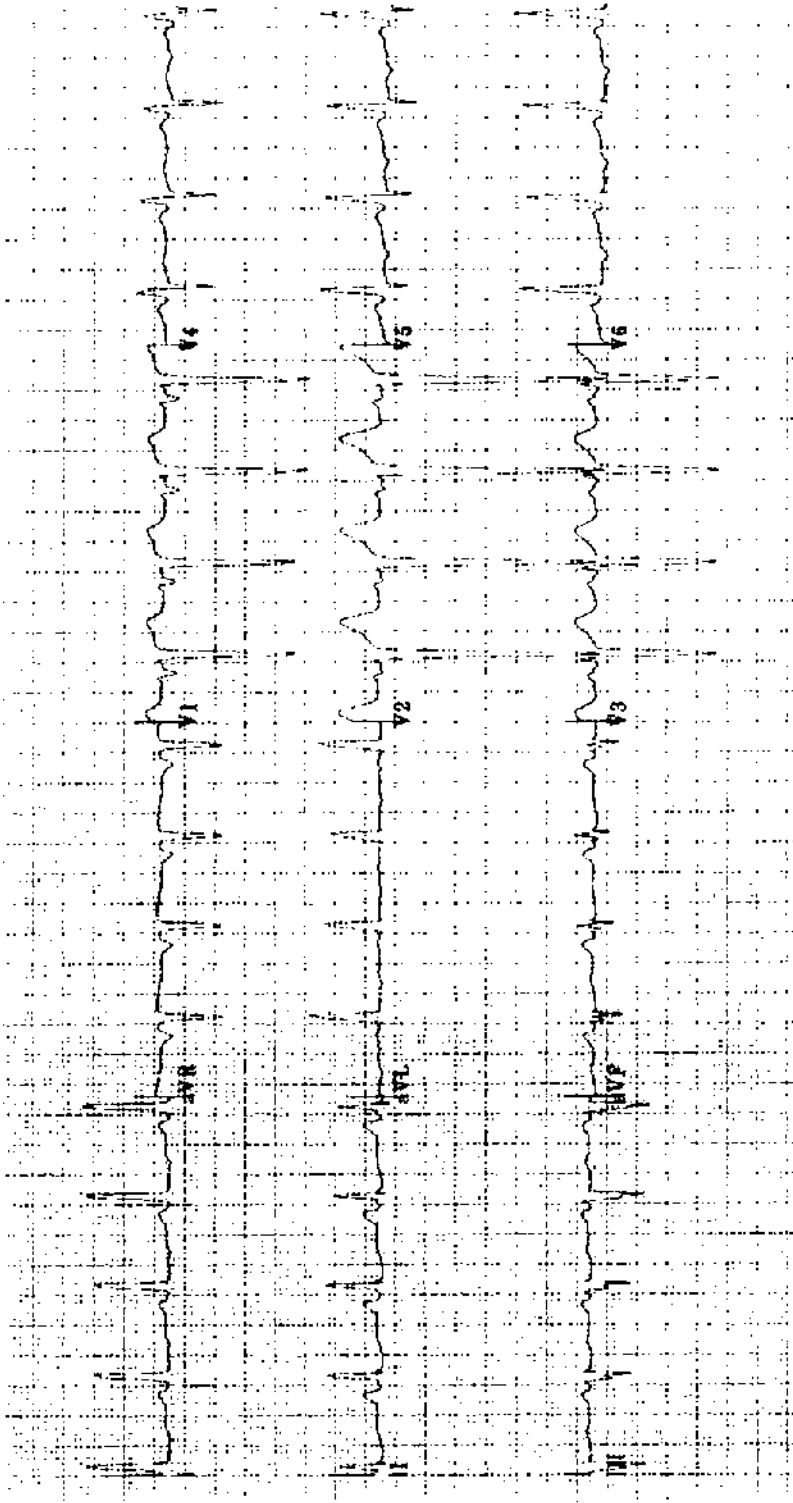
Practice ECG 108 A 70-year-old woman with chest pain of 5 hours duration. Should she have thrombolytic therapy?



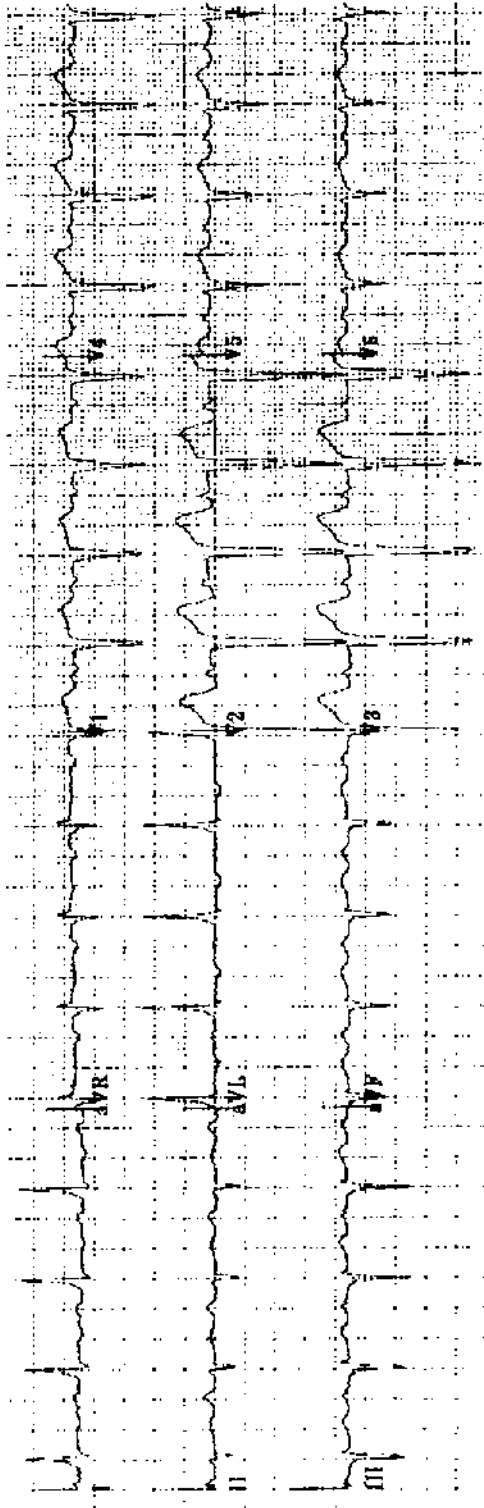
Practice ECG 110 A 70-year-old woman with chest pain of 2 hours duration. There is no old ECG for comparison. Should she have thrombolytic therapy?



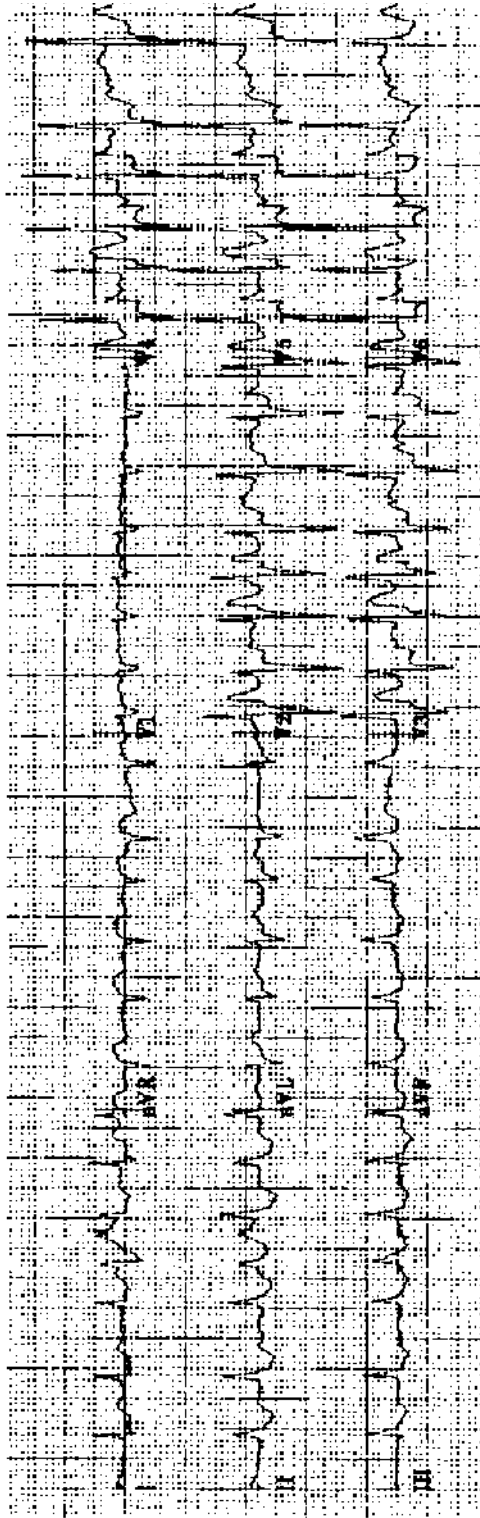
Practice ECG 111 Same patient (No. 110), 3 hours later.



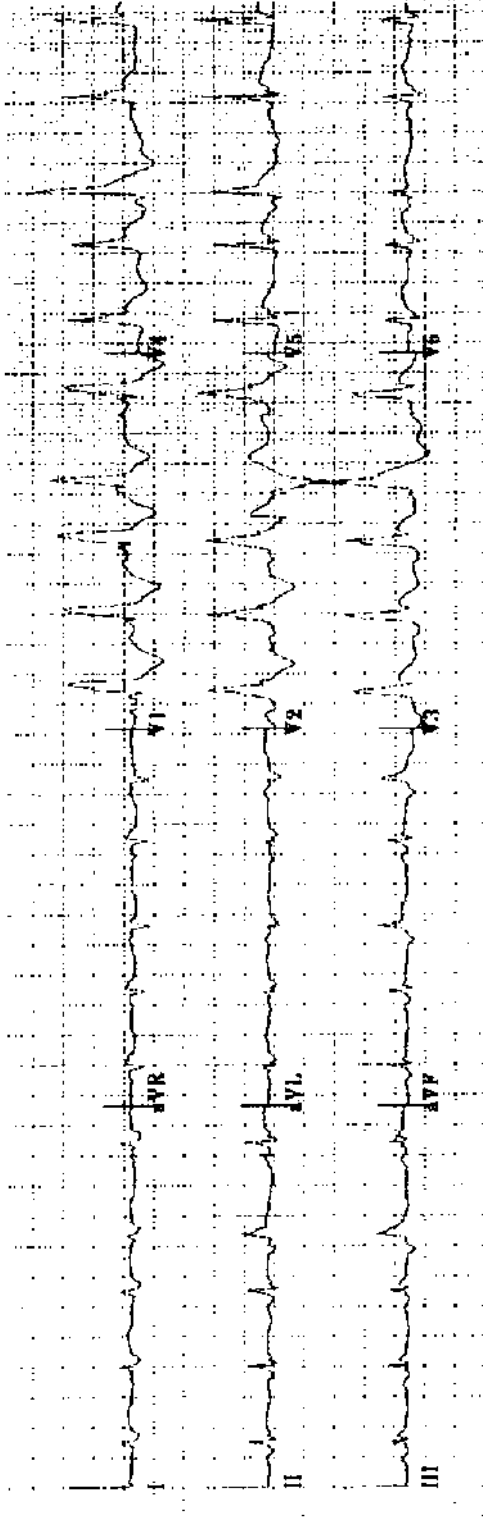
Practice ECG 112 A 46-year-old man with poorly controlled hypertension and renal failure.



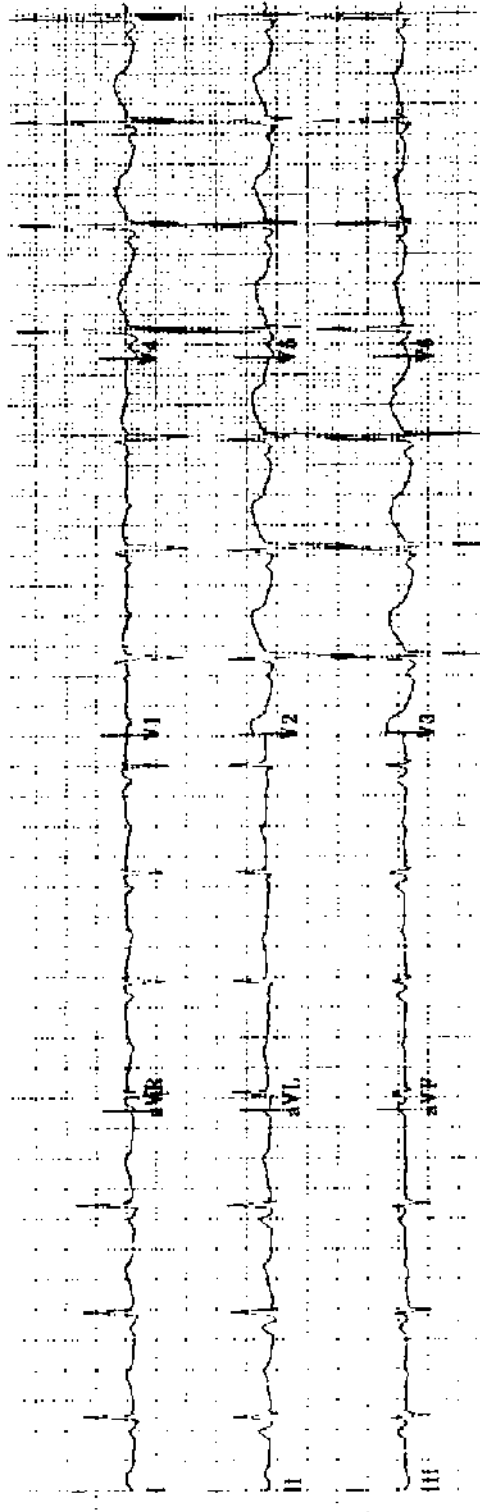
Practice ECG 113 A 43-year-old man referred for evaluation of heart failure.



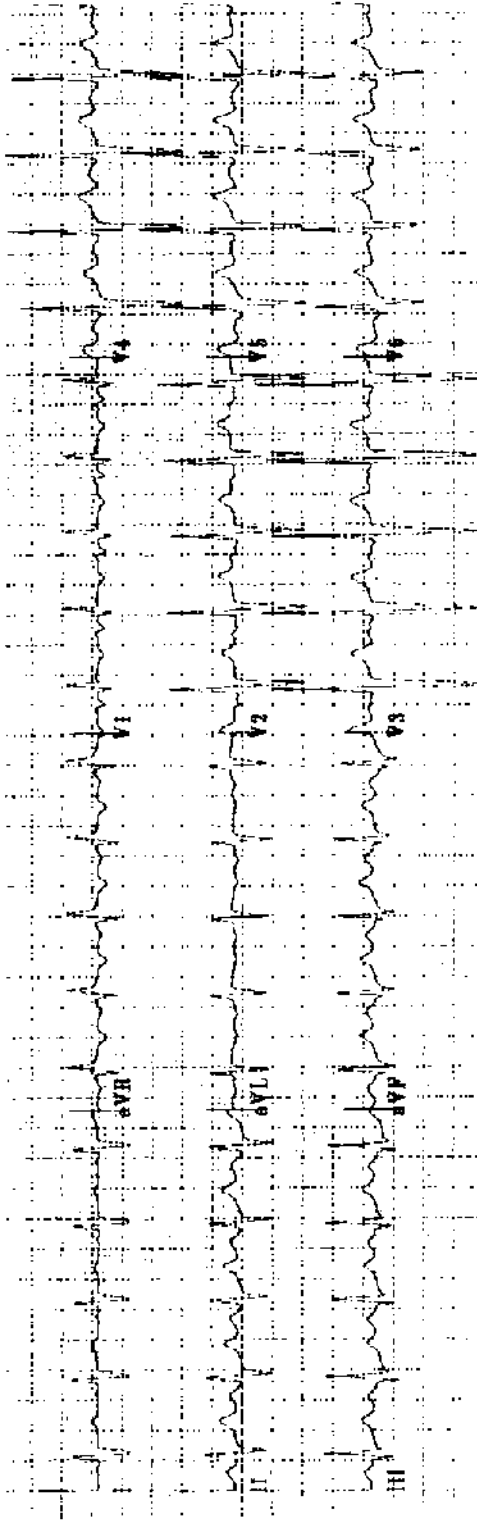
Practice ECG 114 A 52-year-old woman with palpitations. There is no other history of heart disease. This is her second episode. What workup is needed?



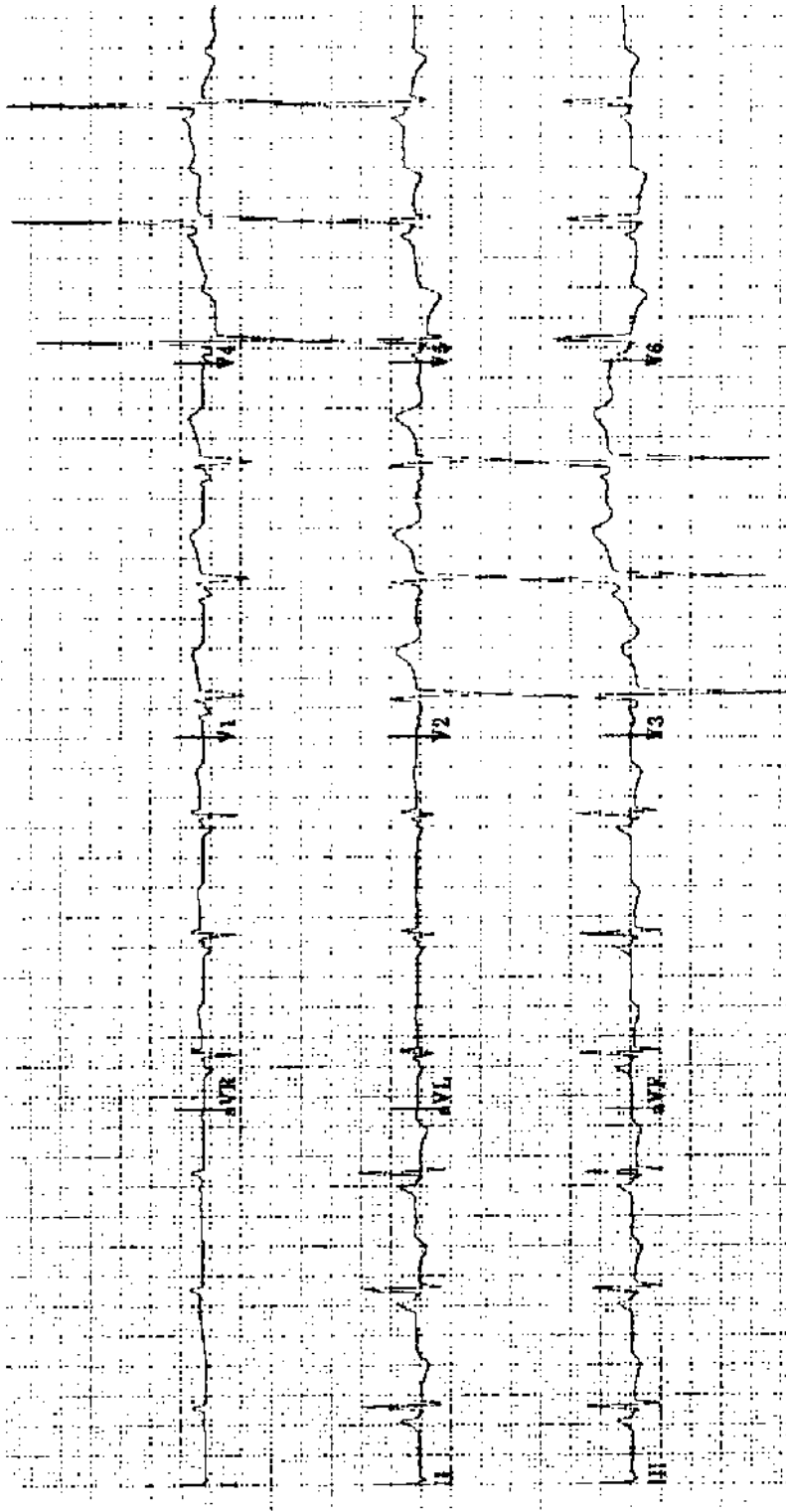
Practice ECG 115 A 78-year-old woman with chest heaviness of 5 hours duration and dyspnea. Would thrombolytic therapy influence survival?



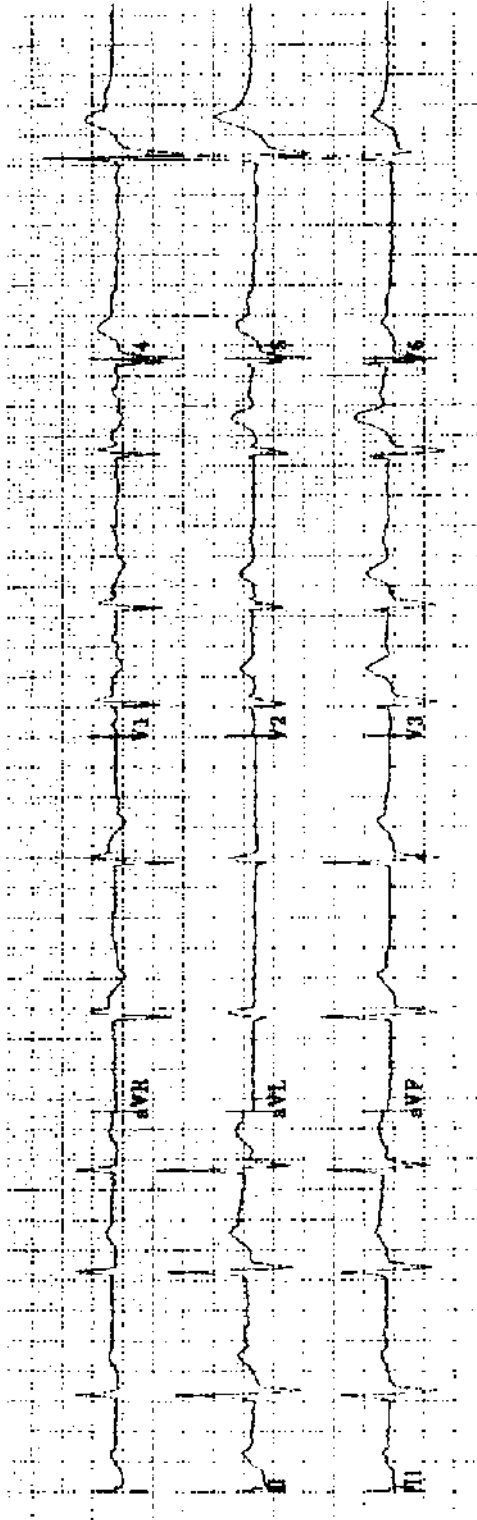
Practice ECG 116 A 41-year-old man on the psychiatric unit.



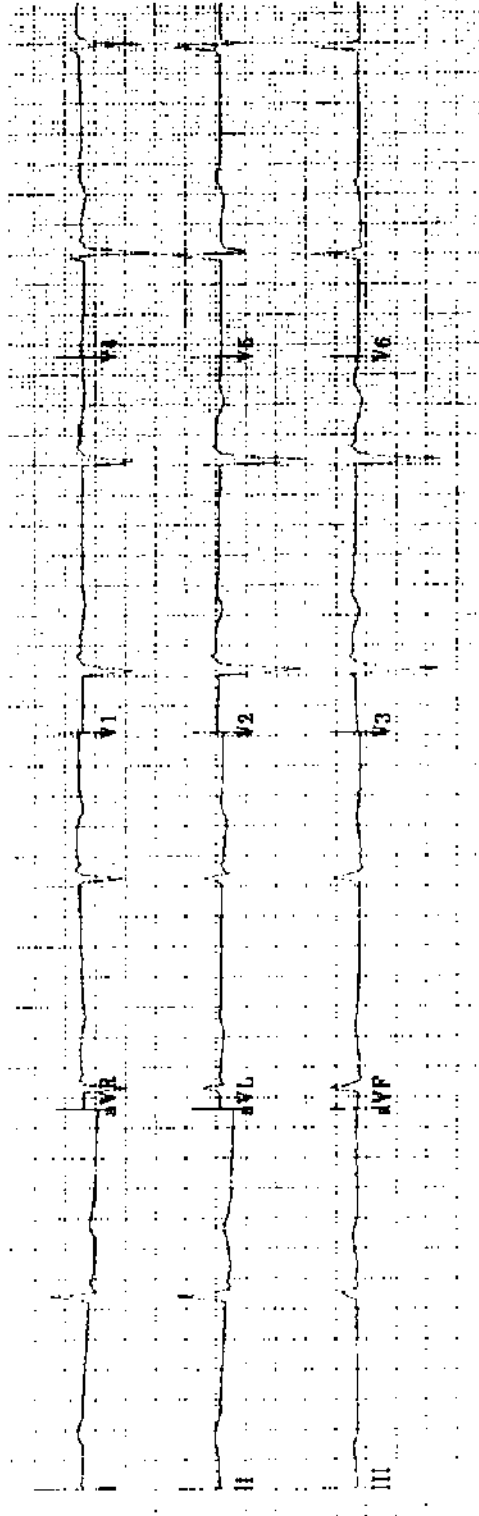
Practice ECG 117 A 19-year-old woman with cyanosis, lethargy, and a history of heart murmur. What other physical findings would you expect?



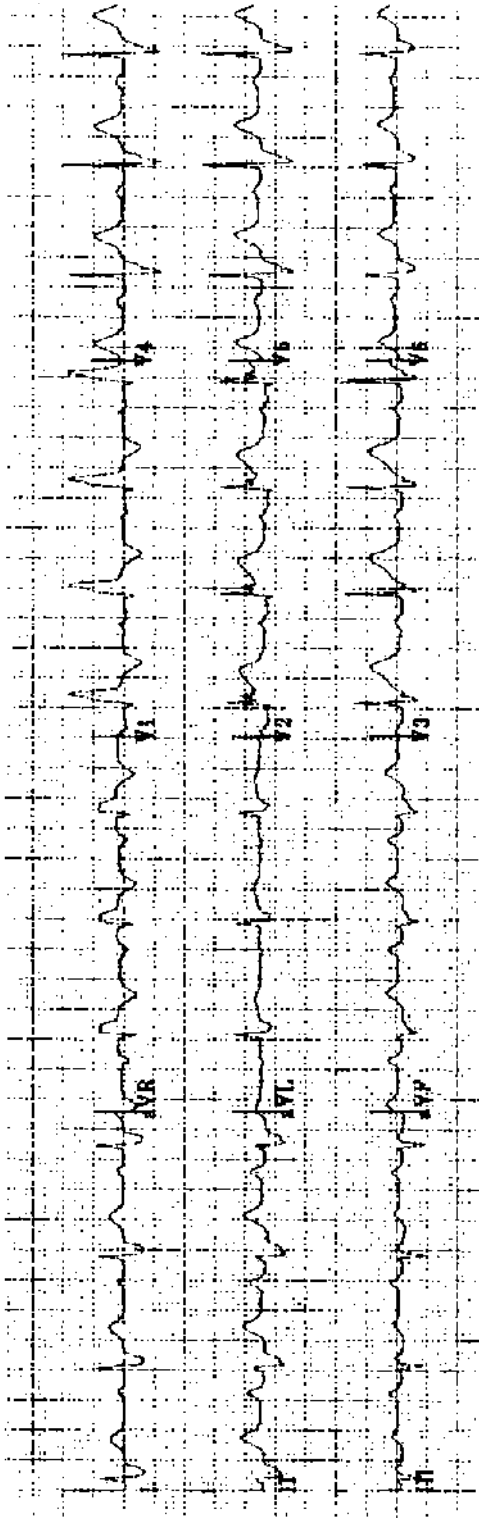
Practice ECG 118 A 73-year-old man with a systolic murmur that radiates to his neck.



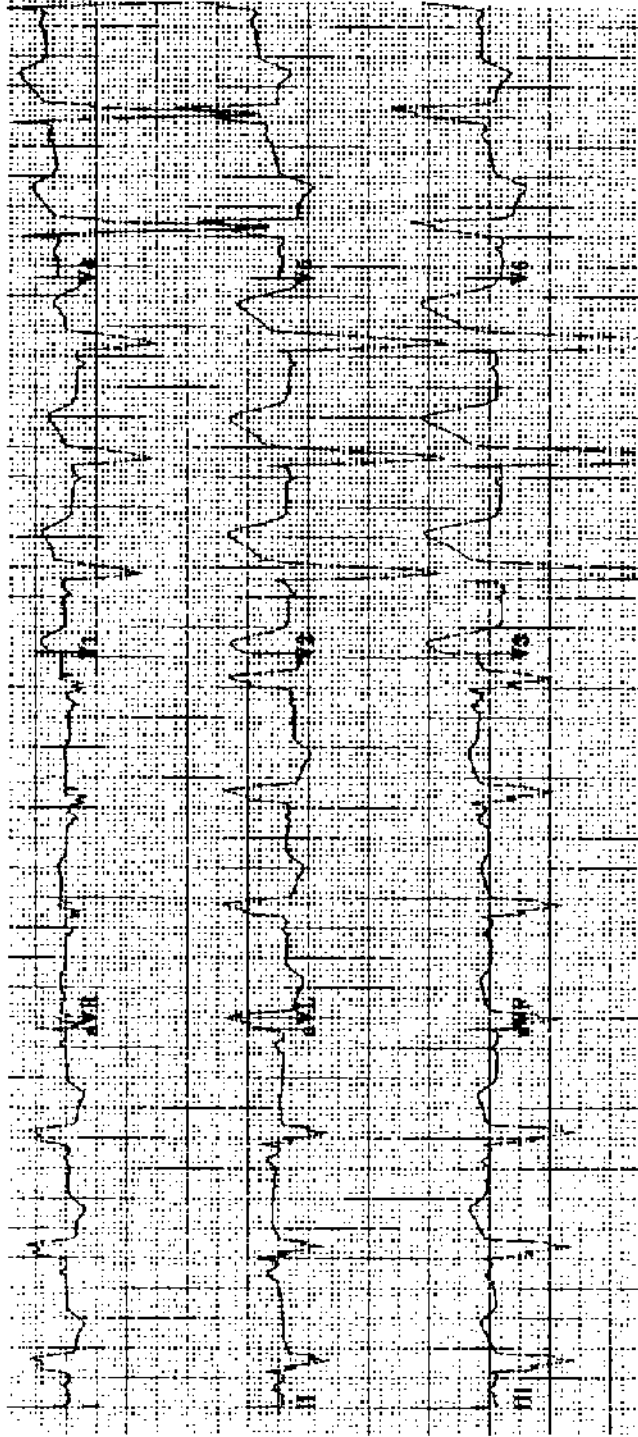
Practice ECG 119 A 28-year-old man with long fingers, high arched palate, and a diastolic murmur.



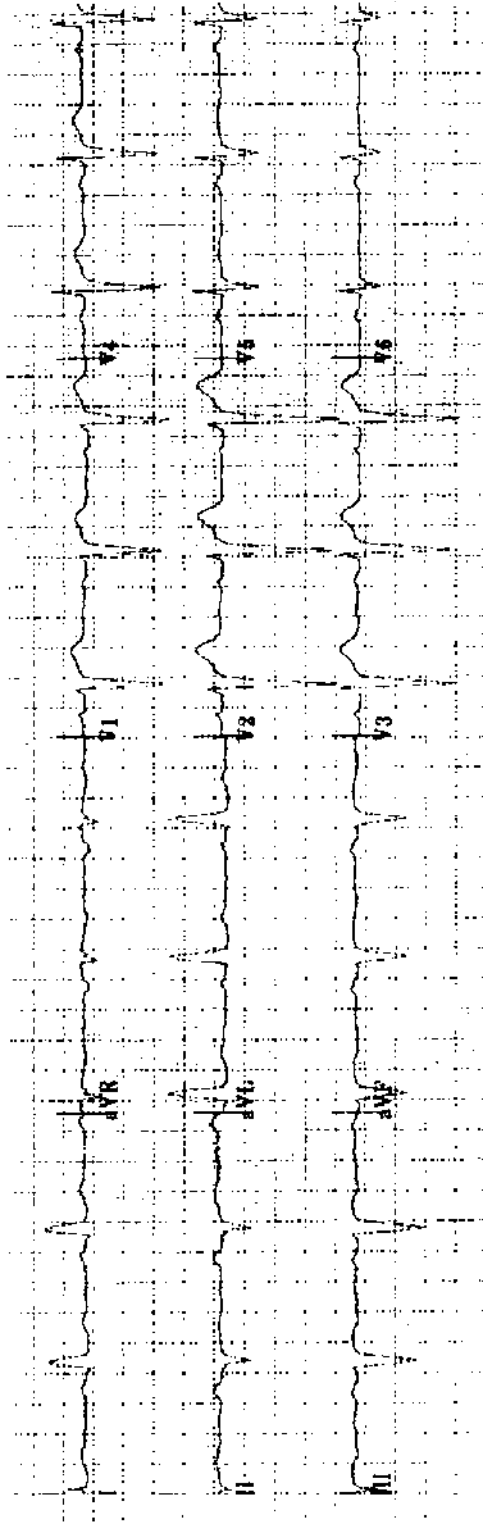
Practice ECG 120 A 51-year-old man with a history of MI.



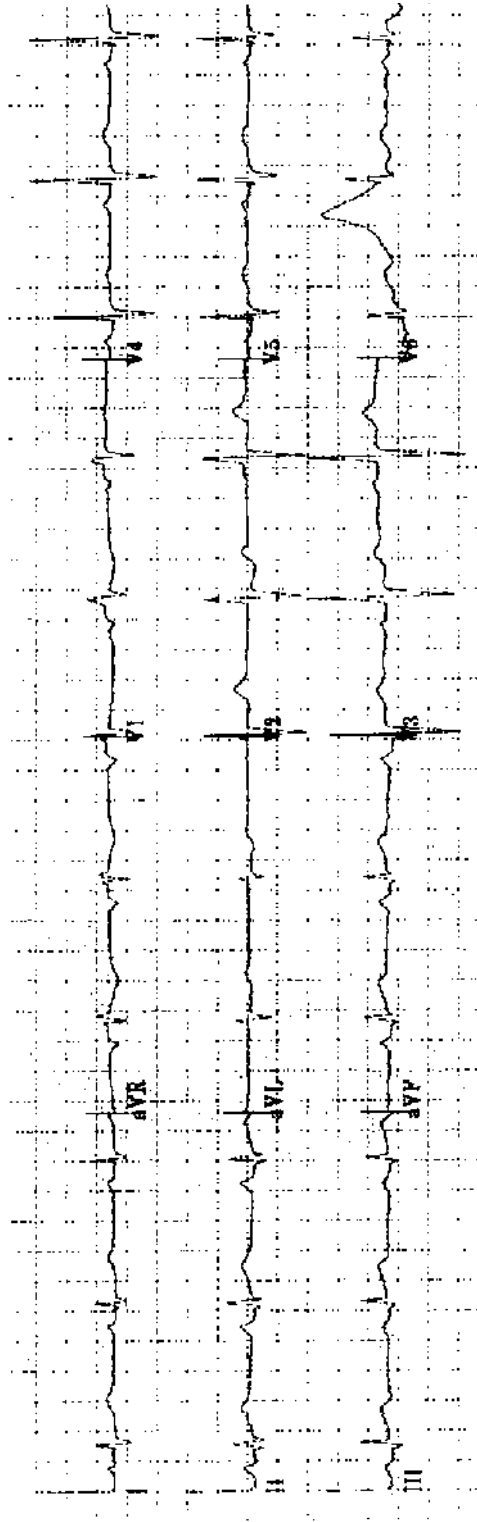
Practice ECG 121 A 68-year-old man roused from sleep by chest pain 6 hours earlier; antacids did not help. Although the pain is severe, is it too late for reperfusion therapy?



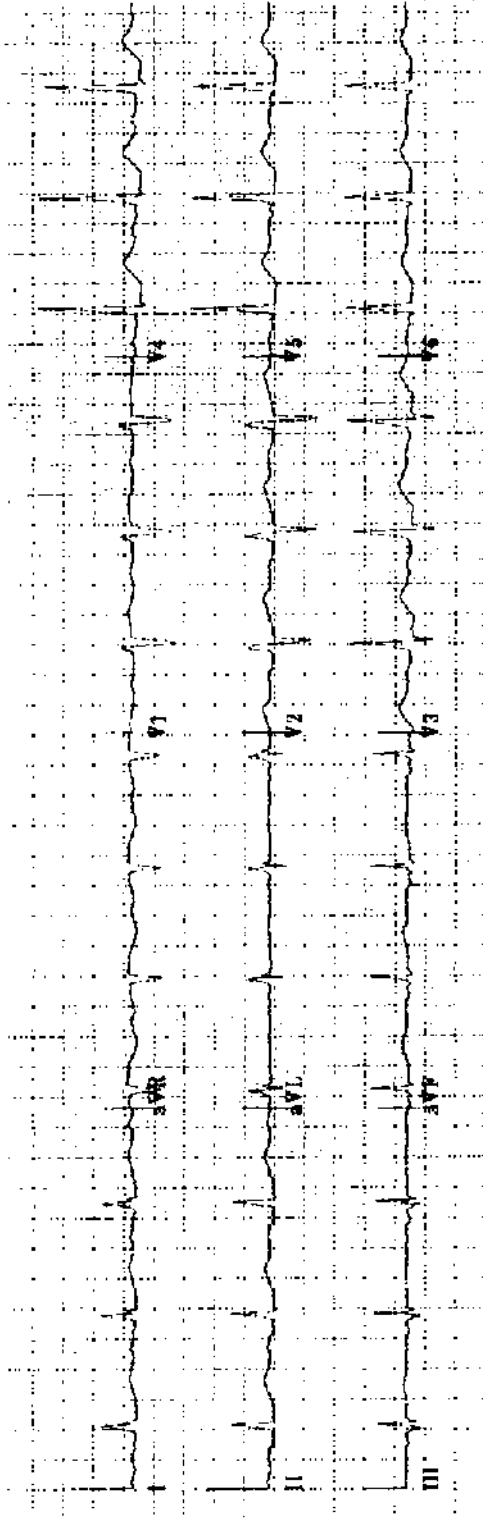
Practice ECG 122 A 67-year-old woman with a history of hypertension. Is there hypertensive heart disease?



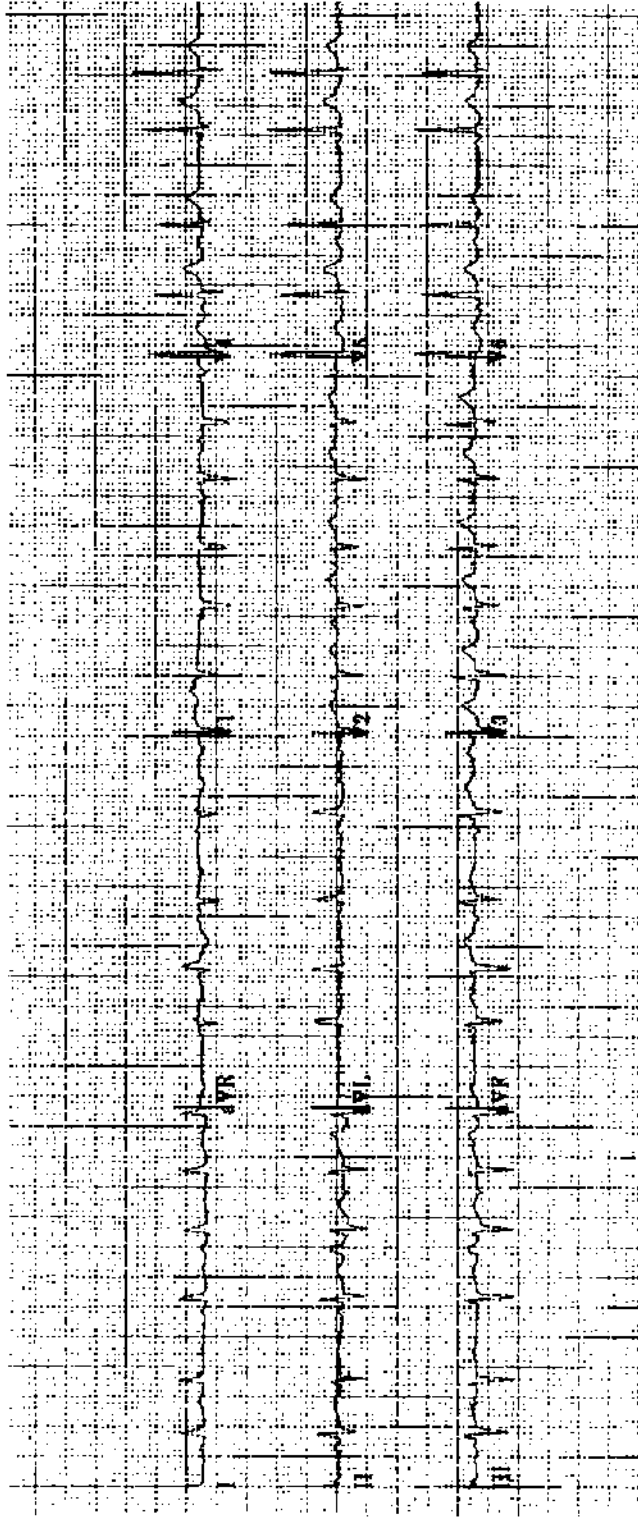
Practice ECG 123 A 56-year-old man referred because of silent MI.



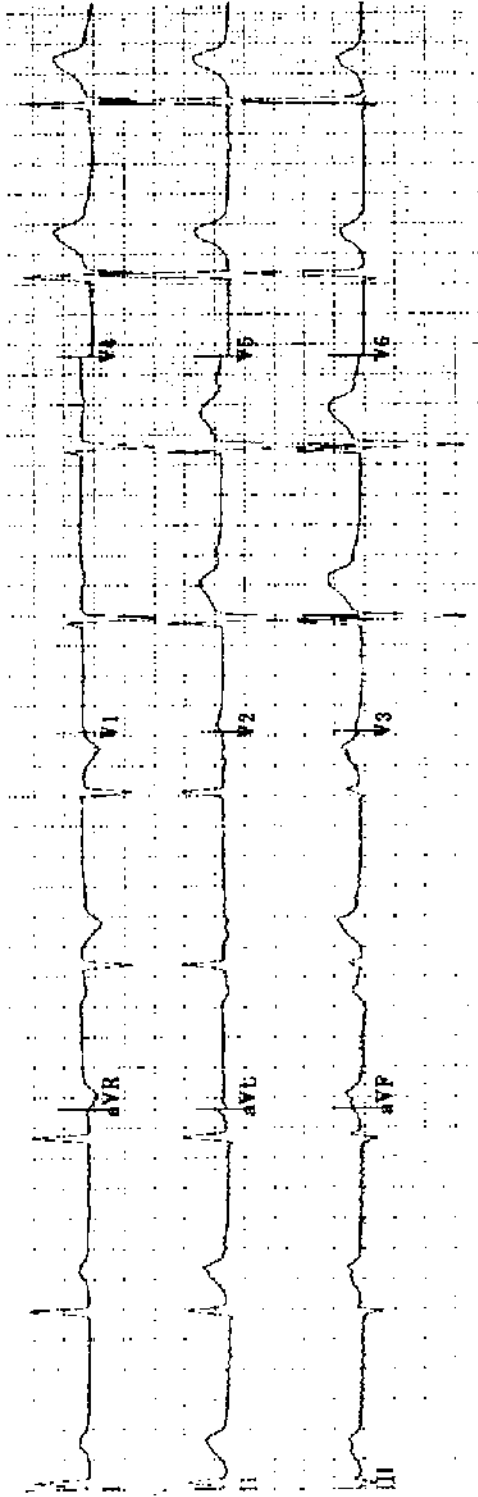
Practice ECG 124 An 82-year-old woman in good health until the onset of chest pain 2 hours earlier. Should she have thrombolytic therapy?



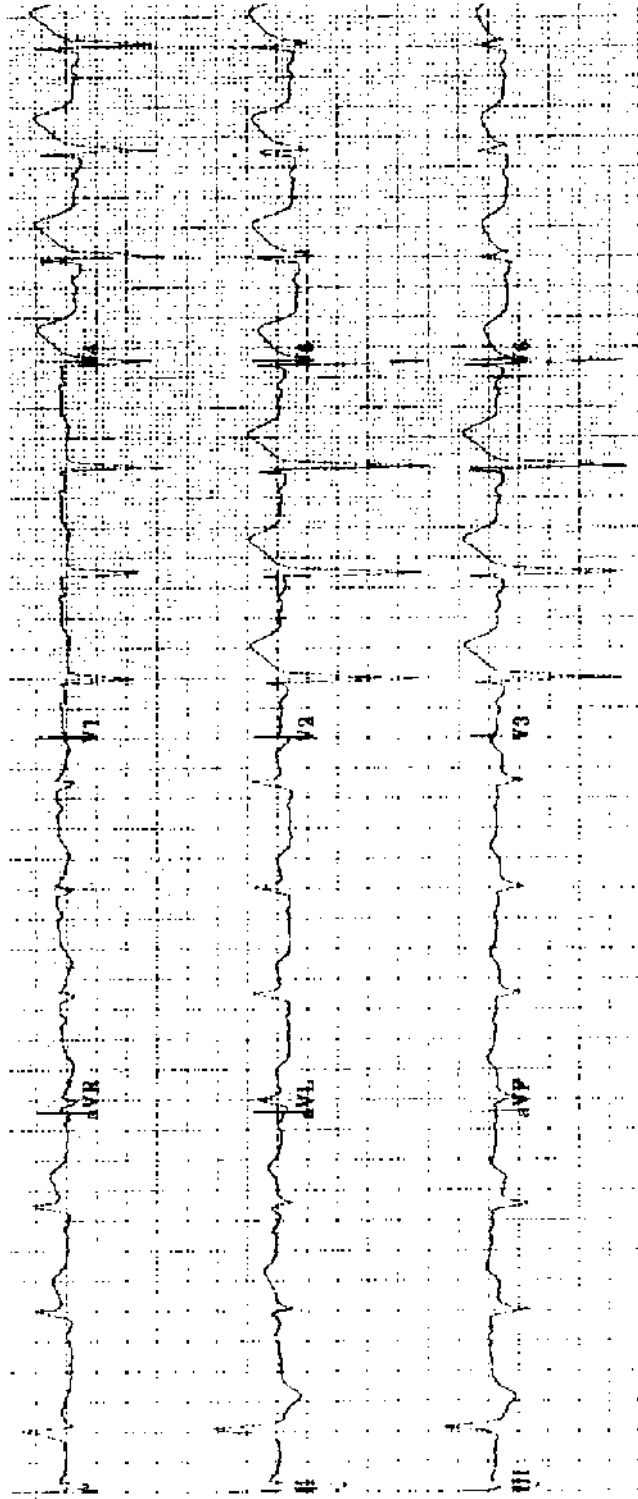
Practice ECG 125 A 51-year-old woman with hypertension and paroxysmal atrial fibrillation. Which medicines is she taking?



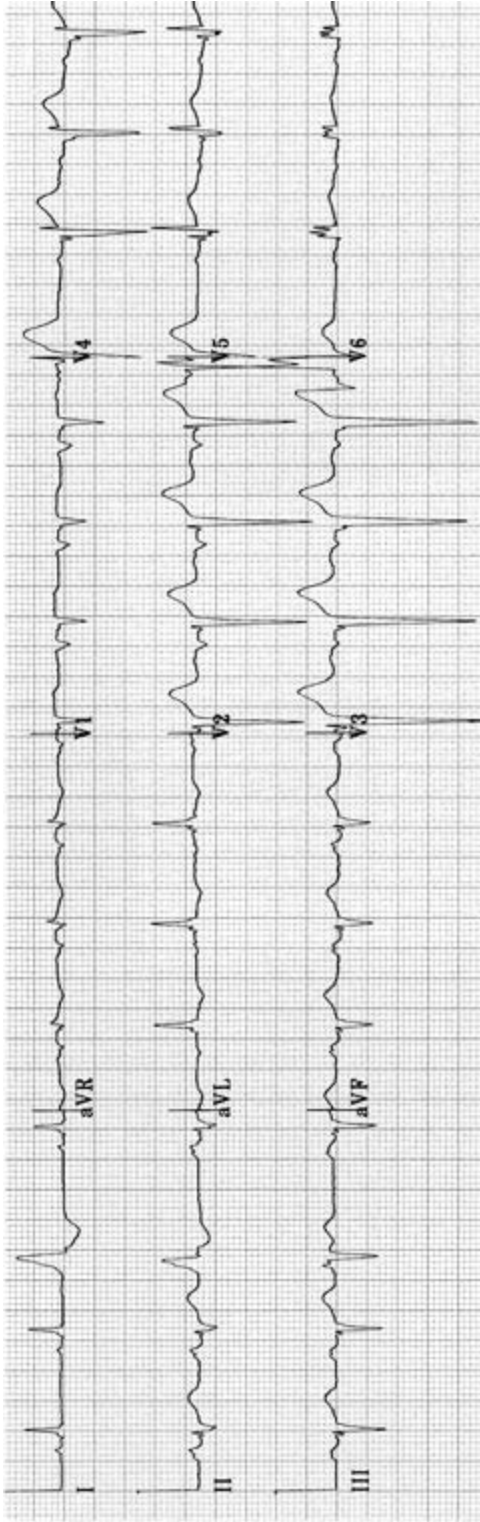
Practice ECG 126 A 76-year-old man who is a patient in the pulmonary unit. Which medicines could be used to control the heart rate?



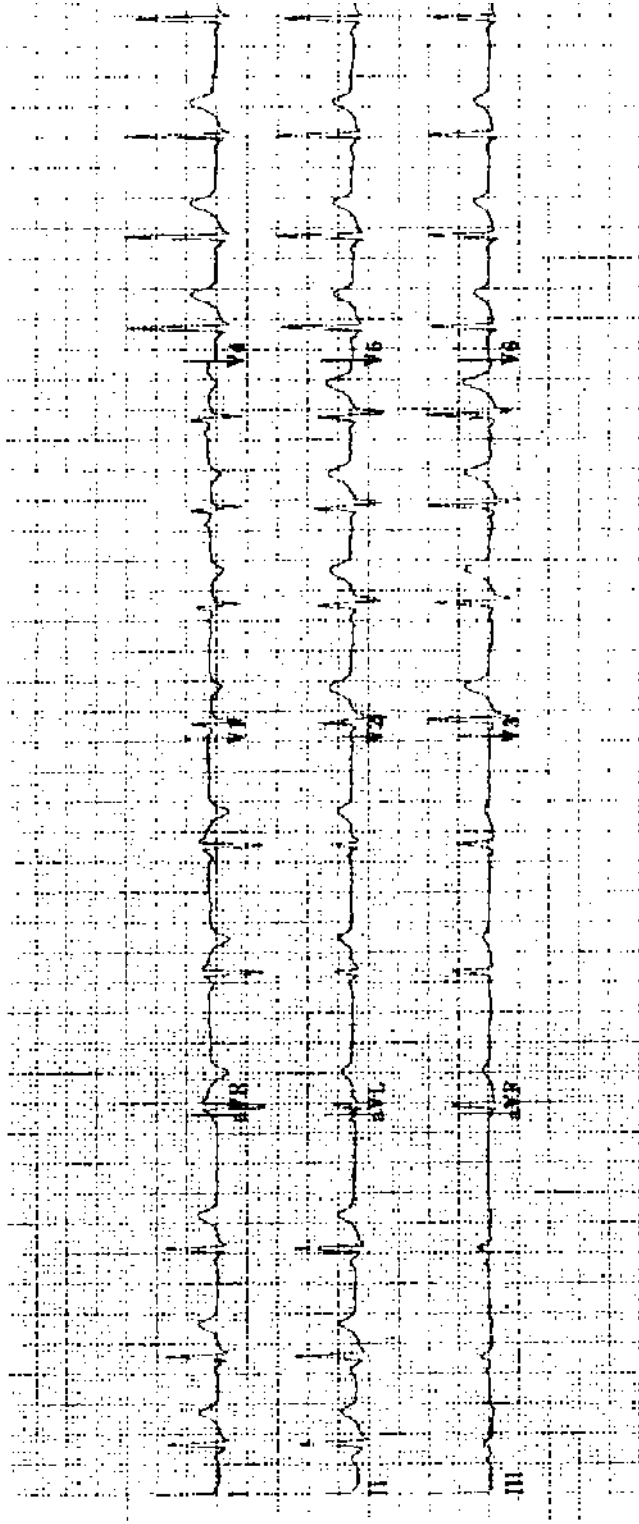
Practice ECG 127 A 35-year-old man on the day after coronary bypass surgery.




Practice ECG 128 A 72-year-old woman with vague, nonspecific chest pain unresponsive to antacids.



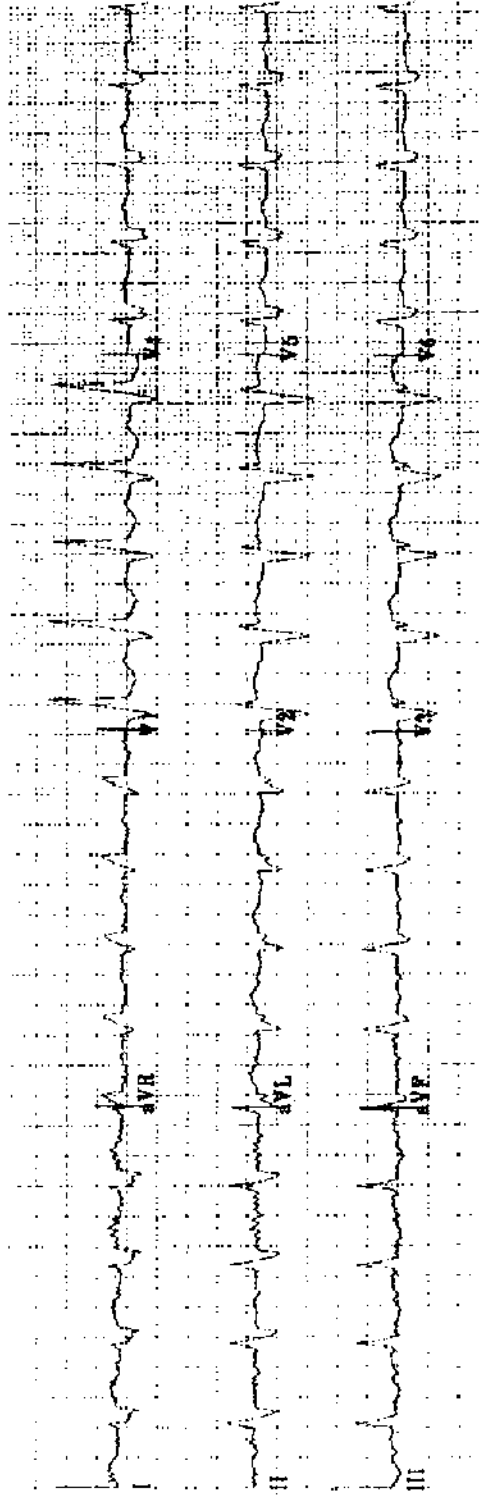
Practice ECG 129 A 77-year-old man with a history of MI and congestive heart failure.




Practice ECG 130 A 23-year-old woman with irregular pulse. Must we be concerned by this arrhythmia?



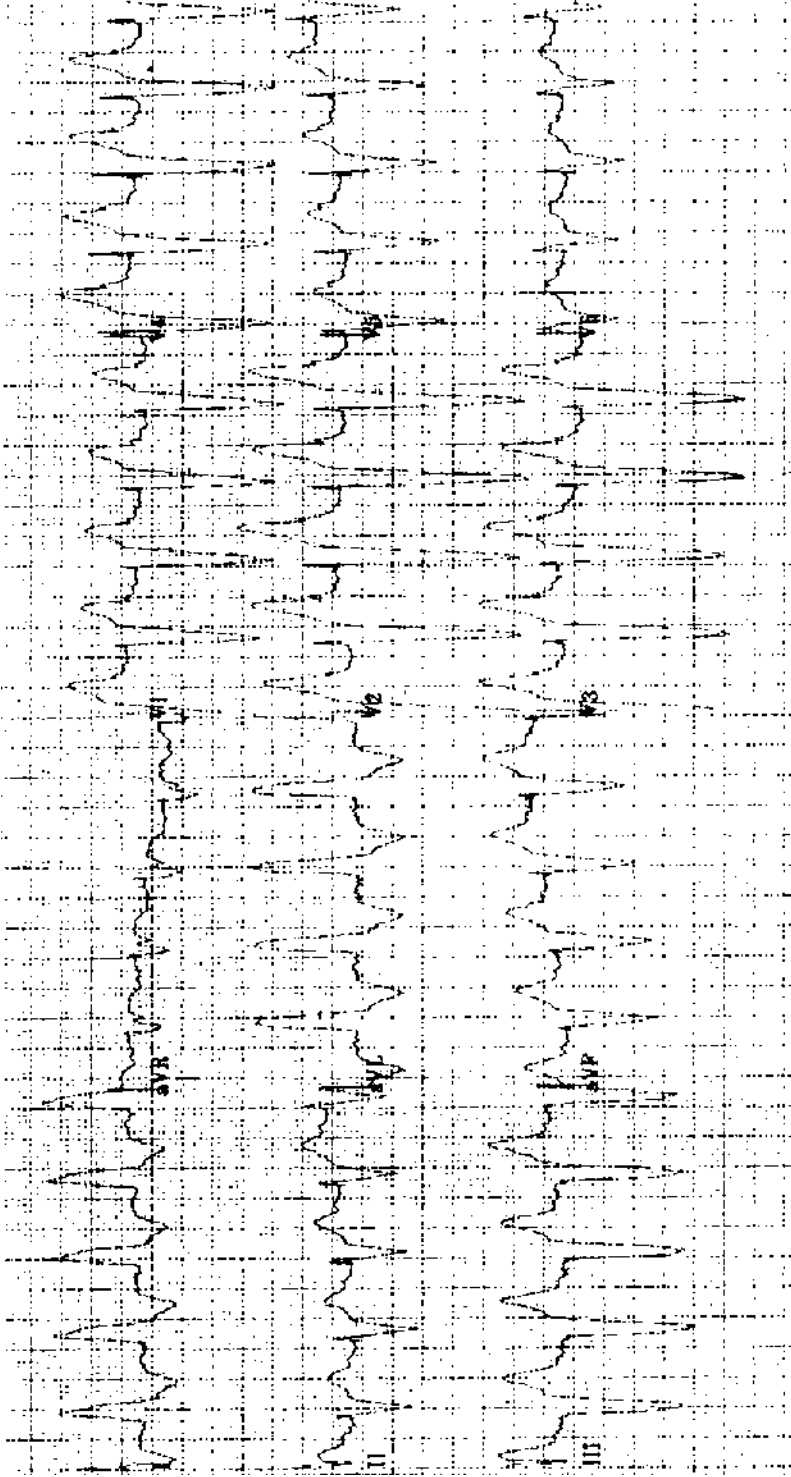
Practice ECG 131 A 73-year-old man with chest pain. Should he have thrombolytic therapy? What other tests would you recommend?



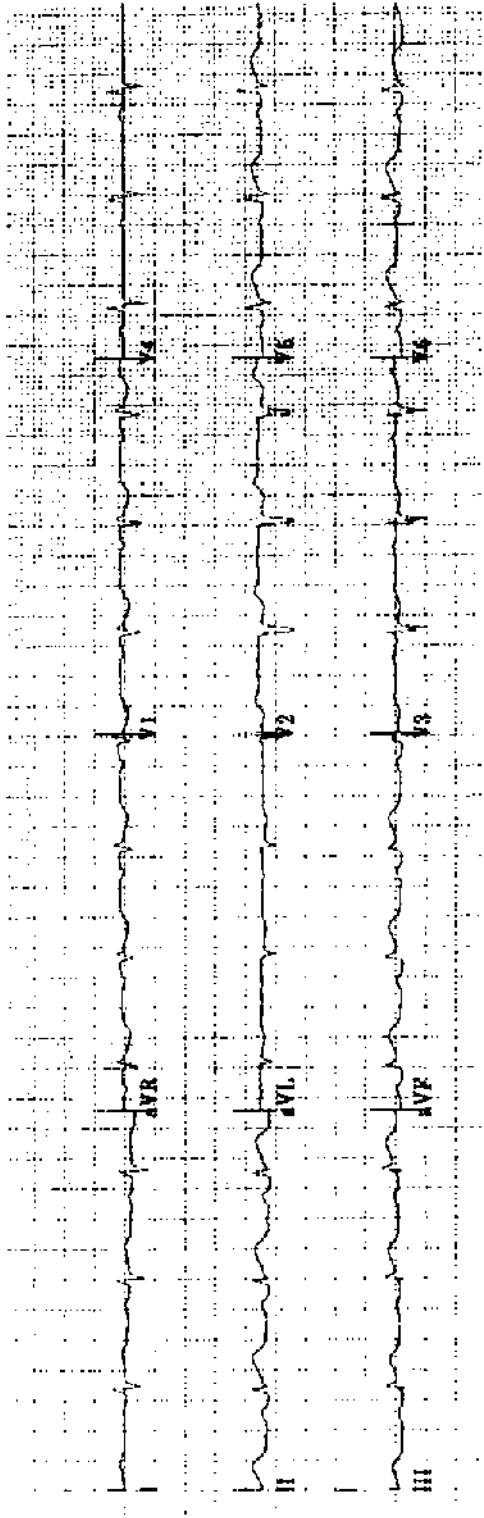
Practice ECG 132 A 52-year-old man with history of MI. Do the ECG findings indicate prognosis?



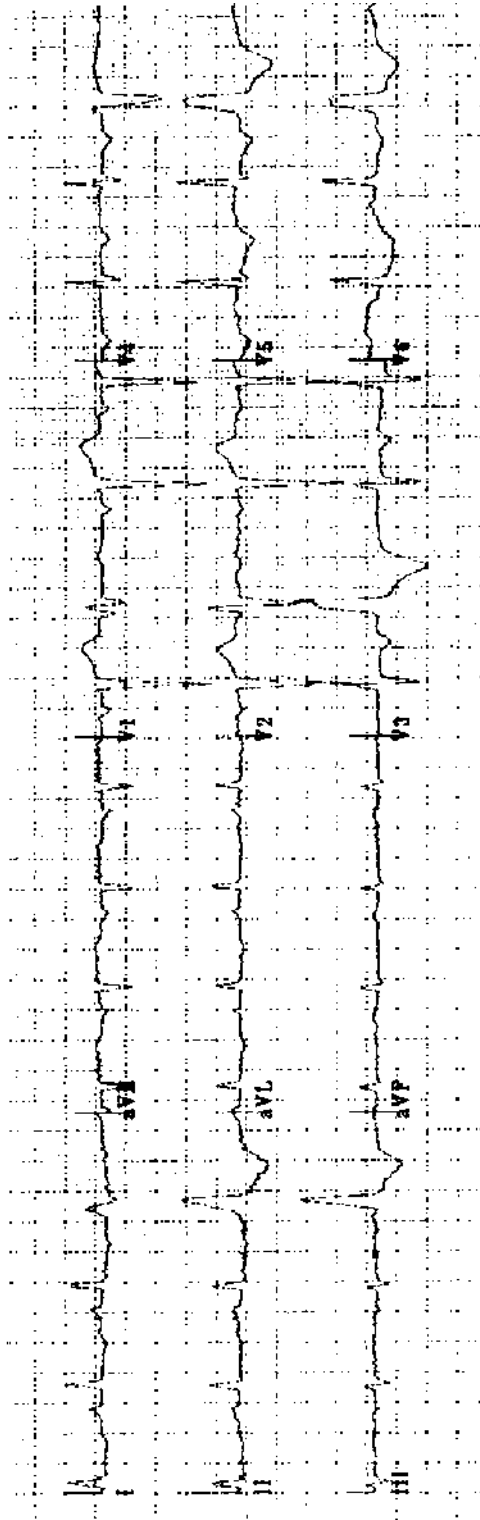
Practice ECG 133 A 55-year-old woman with confusion, lethargy, and difficulty speaking.



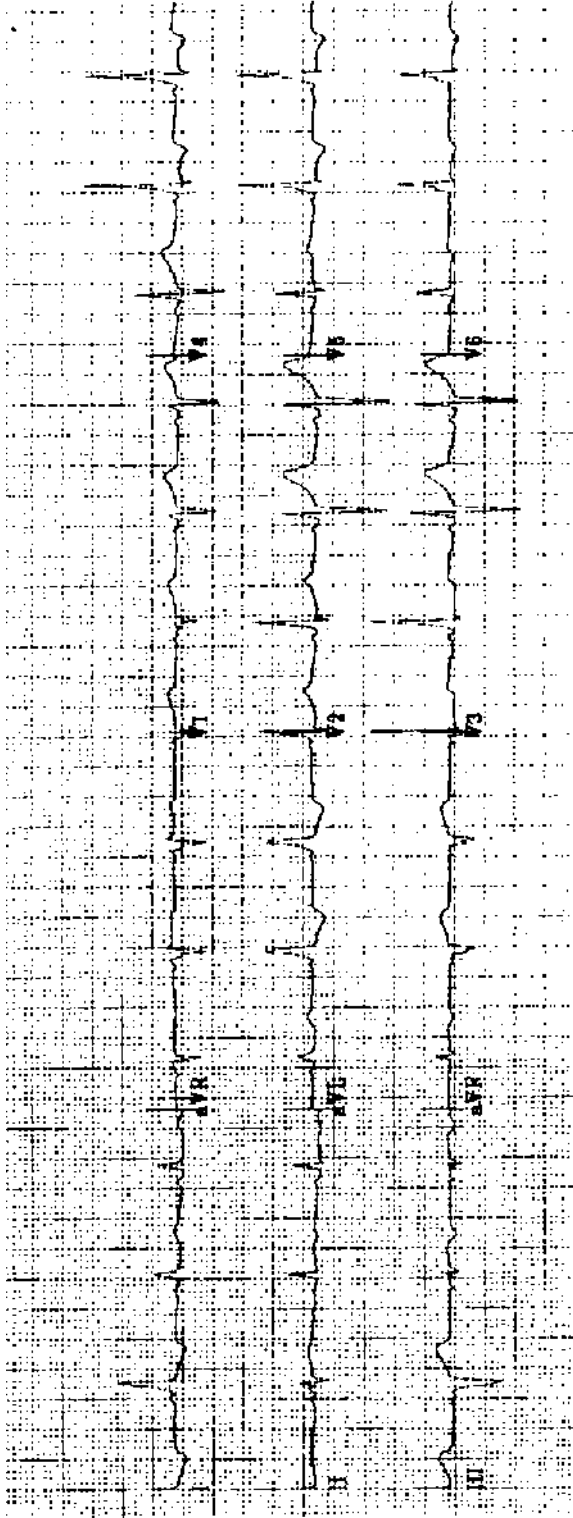
Practice ECG 134 An 83-year-old woman with heart failure.



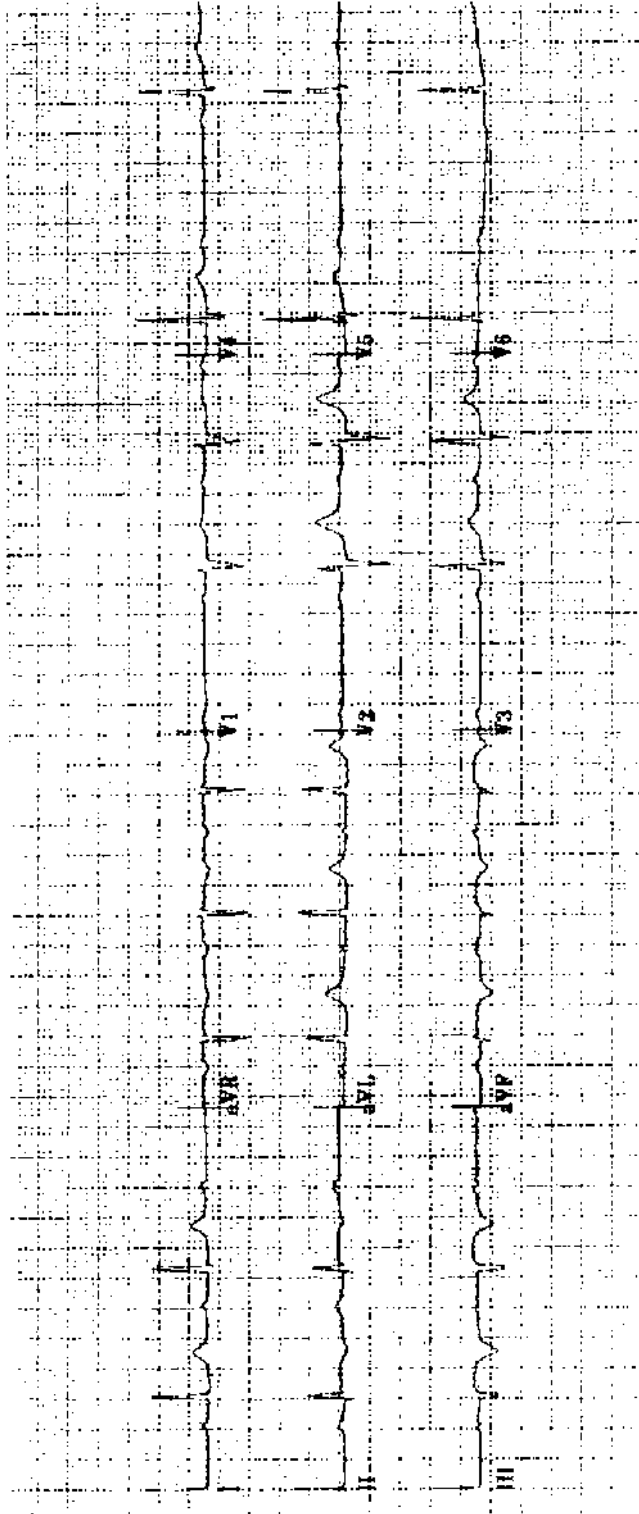
Practice ECG 135 A 54-year-old man with 2 hours of chest pain he thought was pleurisy. He has had the flu.



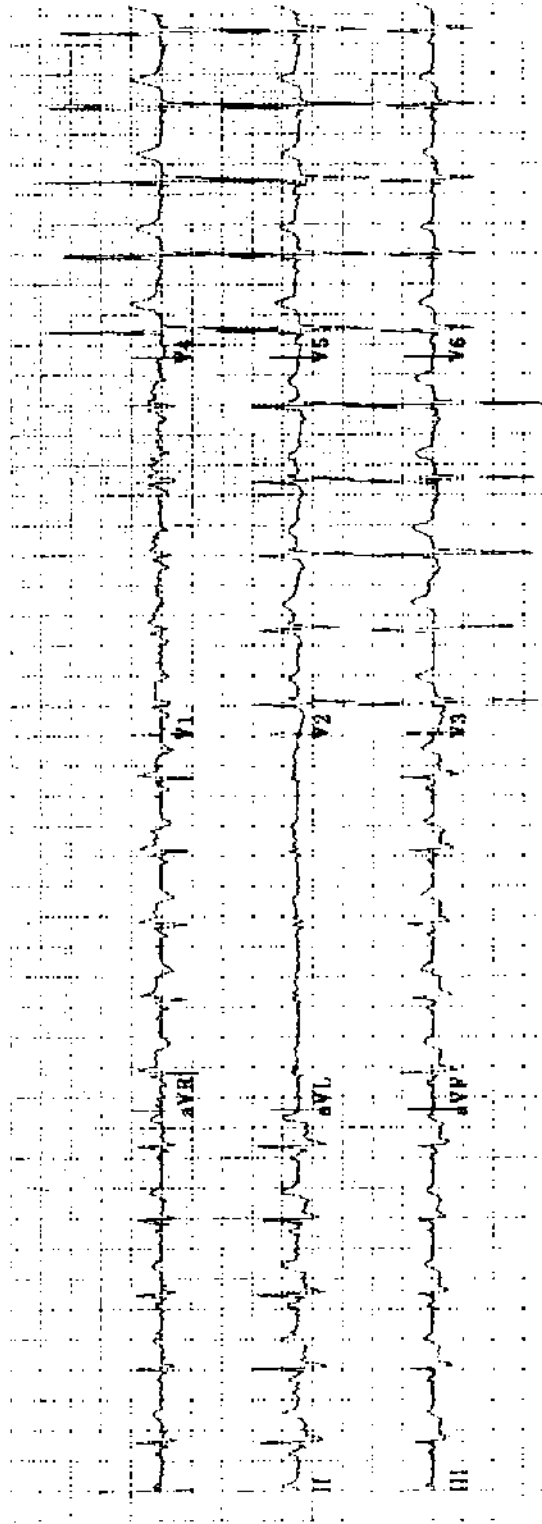
Practice ECG 136 A 78-year-old man in the emergency room with pulmonary edema and chest pain (during this ECG recording).



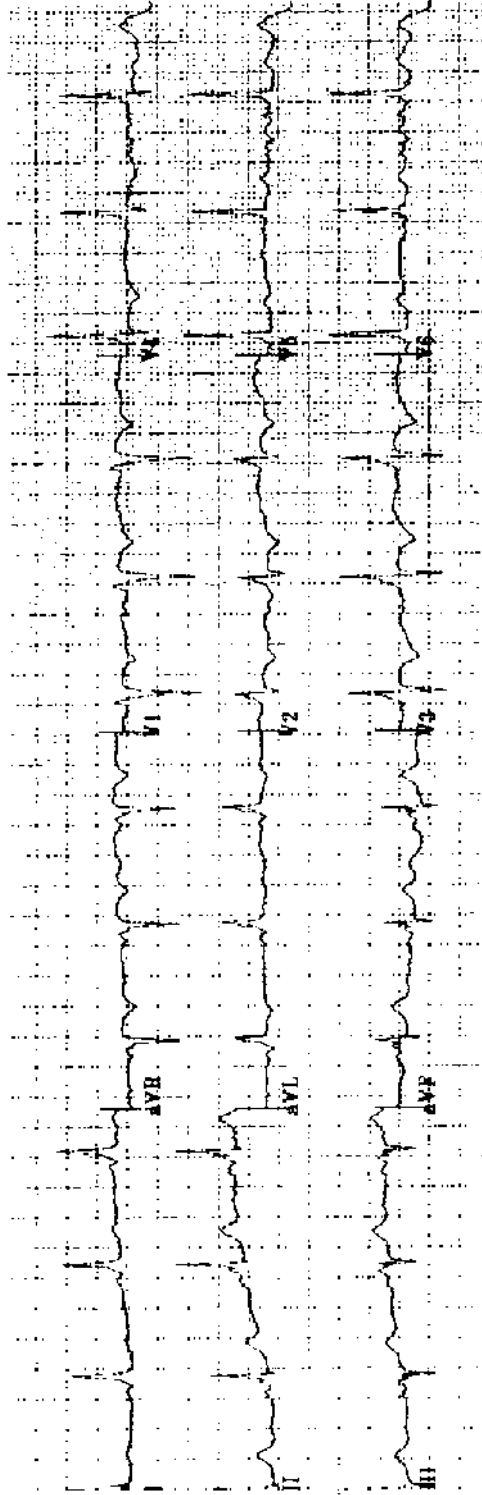
Practice ECG 137 A 54-year-old woman with a long history of palpitations; yearly examination.



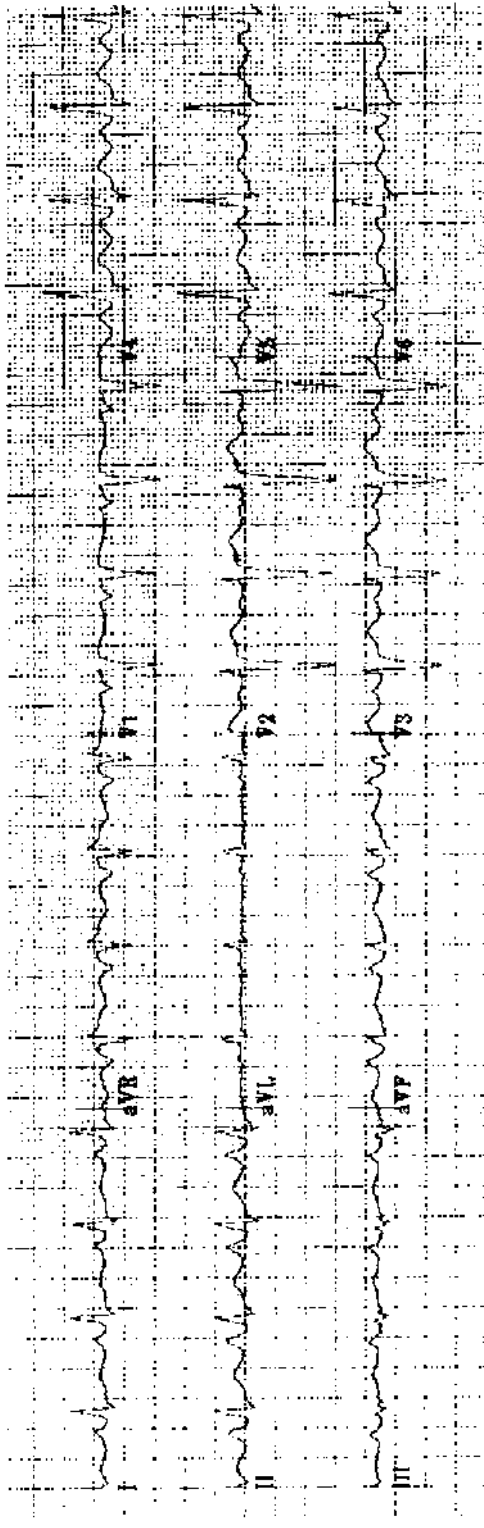
Practice ECG 138 A 48-year-old man admitted 2 days earlier with chest pain that resolved 14 hours later.



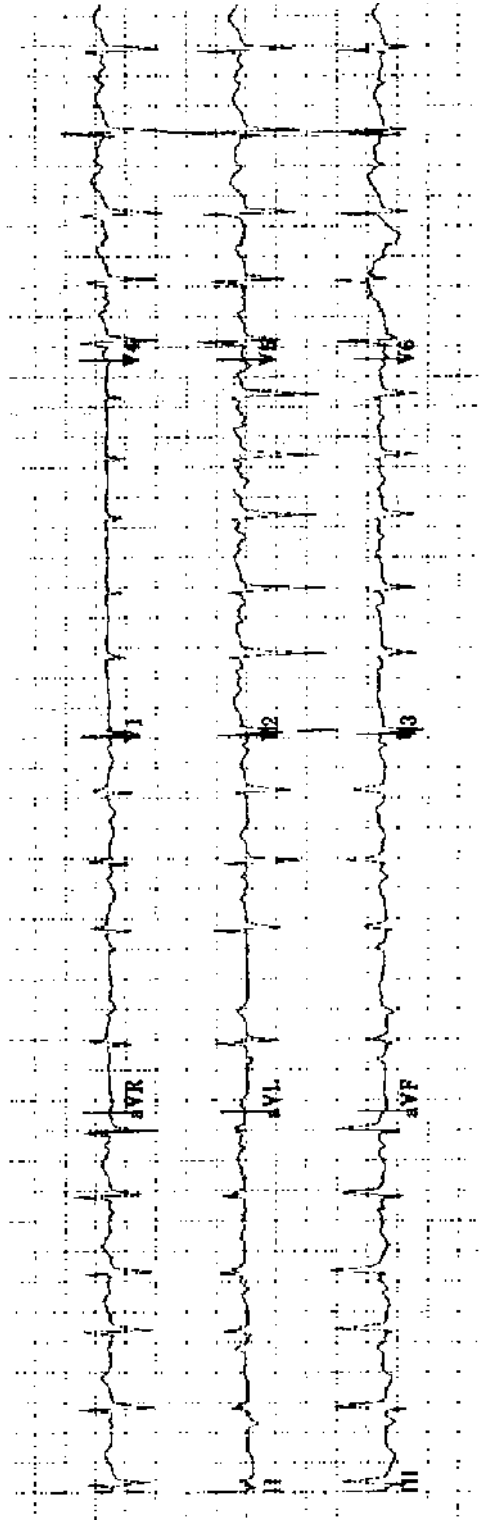
Practice ECG 139 A 66-year-old man with a history of palpitations. He was admitted with pneumonia and fever.



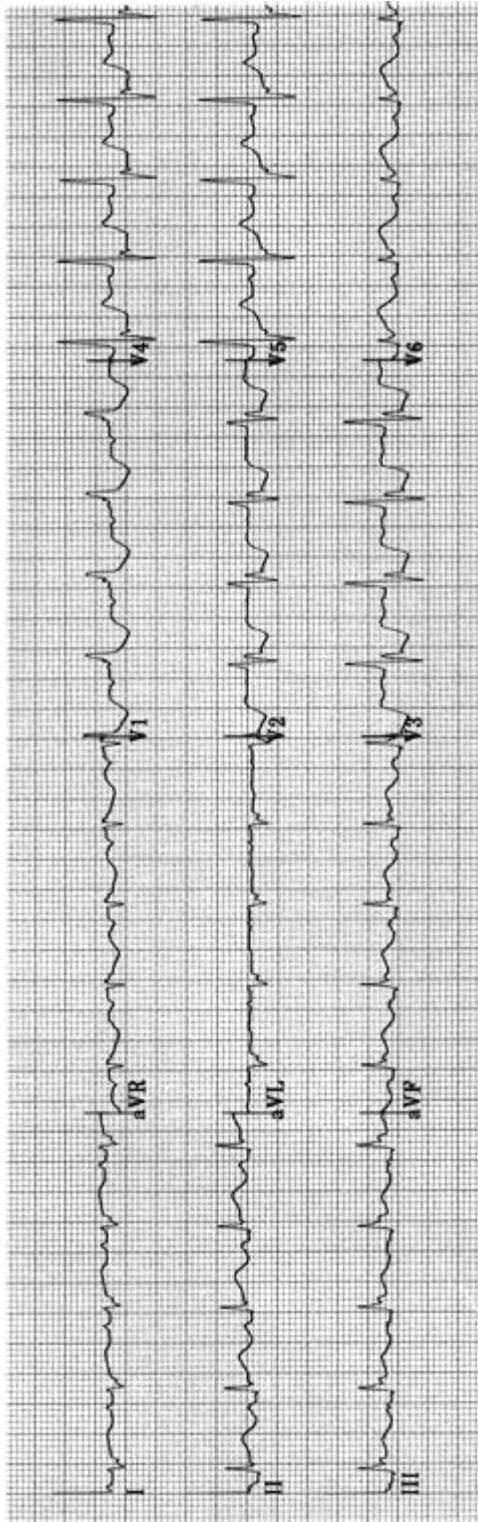
Practice ECG 140 Same patient (No. 139); the pneumonia is being treated and he is afebrile.



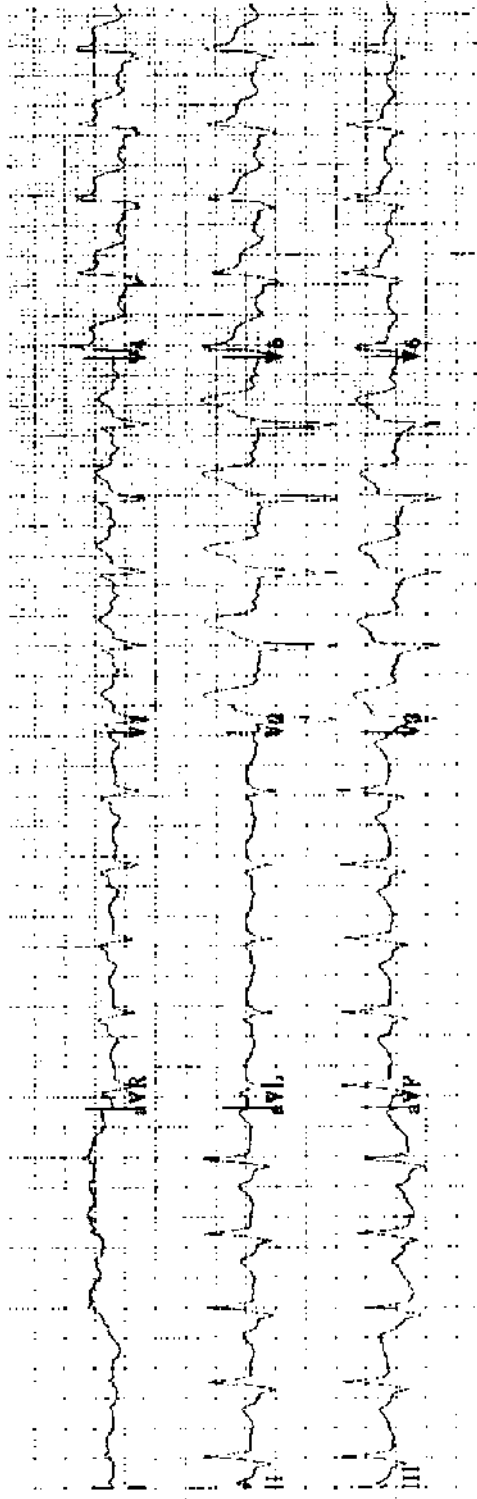
Practice ECG 141 A 53-year-old woman with a history of hypertension and smoking.




Practice ECG 142 A 72-year-old woman with fever and exacerbation of chronic bronchitis.



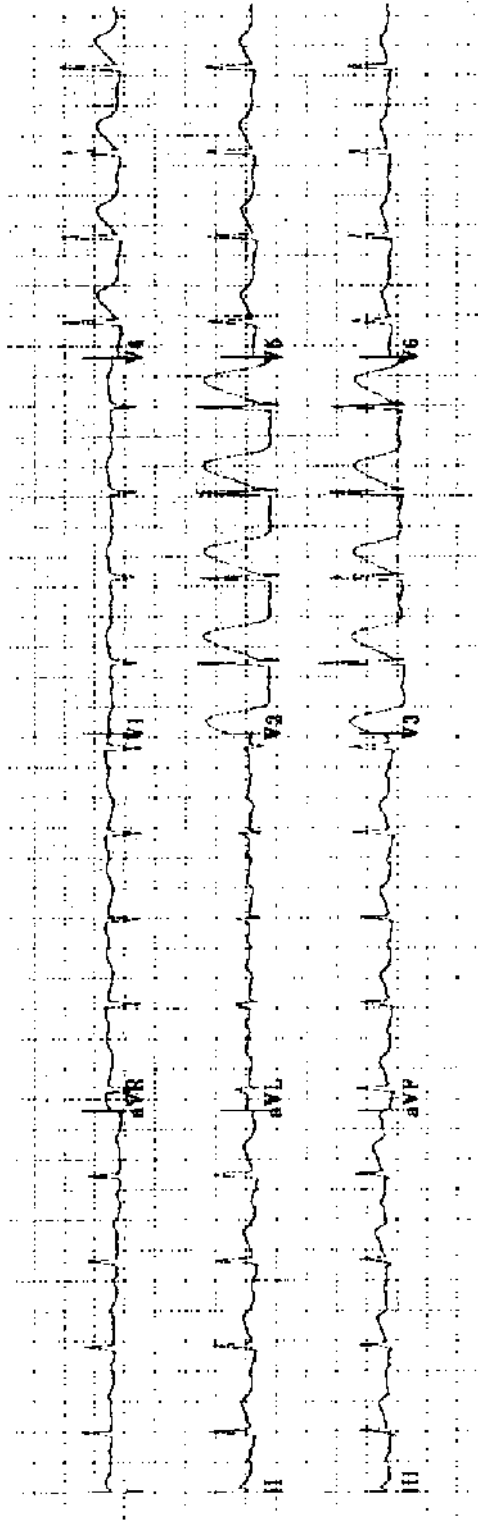
Practice ECG 143 A 72-year-old man with chest pain of 6 hours duration. Is there anterior ischemia?



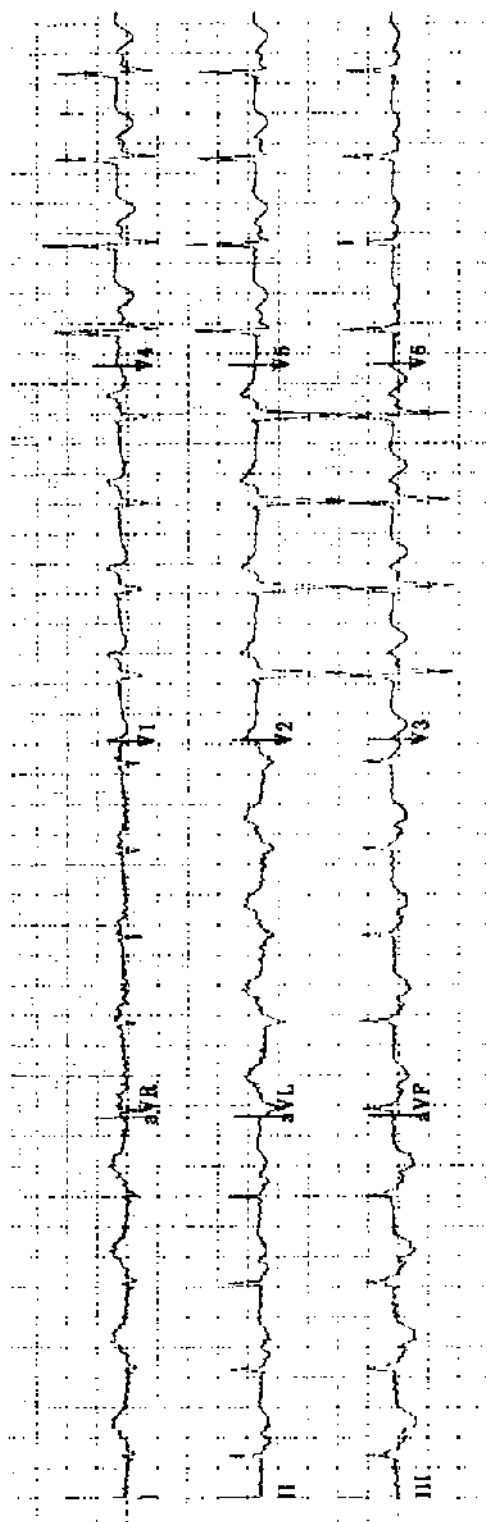
Practice ECG 144 A 59-year-old man in the emergency room with rales, chest pain, and a systolic blood pressure of 80 mm Hg. What is the appropriate treatment?



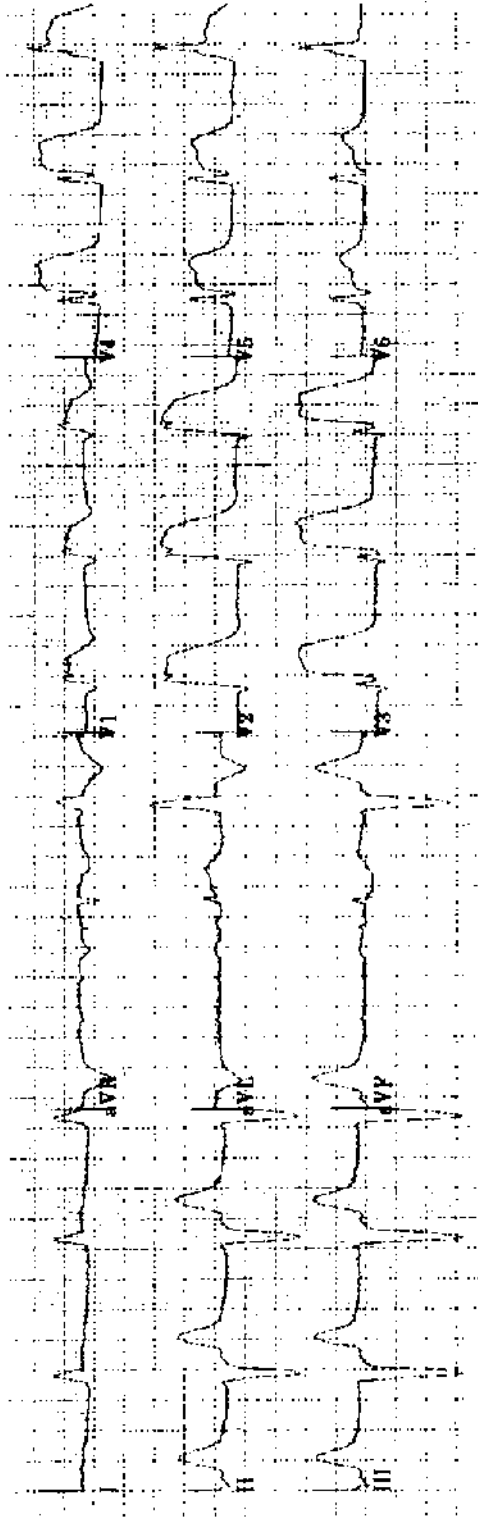
Practice ECG 145 A 59-year-old man who had coronary bypass surgery 4 weeks earlier. For the last week he has had pleurisy, fever and myalgia. His family doctor began treatment for pneumonia, but he has not responded to antibiotics.



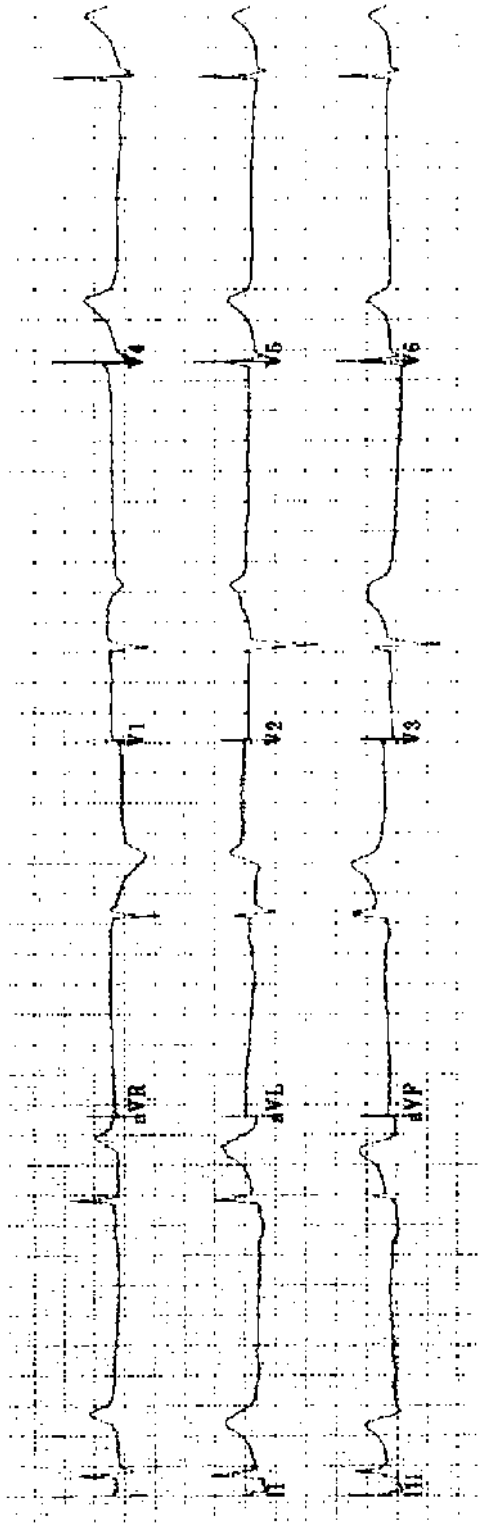
Practice ECG 146 A 69-year-old woman in the emergency room with chest pain.



Practice ECG 147 A 76-year-old woman with a urinary tract infection and possible sepsis.



Practice ECG 148 A 70-year-old man with chest pain.



Practice ECG 149 An 82-year-old woman with dizziness and chest pain.

Interpretation and Comments

The interpretation is the report that accompanies the ECG in the medical record. Comments are provided for teaching purposes. With the early cases, I will discuss measurements as well as diagnosis. This will not be necessary with later ECGs.

1. Interpretation: Normal sinus rhythm (NRS) 70/min. PR .16, QRS .96, QT normal for the rate. Axis 30°. Normal ECG.

Comment: There is a P before each QRS, so the rhythm is sinus. Rate—there are just over 4 large squares between R waves (the RR interval); the rate calculation is $300/4 = 75$, and because the RR is just above 4 large squares, the rate is a bit lower, about 70/min. QT interval—it is less than half the RR interval, roughly normal. Axis—refer to Fig 1.2. The QRS is almost isoelectric in III (positive and negative forces canceling each other), so the QRS vector is about 90° from lead III, or +30°. Actually, the negative Q wave in III is slightly bigger than the R wave, so the axis may be closer to 25°. Morphology—there is baseline artifact in V₆ that is not worth mentioning. An isolated Q wave in III is a normal finding; inferior MI requires Qs in multiple inferior leads. Note the 1.0-mV standardization deflection at the far left of the tracing; this may be excluded from subsequent tracings. A normal ECG! When you read ECGs in the hospital, you may be surprised to find that normal tracings are outnumbered by those with pathology.

2. Interpretation: NSR 60/min. PR .16, QRS .10, QT normal for rate. Axis -35°. Abnormal due to left axis deviation (LAD), nonspecific T wave changes (NSST-TCs).

Comment: Rate—the RR interval is 5 large squares ($300/5 = 60$). Axis—the QRS is roughly isoelectric, a little negative, in II; 90° from II is either -30° or +150°. Because the vector is positive in (points at) I and aVL, the axis is about -30°. I am calling it -35° because the QRS is slightly negative in II. Ts are inverted in V₅ and V₆, and flat in the inferior (II, III, aVF) and lateral (I and aVL) leads. The cause of the T wave changes is uncertain. In this ECG, the transition from net negative to positive complexes occurs around V₄ and V₅; it is borderline and I elected not to call poor R wave progression (PRWP).

3. Interpretation: Sinus tachycardia (ST), 105/min. PR .14, QRS .08, QT normal for the rate. Axis 0°. Abnormal due to ST and NSST-TCs.

Comment: Rate—the RR is just under 3 large squares ($300/3 = 100$). Axis—the QRS is roughly isoelectric in aVF; 90° from aVF is 0°, and the QRS is positive in I. Morphology—the T waves are flat in lateral leads, and there is minimal ST depression.

4. Interpretation: NSR, 80/min. PR .12, QRS .08, QT normal for the rate. Axis 90°. Abnormal due to inferior MI of uncertain age.

Comment: Rate—the RR interval is a bit less than 4 squares ($300/4 = 75$). Axis—the QRS is isoelectric in I (so the axis is 90° from I), and it is positive in aVF. This is within the normal range, but an axis between 90° and 110° may be called a *vertical* axis. Morphology—there are deep Q waves in II, III, and aVF, indicating

inferior wall scar. There are other conditions that may cause Q waves, but they are rare (e.g., pre-excitation and hypertrophic cardiomyopathy). Without ST elevation and chest pain, this is not a pattern of acute MI (with ongoing ischemia). It could be a tracing obtained a day (or a month or a year) after a completed infarction or successful reperfusion therapy.

- 5. Interpretation: Sinus tachycardia 120/min. PR .16, QRS .08, QT normal for rate. Axis 70°. Abnormal due to the rhythm, anterior infarction and ST depression consistent with ischemia. Since the prior tracing, the ST depression is new.**

Comment: Axis—it is closest to isoelectric in aVL, but slightly negative, which would push the axis to the right of 60°. Morphology—Qs limited to V₁ and V₂ may be called a *septal* MI, but *anterior* is fine. Based on coronary anatomy, it is impossible to have infarction of just the interventricular septum, because septal branches originate from the left anterior descending artery, which also supplies the anterior wall. Nevertheless, the term *septal MI* has traditionally been applied to Q waves limited to V₁ and V₂. The deeply depressed, downsloping STs in the anterior and lateral leads are more than nonspecific changes: they look ischemic (see Fig 2.10). Furthermore, comparison with a previous ECG (not provided here) showed that the ST changes were new, and the patient was having chest pain. In this clinical context, the diagnosis of active ischemia is almost certain, but it is a diagnosis that should be made by the clinician, not the ECG reader. This interpretation goes far enough, although asking for clinical correlation could be added.

- 6. Interpretation: NSR 80/min. PR .12, QRS .09, QT normal. Axis 80°. Probably normal ECG with small inferior Qs noted, and diffuse J-point elevation (probably early repolarization).**

Comment: Axis—there is no lead with an isoelectric QRS. To be negative in aVL, the axis has to be more than 60°, and to be positive in I, less than 90°. So the axis is between 60° and 90°, but closer to 90° as it is so negative in aVL. For a Q wave to be significant, it should be a box deep and a box wide. These inferior Qs do not make it; I mention them to make it clear they were not overlooked.

The *J point* is the junction between the QRS and the ST segment. In this case, it is above the baseline in V₂–V₆, and minimally so in inferior and lateral leads. The ST segments are elevated but maintain normal shape with upward concavity. This ST elevation is worth mentioning, but it should be interpreted in a clinical context. For a patient in the emergency room with chest pain, it could indicate pericarditis (it involves multiple vascular distributions, and normal concavity is maintained); you could not be sure from this tracing. (PR interval depression would make pericarditis the diagnosis.) Because you know that this is an insurance examination and that he is young, early repolarization is a safe guess.

- 7. Interpretation: Supraventricular tachycardia (SVT) 160/min, PR uncertain, QRS .06, QT normal. Axis -50° . Abnormal due to SVT, left anterior fascicular block (LAFB), anterior MI of uncertain age, and low voltage.**

Comment: Rhythm—it is a narrow complex tachycardia (with narrow QRSs) and no obvious P waves (could they be buried in the T wave in lead II?). It is a bit too fast for sinus tachycardia in an elderly person. The atrial rate with atrial flutter is usually 300/min, so the ventricular rate with 2:1 conduction is 150/min. It may be a bit slower in an elderly patient, but rarely faster. With a ventricular rate of 160, flutter is less likely. SVT is a reasonable call, and it would include ST as well as other supraventricular arrhythmias. Axis—to be negative in II, it has to be left of -30° , and I am guessing far to the left (beyond -45°), which makes it LAFB. There are deep Qs in V_1 – V_3 ; most with this finding have had an MI, although false positives are possible.

- 8. Interpretation: NSR 70/min. PR .16, QRS .08, QT normal. Axis 10° . Abnormal due to anterior MI and probably inferior MI of uncertain age and nonspecific T wave changes.**

Comment: Axis—almost isoelectric, but a bit negative in III, so the axis is to the left of 30° ; strongly positive in aVF, so it is to the right of 0° . There are Qs in V_1 and V_2 . MI is the correct interpretation, although it could be a false positive. The Q in aVF is broad, although not deep, and there is the deep Q in III. Ts are flat in I, aVL, and V_5 and V_6 . Heart failure may be attributed to ischemic cardiomyopathy in a patient with Q waves in two of the three coronary artery distributions.

- 9. Interpretation: NSR 75/min. PR .22, QRS .11, QT normal. Axis -50° . Abnormal due to first-degree atrioventricular block (1° AV block), LAFB, incomplete right bundle branch block (IRBBB), and left ventricular hypertrophy (LVH) with repolarization changes.**

Comment: If you did not measure the PR, you probably missed the 1° AV block. The QRS is deeply negative in II, so the axis is far left of -30° ; it is slightly negative in aVR, placing the axis just to the right of -60° . I count 7 points for LVH (see Table 2.1): voltage (deep S in III), prolonged QRS, delayed intrinsicoid deflection (look at aVL, a good example of the delay in the time to reach peak voltage), and LAD. The ST-T changes in V_4 – V_6 are probably due to LVH, but it is not the classic strain pattern. A couple of problems with this ECG: Why not inferior MI? There are small positive glitches, R waves in inferior leads, so there are no Qs. What about the tall R in V_1 ? Look closely at that lead: at first glance, the QRS looks narrower than in V_2 . V_1 actually has an rsR pattern, not quite RBBB, as the QRS is not wide enough—but close (I call it IRBBB). LAFB + RBBB would not change the final diagnosis of LVH.

Would bifascicular block plus 1° AV block raise the possibility of incipient trifascicular (complete) heart block and syncope? Not necessarily, as most patients with this pattern are found to have PR prolongation because of delayed con-

duction within the AV node, not below it in the left posterior fascicle (see Chapter 1). Syncope is more common in elderly patients, but this tracing does not indicate a need for a pacemaker or electrophysiologic study in the absence of symptoms.

10. Interpretation: NSR 95/min. PR .26, QRS .08, QT normal. Axis 0°. Abnormal due to 1° AV block.

Comment: Axis—the QRS is isoelectric in aVF and the vector is aimed at lead I (e.g., it is most strongly positive in I). Where should you measure the PR interval? Where the P is well seen and the interval seems longest (lead V₃). Notice that the P is buried in the downslope of the T wave in II, making the QT appear a big longer in that lead. None of these findings explains her loss of memory.

11. Interpretation: Atrial fibrillation (AF) about 70/min with premature ventricular contractions (PVCs) or aberrantly conducted supraventricular beats. QRS .10, QT normal. Axis -50°. Abnormal due to AF, LAFB, and possible inferior MI.

Comment: Fibrillation waves are seen in V₁ and the rhythm is grossly irregular; the rate is a bit slower than usual with AF (consider a digoxin level). Axis—the QRS is slightly negative in aVR and negative in II, putting the axis between -30° and -60°; it looks closer to -60° to me. Are there inferior Qs? The one in III is definite, but there may be a tiny positive glitch in the first complex in aVF, so I hedged with the diagnosis of inferior MI. We do not see much of the ectopic complexes at the end of the recording. Their initial vectors are similar to the other QRS complexes; they could be aberrantly conducted supraventricular beats.

12. Interpretation: AF 80/min. QRS .10, QT normal, Axis 45°. Abnormal due to AF, high QRS voltage, and nonspecific ST-T changes (probably digitalis effect). Cannot exclude LVH.

Comment: Axis—the QRS is positive in all limb leads except aVR; with it positive in aVL and III, the axis must be between 30° and 60°. When all the limb leads are positive, save aVR, I call it 45°. The deep S in V₂ meets voltage criteria for LVH, but the ST changes count less because of digoxin therapy. There may be LVH, and there probably is with the history of hypertension and presence of AF, but a definite diagnosis cannot be made from this ECG. These ST segment changes are typical of digitalis effect; they sag as if you hooked them with your finger and dragged them down. This is different from the ST depression of ischemia (see Fig 2.10) or LV strain (see Fig 2.5). It is a safe bet this patient is taking digoxin (AF and a controlled ventricular rate plus these ST changes).

13. Interpretation: NSR 80/min. PR .18, QRS .08, QT normal. Axis 20°. Borderline ECG with NSST-TCs noted.

Comment: Axis—QRS slightly negative in III, the axis is just to the left of 30°. The flat Ts and sagging STs in V₃-V₅ are not quite normal. An isolated Q wave in III is normal.

- 14. Interpretation: NSR 90/min. PR .18, QRS .16, QT prolonged for the rate (QTc .53). Axis -30° . Abnormal due to left atrial abnormality (LAA), LAD, RBBB, LVH with repolarization abnormalities, and QT interval prolongation.**

Comment: Axis—the QRS is isoelectric in II. LAA—there is a terminal, negative deflection in the P in V_1 plus notching of the P in inferior leads. LVH—voltage, LAA, LAD, wide QRS, and ST-T changes. The QT interval is definitely longer than half the RR interval.

- 15. Interpretation: NSR 60/min. PR .16, QRS .10, QT normal. Axis 35° . Abnormal due to anterior MI of uncertain age and NSST-TCs.**

Comment: Axis—the QRS is roughly isoelectric in III, perhaps a shade positive. There are deep Qs in V_1 – V_3 , with associated T inversion. Because the T inversion extends to lateral leads (V_5 and V_6 , I, and aVL), I added NSST-TCs to the interpretation, but these changes are probably a part of the MI pattern. Thrombolytic therapy? No, because there is no ST elevation, the usual marker of acute, transmural ischemia. You need old tracings for comparison, and you should consider other causes of chest pain. In general, when a patient has recurrent ischemic symptoms, they are identical to those from previous events. I always ask, “Is this just like the pain you had during your heart attack?” If this patient’s pain is ischemic, this ECG suggests that it is angina rather than acute MI—try nitroglycerine therapy. But antacids may work!

- 16. Interpretation: AF, about 90/min. QRS .11, QT normal. Axis -10° . Abnormal due to AF, intraventricular conduction defect (IVCD), and LVH with associated ST-T changes.**

Comment: Axis—almost isoelectric, but a bit negative in aVF. QT interval—the Bazett calculation falls apart with a variable RR interval. In complexes with long RR intervals (V_6 or III), the QT is well below half the RR. When the RR is short, the QT seems long. It is a problem with AF; to diagnose long QT, I want the QT to seem long regardless of the RR. LVH—voltage in V_2 , ST-T changes, wide QRS, and delayed intrinsicoid deflection.

Should she be treated for isolated systolic hypertension? Yes—the Systolic Hypertension in the Elderly Program found that the degree of systolic pressure elevation correlated best with development of LVH, heart failure, stroke, and death; diastolic pressure was less important. Based on the ECG, this patient already has hypertensive heart disease. An echocardiogram would confirm increased LV thickness.

- 17. Interpretation: NSR 75/min. PR .18, QRS .08, QT normal. Axis -30° . Borderline due to left axis deviation.**

Comment: Axis—the QRS is isoelectric in II. It is a fair interpretation; the axis is on the left border of the normal range, but that is the only abnormality. Do not take the *abnormal* designation lightly, particularly for a young patient. An abnormal ECG may mean *heart disease* to his insurance company or employer.

- 18. Interpretation: NSR 60/min. PR .20, QRS .10, QT-U prolonged for the rate. Axis -15° . Abnormal due to PRWP, possible inferior MI, U wave and QT-U prolongation, and possible LVH with associated ST-T changes.**

Comment: Axis—the QRS is positive in II and negative in aVF, which places the axis between 0° and -30° . U wave—well seen in V_3 – V_6 . LVH—wide QRS and ST-T changes in I and aVL. Voltage is close to meeting LVH criteria in the limb leads. The ST-T changes may be missing in V_5 and V_6 because of PRWP—a dilated heart is one of the causes of PRWP, and ST-T changes may be displaced to the left of V_6 , just as the apical impulse may be displaced to the left (perhaps there would be T wave inversion if there were a lead V_8). You notice, however, that I hedge on the diagnosis of LVH. A conduction abnormality, common in elderly patients, could be responsible for T wave changes, delayed transition, and the wide QRS. In this case, make the diagnosis of LVH with an echocardiogram, not the ECG. There is nothing on this ECG that explains her dizziness. There are Q waves in two of the three inferior leads.

- 19. Interpretation: NSR 70/min. PR .16, QRS .10, QT normal. Axis 70° . Abnormal ECG due to possible inferior MI and NSST-TCs. Clinical correlation needed.**

Comment: Axis—the QRS is almost isoelectric, but a bit negative, in aVL. The Q waves in inferior leads are small, on the borderline for the diagnosis of MI. The Ts are a bit tall and peaked in anterior leads, and the T axis is opposite the QRS axis in those leads, but this probably is a normal finding. There is J-point elevation in the V leads. Asking for clinical correlation could apply to every ECG you read, but for tracings with borderline findings, it is worth a mention on the report (it is more than just another way to hedge).

- 20. Interpretation: NSR 70/min. PR .24, QRS .09, QT normal. Axis -30° . Abnormal due to 1° AV block, LAD, and inferolateral MI of uncertain age.**

Comment: When compared to the previous case, this patient's Q waves are deeper and wider and are found in all three of the inferior leads. The diagnosis of inferior MI is certain. There are also deep Qs in V_5 and V_6 , lateral leads. Perhaps he has had two MIs with occlusion of the artery to the inferior wall, then occlusion of another vessel to the lateral wall. But this is unlikely. Instead, the coronary artery supplying this patient's inferior wall probably was large, wrapping around the heart and supplying a part of the lateral wall as well. The resulting infarct was large enough to leave him with heart failure. Inferior MI is usually smaller and less consequential than anterior infarction; this case may be an exception.

- 21. Interpretation: NSR 80/min. PR .13, QRS .09, QT normal. Axis 100° . Abnormal due to biatrial abnormality, PRWP, and right ventricular hypertrophy (RVH).**

Comment: RAA is obvious (tall Ps in inferior leads); LAA is arguable, as there is no positive deflection before the negative deflection in V_1 . RVH—tall R in V_1 , deep S in V_6 , T inversion in V_1 (strain pattern), right-axis deviation (RAD),

right atrial abnormality (RAA). Based on physical findings and the ECG, the patient probably has tricuspid regurgitation.

22. Interpretation: ST 130/min. PR .14, QRS .08, QTc .40. Axis 90°. Abnormal due to ST, RAA, PRWP, and NSST-TCs. Small inferior Qs noted.

Comment: The tall, peaked P waves are typical. She does not meet criteria for RVH. But RAA, PRWP, and relatively low voltage make emphysema a good possibility. The “vertical” axis is also common, and the isoelectric QRS complex in lead I has been identified as a sign of emphysema. Sinus tachycardia suggests that the patient is struggling—this “arrhythmia” is a potent indicator of prognosis in multiple illnesses. Within hours of this ECG, she was on a ventilator.

23. Interpretation: Atrial flutter and a ventricular pacemaker with 100% capture at 70/min. LBBB pattern with marked LAD.

Comment: The saw-tooth flutter waves are apparent in inferior leads. Look at the QRS complexes in I and II; there is a small pacing spike at the beginning of each. The pacer must be located in the right ventricle, as there is a LBBB pattern. The QRS morphology of the paced beat is not usually mentioned in the formal interpretation.

A demand, ventricular pacemaker is commonly set to pace at about 70/min. It is designated a VVI pacemaker: *ventricular* sensing, *ventricular* pacing, and programmed to be *inhibited* from pacing if it senses a native QRS. With atrial flutter or fibrillation there is no reason for a dual chamber pacemaker, as the atrium cannot be paced.

24. Interpretation: NSR 65/min with an isolated PVC. PR .18, QRS .08, QT normal. Axis 45°. Abnormal due to LAA and probable LVH. Cannot exclude previous inferior MI.

Comment: The P wave is biphasic in V₁ and is probably notched in inferior leads. Axis—the QRS is positive in all limb leads (save aVR). LVH—criteria include voltage, LAA, and borderline ST changes. Is there an infarct pattern? I think there are small, positive glitches, R waves, before the S waves in II and aVF. As this may be wrong, I hedged. Although there is probable LVH, he does not have the typical strain pattern seen with the pressure overload caused by aortic stenosis. Volume overload causes LV dilatation and an increase in LV mass without a big increase in LV thickness. This man had mitral regurgitation with a dilated but not thickened LV. The ECG does not allow this differentiation, but the findings are consistent with the diagnosis.

25. Interpretation: Nodal rhythm, 58/min. QRS .13, QT long for the rate. Axis about 10°. Abnormal due to a long QTc, rhythm, and RBBB.

Comment: Retrograde Ps are seen at the beginning of the T wave in multiple leads. The QT seems quite long in V₄ and V₅, and the calculated QTc is .55

second. Thiazide diuretics may depress potassium and/or magnesium levels, causing prolongation of the QT interval. It is important to diagnose and correct these electrolyte disturbances, as they may lead to ventricular arrhythmias and sudden death. Check the digoxin level as well, as the nodal rhythm may be evidence of digitalis toxicity.

26. Interpretation: ST 108/min. PR .16, QRS .08, QT normal. Axis 70°. Abnormal due to ST, anterior MI of uncertain age with persistent ST elevation.

Comment: Axis—close to isoelectric, though slightly negative, in aVL. He probably had the MI a month earlier and misinterpreted his symptoms. Resting tachycardia a month after anterior infarction is a worrisome finding suggesting LV dysfunction. That is reason enough for an echocardiogram. In addition, persistent ST elevation in infarct zone leads may indicate an LV aneurysm. This unfortunate fellow should have had reperfusion therapy at the time of his acute MI.

27. Interpretation: NSR 60/min. PR .18, QRS .08, QT normal. Axis 45°. Abnormal due to deep T inversion in anterior leads consistent with ischemia or non-Q MI.

Comment: She should be hospitalized and treated with aspirin, heparin, clopidogrel, and antianginal drugs. If the troponin is elevated—a possibility with this ECG—I would add a IIb/IIIa inhibitor. Angiography is indicated and probably would show a tight and ragged-appearing lesion in the anterior descending coronary artery, possibly with thrombus. Although this infarction is a small one, with only minimal injury to the anterior wall, she is at risk for occlusion and transmural MI.

28. Interpretation: NSR 70/min. PR .19, QRS .10, QT normal. Axis -15°. Abnormal due to NSST-TCs; cannot exclude LVH.

Comment: Axis—the QRS is slightly negative in aVF, positive in II, so the axis is between 0° and -30°. LVH—the QRS is slightly wide and the axis is toward the left, but neither finding achieves significance. Voltage is not high. There is just the lateral T inversion. She may have LVH, and the ECG is just not sensitive enough to make a certain diagnosis. Get an echocardiogram to measure LV thickness.

29. Interpretation: AF with rapid ventricular response. QRS .10, QT long for the rate, axis 0°. Abnormal due to AF, LVH with repolarization changes, and inferior MI of uncertain age. Cannot exclude active ischemia.

Comment: The ST segment depression may all be due to LVH, but the degree of depression seems too deep for that. A rapid ventricular rate can provoke ischemia, which may be painless in a patient with diabetic neuropathy. I would treat her for ischemia as well as pulmonary congestion. (It later became apparent that she had ketoacidosis and pulmonary edema precipitated by a non-ST elevation infarction.)

30. Interpretation: NSR 80/min. PR .18, QRS .16, QT normal, axis 100°. Abnormal due to RBBB, RAD, and possibly acute anterior and inferior MI.

Comment: This is an unusual ECG because there is ST elevation in both inferior and anterior leads. Recall that it is uncommon for acute ischemia to occur simultaneously in two different vascular distributions. Why would two different arteries occlude at the same time? Global ST elevation instead suggests a global cause such as pericarditis. But this looks more like ischemia to me because (1) the STs are upwardly convex and (2) there is T inversion at the same time there is ST elevation. The Ts can invert with pericarditis, but the STs usually return to baseline before they do.

Here is the explanation for this case of coincidental MIs. His right coronary artery occluded and he had an inferior MI 2 years earlier, but the infarct was incomplete. Good collateral flow from the anterior descending artery to the distal right coronary artery limited the size of the inferior MI (see Fig 2.8). Now he has occluded the anterior descending artery, losing flow to the anterior wall plus flow through the collaterals to his inferior wall. He is thus losing two vascular distributions with a single coronary occlusion.

Comparison of this ECG with old tracings showed that the bifascicular block is new; plans were made to take the patient to the catheterization lab for a temporary pacemaker and acute angioplasty. While in the elevator, he lost his blood pressure and died from cardiogenic shock. (Cause of death: How about old age? Multiple infarctions complicated by LV failure are just too much heart disease for an 85-year-old person. There are many clinicians who would argue against aggressive, interventional therapy at this stage of life when the odds of success are poor.)

31. Interpretation: ST 110/min. PR .14, QRS .16. Axis -20°. Abnormal due to the rhythm and LBBB.

Comment: In this case, the QTc is .50 second. In the presence of LBBB, QT prolongation loses its significance. There is increased voltage, a wide QRS, lateral ST-T wave changes and possibly LAA. LBBB usually precludes an ECG diagnosis of LVH (as it does MI). However, the combination of extremely high QRS voltage (S wave in V_2 + R wave in V_6 > 45 mm) plus LAA is evidence for LVH in the presence of LBBB. She has both findings, and probably has hypertensive heart disease and LVH. An echocardiogram would be needed to confirm the diagnosis (and has become the gold standard for LVH).

32. Interpretation: NSR 90/min. PR .11, QRS .13, QT normal. Axis 15°. Abnormal due to pre-excitation (Wolff-Parkinson-White syndrome [WPW]).

Comment: The PR is borderline short (depends on the lead). There is a delta wave (lead I or the V leads). Compare this tracing with those demonstrating bundle branch block. With WPW, the *initial* portion of the QRS is slurred. With bundle branch block, the *terminal* part of the QRS is slurred. This makes sense when you think of the pathophysiologic characteristics of the two conditions

(see text). A blocked bundle branch causes a portion of the heart to be depolarized late, affecting the end of the QRS. There is a tall R wave in V_1 (consistent with posterior MI), and there are possible Q waves in inferior leads. Delta waves may appear as pseudo-Qs.

33. Interpretation: SVT 180/min. QRS .07, QT long for the rate. Axis 90° . Abnormal due to SVT. High QRS voltage noted.

Comment: P waves are not easily seen, although the notched upstroke of the T wave in the precordial leads could be a P. Atrial flutter is unlikely at a rate of 180/min. With flutter, the atrial rate is usually 300/min, and the ventricular rate is 1/2, 1/3, or 1/4 of that (with 2:1, 3:1, or 4:1 block). It is not rapid AF, as the rhythm is regular. This could be a reentrant SVT due to a pre-excitation syndrome; you would not expect to see delta waves during SVT where antegrade conduction is through the AV node, right? (See Fig 1.16.)

When reading the ECG, making the simple diagnosis of SVT is adequate. Most of these cases are due to AV nodal reentry (the reentrant focus is in the AV node).

34. Interpretation: NSR 75/min. PR .22, QRS .08, QT normal. Axis -30° . Abnormal due to 1° AV block, LAD, and NSST-TCs.

Comment: I agree that there is ST elevation in V_2 , but not enough to make a diagnosis of acute ischemia. Also, the STs have normal upward convexity. There is T inversion, but it is not the deep, symmetrical T inversion typical of non-Q MI (see ECG No. 27). So I am calling the ST-T changes nonspecific.

If the pain sounds like angina, treat her with nitroglycerine and aspirin. It would be important to *repeat the ECG* in 10 to 15 min, especially if the quality or intensity of pain changes. You might discover increased ST elevation if this is an MI. Finding an old tracing for comparison would help. In the absence of the marked ST elevation that is typical of acute, transmural MI, I would not recommend thrombolytic therapy. Remember that the risk of intracranial bleeding with thrombolysis is higher for elderly patients.

35. Interpretation: AV sequential pacemaker with 100% capture, 60/min.

Comment: There are pacing spikes before the P wave and QRS. The QRS has an LBBB pattern indicating a right ventricular location of the pacing electrode. This dual-chamber pacemaker, with leads in the right atrium and right ventricle, is called a DDD pacemaker; it has dual-chamber sensing, dual-chamber pacing, and dual sensing modes (pacing that can be inhibited or triggered by preceding beats).

36. Interpretation: NSR 90/min. PR .20, QRS .16, QTc .54. Axis -60° . Abnormal due to RBBB + LAFB, and LVH. Cannot exclude lateral MI of uncertain age.

Comment: QTc prolongation loses its usual significance when there is bundle

branch block (which must alter the sequence of ventricular repolarization as well as depolarization). It is possible to diagnose ventricular hypertrophy and infarction in the presence of RBBB, but not with LBBB. The deep Q in aVL raises the possibility of lateral MI.

LVH indicates that her hypertension has not been adequately controlled. Confirm the diagnosis with an echocardiogram.

37. Interpretation: AF 80/min. QRS .10, QT normal. Axis 60°. Abnormal due to AF, anterior MI of uncertain age, and NSST-TCs.

Comment: The ST-T changes in precordial leads may be related to the old MI. ST sagging in inferior leads looks like digitalis effect (and you would expect that she is taking it as there is AF with good control of the ventricular rate).

38. Interpretation: Complete heart block, 36/min. QRS .18, QT normal. Axis 130°. Abnormal due to complete heart block and a ventricular escape rhythm.

Comment: At first glance, I called this 2:1 AV block. With modern equipment, the lead changes are instantaneous, and the top line of recording can be read as a continuous rhythm strip. Notice that the P waves that appear to be conducted (every other P wave) are followed by progressively longer PR intervals. The second to last beat has such a long PR that it is hard to believe the P is conducted. And the last beat has a short PR. Despite this variability of the PR, the ventricular rate is constant. The ventricular rate is not a multiple of the atrial rate; but it is close and for this reason has the appearance of 2:1 block. This is an example of AV dissociation and complete heart block.

The ventricular escape rhythm has a rate of 36 beats/min. This relatively rapid rhythm accounts for the absence of syncope. Why not diagnose RBBB + left posterior fascicular block (LPFB)? The ventricular beats have that morphology, but they originate from the ventricle. The term *bundle branch block* indicates that the beat originates from above the bundle branch.

39. Interpretation: NSR 90/min. PR .16, QRS .90, QT long for the rate. Axis 60°. Abnormal due to acute anterolateral MI and long QT.

Comment: Acute ischemia is one cause of QT interval prolongation, and patients who have a long QT during their acute MI have an increased risk of ventricular arrhythmias.

There is reciprocal ST depression in inferior leads, but the main event is clearly the anterolateral ST elevation. He already has Q waves in precordial leads, but that does not mean that the MI occurred in the distant past. According to the history he had 2 hours of pain, then relief. It sounds like occlusion of the anterior descending artery, then spontaneous thrombolysis with relief of pain. With reperfusion early in the course of MI, Q waves may evolve rapidly, within minutes. When pain redeveloped, the STs reelevated and the Qs remained.

Because there is ischemic pain and ST elevation, he must have live muscle in the region, and reperfusion therapy is indicated (primary angioplasty if readily available, and if not, thrombolytic therapy).

The size of anterior infarction is proportional to the number of leads with ST elevation; in this case V_2 - V_6 plus I and aVL. This is a big MI.

40. Interpretation: NSR 60/min. PR .16, QRS .08, QT normal for the rate. Axis 60°. Abnormal due to anterolateral MI. Compared with the prior tracing. ST changes are less prominent and the QT interval is shorter.

Comment: It appears that thrombolytic therapy was successful. This ECG was done 4 hours later, and there is less ST elevation. The reciprocal ST depression in inferior leads has resolved. Some persistence of ST elevation is typical after successful thrombolysis, but prompt improvement in ST elevation is the best indicator of successful reperfusion. Shortening of the QTc from .44 to .40 second is interesting. It is common to see resolution of conduction abnormalities when infarction is interrupted. There is a similar beneficial effect of reperfusion on prolonged QT.

41. Interpretation: NSR 60/min. PR .18, QRS .09, QT normal. Axis 45°. Borderline ECG due to incomplete RBBB.

Comment: IRBBB may indicate RV volume overload (it is a sensitive but not specific finding). For an asymptomatic young person, consider atrial septal defect (ASD). An echocardiogram would exclude that illness. And the chest x-ray would show shunt vascularity with ASD. But my first diagnostic study would be a physical exam (fixed splitting of the second heart sound and a soft systolic murmur). I would order an echo only if the exam result was abnormal. Most patients with this ECG have no heart disease.

42. Interpretation: NSR 65/min. PR .16, QRS .10, QT normal. Axis -70°. Abnormal due to IRBBB, LAFB, and PRWP.

Comment: LAFB is a common cause of PRWP across precordial leads. Here is another case of IRBBB, this time with associated left anterior fascicular block (LAFB). There are physical findings to indicate ASD.

The ECG allows you to differentiate primum from secundum ASD. The ostium secundum defect accounts for 85% of ASDs; it affects the superior part of the septum and has no effect on the infranodal conduction system. The primum defect is an abnormality of the endocardial cushion, which also is the origin of the mitral and/or tricuspid valves and the upper part of the interventricular septum. Primum ASDs usually affect the anterior fascicle; LAFB thus points to a primum ASD (and a normal axis, to secundum ASD).

The loud murmur probably is mitral regurgitation; with a primum defect, there may be a cleft mitral on tricuspid leaflet. The usual systolic murmur of a secundum ASD is soft and is caused by increased flow across a normal pulmonic valve.

43. Interpretation: NSR 90/min. PR .18, QRS .09, QT is long for the rate with QTc .54. Axis 70°. Abnormal due to long QT and LAA.

Comment: There is notching of the P in lead II. The dominant finding is the long QT. Phenothiazine derivatives, including antihistamines, may lengthen the QT interval. When some antihistamines are combined with erythromycin, the QT interval prolongation may be aggravated; this combination may precipitate ventricular arrhythmias. The history of syncope and the ECG are indications for monitoring in the telemetry unit.

44. Interpretation: Polymorphic ventricular tachycardia (VT), torsade de pointes.

Comment: The axis of the ventricular beats is changing; at the beginning of the strip the QRS complexes seem negative, then they become positive. The axis is “turning about a point”; hence the name (also a ballet term). Torsade de pointes is a form of VT that tends to occur with *conditions that prolong the QT interval* (see Table 2.5). Treatment for the arrhythmia includes measures that shorten the QT: magnesium infusion, increasing the heart rate with temporary pacing, or even isoproterenol infusion.

45. Interpretation: Top: NSR, 65/min with 3-beat bursts of VT. Middle: Monomorphic VT, 170/min. Bottom: VF.

Comment: Sudden cardiac death from ventricular fibrillation (VF) is a common complication of severe LV dysfunction. This patient was resuscitated and subsequently received an implantable defibrillator.

46. Interpretation: NSR 85/min with an AV sequential pacemaker and ventricular pacing.

Comment: There is a P before each QRS. The pacer senses the P wave and paces the ventricle after a preset AV (or PR) interval. As the ventricular lead is positioned in the right ventricle, the QRS has an LBBB pattern. Pacing spikes are often small and may not be apparent in all ECG leads.

47. Interpretation: Sinus bradycardia (SB) 50/min. PR .14, QRS .08, QT normal. Axis 45°. Abnormal due to T inversion consistent with anterolateral ischemia or non-Q infarction.

Comment: The deep and symmetrically inverted Ts are typical for non-ST elevation infarction (to differentiate that from unstable angina with the same ECG findings depends on cardiac enzymes). In V_2 and V_3 , there is a hint of ST elevation. These STs have slight upward convexity. I am not sure it means anything in the absence of chest pain, but if he had recurrence of pain I would repeat the ECG promptly, looking for more ST elevation. This is a case for antithrombotic therapy and early angiography.

48. Interpretation: NSR 95/min. PR .12, QRS .10, QT normal. Axis 45°. Abnormal due to ST elevation, possibly inferolateral ischemia or MI.

Comment: The ST elevation in inferior leads plus V_5 and V_6 is subtle but definite. There is also reciprocal ST depression in V_1 through V_3 . Having an old tracing for comparison would help, but this is probably acute MI. Is it large or small MI? Recall that with inferior MI, infarct size is proportional to the amount of ST elevation in inferior leads. These STs are not up very much. The ECG should be repeated in a few minutes, as the degree of ST elevation can vary during the acute MI. It probably is a small MI, and this would figure in decisions about how aggressively to treat. Acute angioplasty is low risk and would be the treatment of choice as pain is ongoing.

Thrombolytic therapy carries a small but definite risk of intracranial bleeding, and some would recommend avoiding it with small, low-risk MI. This patient has had chest pain for 9 hours, and the chances of salvaging muscle are diminished that late in the course of MI. A particular complication of late thrombolytic therapy—after 12 hours of pain—is myocardial rupture. In the absence of other clinical indicators of high risk with this infarction, I would not treat her with thrombolytic agents.

It is important to recognize that ST elevation may be subtle with acute MI. Even with small infarction, there is a risk of early arrhythmias. This patient should be in the hospital on a monitor (not at home taking antacids).

49. Interpretation: NSR 95/min. PR .20, QRS .08, QT normal. Axis -30° . Abnormal due to, LAD, PRWP, NSST-TCs.

Comment: This PR is borderline. There are small R waves in V_2 and V_3 , and this is not an anterior MI. Delayed R progression is probably related to the axis. Note that this ECG report, like many, is descriptive and provides no clinical diagnosis. She has diabetes. Could the T inversion in aVL be a subtle indicator of silent, occult ischemic heart disease? Sure; but that is not an issue to be addressed when reading the ECG.

50. Interpretation: SB 50/min. PR .24, QRS .10, QT long for the rate with QTc .57. Axis 70° . Abnormal due to SB, LAA, 1° AV block, long QT, and NSST-TCs.

Comment: The computer read a possible anterior MI; I see positive glitches at the beginning of the QRS in V_2 and V_3 . In this case, with the rate less than 60/min, the QTc is less than the measured QT (recheck Bazett's formula). The ST sagging in V_5 looks like digitalis effect, a good possibility in an elderly man with bradycardia and 1° AV block.

51. Interpretation: AF 70/min. QRS .11, QT normal. Axis -50° . Abnormal due to AF, LAFB, NSST-TCs, and PRWP (cannot exclude prior anterior MI or LVH).

Comment: The premature beat in V_1 could be a PVC, but it may also be a

supraventricular beat that is aberrantly conducted. The fact that its axis is similar to that of other beats supports aberrancy. The diagnosis of AF may be incorrect; the first RR intervals in I, aVR, and V₄ are identical. Perhaps it is sinus rhythm with low voltage Ps, or a nodal rhythm. But with a rhythm this irregular, I am willing to call it AF (and possibly be wrong). There could be an anterior MI, as just some of the complexes in V₂ and V₃ have small initial R waves. LVH is possible as well: LAD, wide QRS, lateral ST-T changes (see Table 2.1).

There is a lot going on in this ECG. When there are multiple abnormalities, just look at each of the things on your list one at a time (see Table 1.1) and note the findings in your interpretation. It is like caring for a patient in the ICU with multiple problems; it is easiest to have a problem list and deal with each problem individually.

52. Interpretation: Precise measurement of intervals is not possible without time lines. In the right precordial leads the QRS looks wide, there is J-point elevation, and T wave inversion. Abnormal due to possible IVCD and findings typical of the Brugada syndrome.

Comment: The Brugada syndrome was described in the early 1990s, and these are the typical ECG findings. The ST elevation in V₁₋₃ is saddle shaped, and the apparently wide QRS in these leads suggesting RBBB or IRBBB is due to the J-point elevation. Note that the terminal QRS in limb leads is not slurred (as in the case of the RBBB), and in these leads the QRS duration is normal. Patients with the Brugada syndrome have no cardiac structural abnormality and normal LV function. But there is a defect in the cardiac membrane sodium channel, and a risk of VT and sudden death. With syncope, electrophysiologic testing is indicated. Close relatives should have screening ECGs.

53. Interpretation: NSR 70/min, PR .16, QRS .08, QT normal. Axis -40°. Abnormal due to LAD, PRWP, and NSST-TCs.

Comment: This man has idiopathic, dilated cardiomyopathy, which may account for the relatively low voltage as well as all of the abnormal findings. But there is nothing on the ECG that is specific for cardiomyopathy. The absence of Q waves makes ischemic cardiomyopathy unlikely.

54. Interpretation: NSR 80/min. PR .16, QRS .10, QT normal. Axis 30°. Abnormal due to NSST-TCs. Small inferior Qs noted.

Comment: The small Qs in II and aVF are not enough to call this an inferior MI, despite the history of MI. It is not unusual for the Qs of small inferior infarction to disappear gradually. (The most famous example of this was Lyndon Johnson, who carried a miniature of his ECG so that he could show doctors he met and challenge them to find his MI. Recall that he also enjoyed showing his cholecystectomy scar.)

The sagging ST segments suggest digitalis effect; with her history of AF, she may be taking digoxin. Is the QT long? It is hard to be sure.

55. Interpretation: NSR 60/min. PR .14, QRS .10, QT normal. Axis 30°. Abnormal due to NSST-TCs and small inferior Qs. U wave noted.

Comment: The U wave is seen in V₂ through V₄; the QTU is still in the normal range. Although the Q waves are small, this probably is an inferior MI because there is associated T inversion in leads III and aVF.

56. Interpretation: NSR 70/min. PR .14, QRS .15, QT normal. Axis -50°. Abnormal due to LAA, LAFB, IVCD, PRWP, and NSST-TCs.

Comment: At first glance, this looks like LBBB; the QRS is wide and terminal forces are aimed to the left. The small Qs in I and aVL—the so-called septal Qs—prevent that diagnosis (see text and Fig 2.4). Because the diagnosis is IVCD rather than LBBB, I mention ST-T changes, delayed R progression, and LAFB in the ECG report.

Because it is not LBBB, why not call it LVH? There are enough criteria (see Table 2.1). Because the conduction abnormality could cause all these findings, I elected not to make that call. It would not be wrong to indicate possible LVH. Intraventricular conduction abnormalities are common among elderly patients.

57. Interpretation: NSR 95/min. PR .20, QRS .14, QTc .70. Axis -40°. Abnormal due to LAA, LBBB, and a long QT interval.

Comment: LAA may be a reach, but I think the P is broad and notched in III, and roughly biphasic in V₁. LBBB may be responsible for long QT; QT prolongation does not have the same significance in the presence of gross conduction abnormalities. But this QT is so impressive that I decided to mention it, particularly as there is a history of arrhythmia. At the least, he should have his electrolytes checked—including magnesium—and medicines reviewed.

58. Interpretation: NSR 60/min. PR .14, QRS .09, QT normal. Axis -60°. Abnormal due to LAD plus inferolateral MI of uncertain age, NSST-TCs.

Comment: Because of inferior Q waves, call this LAD rather than LAFB. The Q waves are impressive; I elected to call them inferolateral rather than inferior + lateral or inferior + anterior.

The patient had no history of MI. An echocardiogram showed marked thickening of the interventricular septum plus other features of idiopathic hypertrophic subaortic stenosis (IHSS), a form of hypertrophic cardiomyopathy. We tend to think of Q waves as specific for myocardial scar; it is a reliable finding, as exceptions (false positives) are uncommon. IHSS and WPW can fool you with a pseudoinfarct pattern.

59. Interpretation: NSR 90/min. PR .15, QRS .07, QT normal. Axis 120°. Abnormal due to LAA, RAD, probable RVH with associated repolarization changes.

Comment: The relatively low voltage is typical of emphysema. RAD, the tall R in V₁ and deep S in V₆ (relative to overall voltage), plus the T changes in the

right precordial leads make RVH likely. She has cor pulmonale. Note that her LAA is an unrelated finding, not part of the RVH or cor pulmonale syndrome. You might expect to see RAA, not LAA; perhaps she has hypertension as well.

60. Interpretation: ST 110/min. PR .14, QRS .08, QT normal. Axis -35° . Abnormal due to ST, LAD, probable LAA, and anterior MI of uncertain age.

Comment: Sinus tachycardia at rest is consistent with his known congestive heart failure and suggests LV decompensation. LAA is consistent with increased pulmonary capillary wedge pressure. There are Qs in just three precordial leads, changes that are not that extensive. Infarction patterns on the ECG do not always reflect the degree of cardiac disability. Perhaps he has hypertensive heart disease or cardiomyopathy in addition to his ischemic heart disease. Again, the resting tachycardia may be the most telling finding.

61. Interpretation: Atrial flutter with 2:1 block, 135/min. QRS .14, QT long for the rate. Axis 60° . Abnormal due to rhythm, unusual P axis, RBBB and associated repolarization change. Small Q waves in inferolateral leads noted.

Comment: The ventricular rate in atrial flutter with 2:1 block is usually 150/min. It may be somewhat slower in an older person with a tired conduction system, and there appears to be flutter waves in lead II. The inferolateral Qs are small but worth mentioning. ST depression may all be due to RBBB, but it could reflect ischemia in a patient with chest pain. We are not given that history. Comparison of this with a previous ECG is important, particularly for an acutely ill patient.

62. Interpretation: AF 90/min. QRS .10, QT normal. Axis -10° . Abnormal due to rhythm, NSST-TCs.

Comment: There appears to be flutter waves in inferior leads. This could be called atrial flutter with variable block or atrial flutter-fib. Because atrial flutter is usually a regular rhythm, and I find no area where the rhythm is regular, I have called this AF. But you can see where there may be some blending of the two conditions. It looks like the Ts are inverted in inferior leads and flat in V_5 and V_6 , but these apparent changes may be due to flutter waves.

As a rule, patients with AF need anticoagulation (to prevent peripheral embolism). This is recommended for atrial flutter as well, although the evidence is less compelling. Based on this ECG, I would call it AF and treat him with warfarin. The trials of anticoagulation for AF generally identified elderly patients as having the highest risk for peripheral embolism.

63. Interpretation: NSR 90/min. PR .20, QRS .12, QT normal. Axis 60° . Abnormal due to RBBB and acute anterolateral MI.

Comment: Axis—the QRS looks most isoelectric in aVL, and it is positive in II. The QRS is wide enough for bundle branch block. Rather than an RSR pattern

in V_1 , there is a qR pattern; the initial positive deflection is lost because of the anterior MI.

This is another unusual ECG in which ST elevation involves multiple vascular regions. I believe it is infarction rather than pericarditis for a few reasons: the degree of ST elevation (I have never seen pericarditis push the STs this high), the upward convexity of STs, the early T inversion in V_2 , the associated Q waves, and the patient's age (acute pericarditis is more commonly an illness of younger patients, and this man is in the coronary age group). He probably has a substantial anterior descending artery with large branches that reach the lateral wall.

It is a big MI. Recall that the size of anterior MI is proportional to the number of leads with ST elevation, not the degree of elevation. I count nine leads with elevated STs. Once, an elderly man who had had coronary artery spasm, ST elevation, and terrible chest pain told me later, "Doc, that was the Big Mac." This looks like the Big Mac to me. Without early and successful reperfusion therapy the prognosis is terrible.

64. Interpretation: ST 100/min. PR .24, QRS .10, QT normal. Axis 10° . Abnormal due to 1° AV block and NSST-TCs. Small inferior Qs noted.

Comment: In a couple of leads (II, V_4), it appears that the QT is long. But in leads where the P and the T waves are distinct (V_2 and V_3), it is apparent that the P is making the end of the T wave difficult to see. There seems to be a small initial R wave in III, and the small, isolated Q in aVF does not make the diagnosis of MI. The flat and slightly depressed STs in V_2 - V_4 deserve mention.

Consider digitalis toxicity with the long PR interval, confusion, and blurred vision (although the ST depression does not have the sagging appearance of digitalis effect).

65. Interpretation: NSR 70/min. PR .22, QRS .14, QT normal. Axis -60° . Abnormal due to 1° AV block, LAFB, IVCD, NSST-TCs, and PRWP.

Comment: It is not LBBB because of the septal Q (aVL). The PRWP may be the result of the conduction abnormality, but it could reflect anterior ischemia (look at the ST and T changes). Nevertheless, delayed R progression is a non-specific finding, and speculation about possible infarction is the role of the patient's doctor, not the ECG reader. In the presence of conduction disease like this, a false-positive stress test result is a possibility. An exercise perfusion scan or exercise echocardiogram would be better. With LBBB a pharmacologic stress perfusion scan is the most accurate screening study.

66. Interpretation: NSR, 90/min. PR .08, QRS .14, QT normal. Axis -60° . Abnormal due to pre-excitation.

Comment: It looks like LBBB, but the short PR and the patient's age raise the possibility of WPW—that was my diagnosis. In a number of leads, the delta

wave slurs the upstroke of the QRS, and the terminal portion of the QRS looks normal. Interventricular conduction abnormalities tend to slur the tail end of the QRS (see ECG No. 65).

The next day, her ECG looked normal. Conduction through the bypass tract can come and go. Bundle branch block seldom varies.

67. Interpretation: AF 50/min. QRS .14, QT normal. Axis -50° . Abnormal due to AF with slow ventricular response, IVCD, PRWP, and inferolateral MI of uncertain age.

Comment: This 86-year-old patient is not taking an AV nodal blocking drug. His slow ventricular rate with AF indicates a sick AV node. His symptoms indicate that he may be having more severe bradyarrhythmias. I would admit him to a telemetry bed, expecting to document long pauses. He would then receive a pacemaker. Why not get an outpatient, ambulatory monitor? With symptoms for just 1 week and this ECG, I am concerned about syncope and injury.

68. Interpretation: Probable wandering atrial pacemaker 90/min (suggest rhythm strip). PR variable, QRS .08, QT normal. Axis 55° . Abnormal due to rhythm, NSST-TCs.

Comment: An alternative to wandering atrial pacemaker would be NSR with premature atrial contractions (PACs). The rhythm could be due to digitalis toxicity, but it is as likely related to her age. The STs are sagging in precordial leads; I would at least check the digoxin level.

69. Interpretation: NSR 75/min. PR .13, QRS .08, QT normal. Axis 90° . Borderline due to tall peaked Ts consistent with hyperkalemia; may be a normal variant.

Comment: This patient was taking hydrochlorothiazide with spironolactone, plus KCl. Her potassium was 5.8. When the potassium was stopped, her T wave amplitude fell. The T wave changes in this ECG are typical of mild hyperkalemia. With higher potassium, the Ts get much taller, and T wave amplitude can exceed that of the QRS. (A student once told me he imagined a stack of small Ks under the tall T wave.) Conduction abnormalities then appear (wider QRS, prolonged PR). With hyperkalemia, bradyarrhythmias are the rule; hyperkalemia precipitates rapid rhythms, either atrial or ventricular.

70. Interpretation: Wide-complex tachycardia 140/min, possibly VT. QRS .20, QT long for the rate. Axis -80° . Abnormal due to rhythm, LBBB pattern. Clinical correlation needed.

Comment: I cannot be sure about the rhythm. The LBBB pattern favors VT, whereas RBBB would suggest aberrant conduction and SVT. The glitch at the beginning of the QRS in II and aVF could be a P wave, suggesting a supraventricular rhythm of some sort (possibly nodal tachycardia with a retrograde P). But it is impossible to tell from this tracing. In addition to hedging, it seems best, to me, to indicate the most serious possibility in the ECG report.

If the patient is stable, recording bigger Ps with an esophageal or right atrial lead would provide an answer. If unstable, DC cardioversion would be justified. With such an arrhythmia, you should measure electrolytes (including magnesium) and the digoxin level.

71. Interpretation: Atrial pacemaker, 100% capture at 100/min. QRS .08, QT long for the rate. Axis 30°. Abnormal due to pacer, low QRS voltage, inferolateral ischemia, possibly acute MI.

Comment: These pacing spikes look different from others you have seen; they have high amplitude, are biphasic, and have a slowly tailing end that makes them look like QRS complexes. However, they are followed by low-voltage QRSs that in turn are followed by T waves. These pacing spikes are typical of *unipolar* leads. *Bipolar* leads have lower amplitude, are sharper, and tend to be uniphasic (see ECG No. 35). Pacing the atrium has no effect on QRS morphology, and it is possible to diagnose ischemia with inferolateral ST elevation plus reciprocal ST depression in anterior leads.

72. Interpretation: ST 120/min. PR .16, QRS .14, QT long for the rate. Axis -20°. Abnormal due to rate and LBBB, not present on previous ECG.

Comment: This may be rate-related bundle branch block. The LBBB could resolve when the heart rate comes down. No specific treatment is needed other than a repeat ECG. Could the conduction change indicate intraoperative MI? That is a possibility, but the odds are against it with no prior history of coronary disease. Overnight observation on a monitor and cardiac enzymes would be sensible. Consider an echocardiogram (regional wall motion changes).

73. Interpretation: NSR 75/min. PR .22, QRS .08, QT long for the rate with QTc .48. Axis 60°. Abnormal due to 1° AV block, long QT, and ST sagging consistent with digitalis effect.

Comment: The QT interval is borderline. I thought there might be a U wave tacked on the end of the T in V₂ and made the call. I may be wrong. The sagging STs look like digitalis effect; especially in a patient with a long PR and history of AF.

74. Interpretation: NSR 90/min. PR .14, QRS .09, QT normal. Axis 30°. Abnormal due to acute inferior MI and PRWP.

Comment: This could be an inferolateral MI as there is slight ST elevation in V₆ as well as the inferior leads. The degree of ST elevation is minimal, so this is not a large inferior infarction (see Fig 2.13). On the other hand, there are reciprocal ST-T changes in anterior leads plus I and aVL. I think she meets criteria for reperfusion therapy, particularly as you are getting to it early in the course of infarction. But if she had a contraindication to thrombolytic therapy, and angioplasty was not available, I would not feel badly for her. It is probably a low-risk MI.

75. Interpretation: NSR 95/min with PVCs. PR .14, QRS .08, QT normal. Abnormal due to PVCs and anterior MI of uncertain age.

Comment: With this ECG, you can be sure that the ectopic beats are ventricular and not atrial with aberrant conduction (even with the RBBB pattern). With calipers or the edge of a piece of paper, mark the P-to-P interval. Now measure from the P wave of the last sinus beat before the ectopic beat in V_3 . Just where the next P should arrive, there is a glitch on the ectopic QRS. That glitch probably is a P wave that comes on time and is not conducted. The subsequent P wave also comes on time, so that the atrial rhythm is not reset by the ectopic beat. This is an example of AV dissociation. As the ectopic beats do not affect the atria, they must originate in the ventricle.

76. Interpretation: Uncertain rhythm (atrial flutter and nodal rhythm are possibilities), no P waves seen, 75/min. QRS .09, QT normal. Axis 110° . Abnormal due to rhythm, RAD, low voltage, and RVH.

Comment: This could be atrial flutter; look at the baseline in V_1 for possible flutter waves. The rate is right for 4:1 conduction, and flutter is common with obstructive lung disease. Another possibility is a nodal rhythm. The diagnosis of RVH is supported by ST-T changes in right and midprecordial leads, in addition to the R in V_1 , deep S in V_6 , and RAD. She has cor pulmonale.

77. Interpretation: NSR 65/min. PR .20, QRS .08, QT normal. Axis 45° . Abnormal due to probable anterior ischemia; possible anterior MI.

Comment: In addition to T inversion, there is slight ST elevation in anterior leads, more than is usually seen with non-Q MI (or “non-ST elevation” MI). Perhaps there is a tiny positive glitch (R wave) in V_2 , perhaps not. Creatine kinase rose (to twice normal), consistent with non-Q MI. With the brief duration of pain and this ECG, the next steps are antithrombotic therapy and angiography.

78. Interpretation: SB 58/min. PR .12, QRS .10, QT normal. Axis 45° . Abnormal due to acute inferior MI with reciprocal ST depression in lateral leads.

Comment: A young person with his first MI; there is no time to waste. The latest studies indicate that angioplasty/stenting is the best treatment if arterial puncture in the cath lab can be accomplished within 2 hours. Be realistic when gaging how quickly he can be transferred (doctors and hospital administrators often are not). If it is going to take more than 2 hours, treat him with tissue plasminogen activator.

79. Interpretation: NSR 70/min. PR .12, QRS .09, QT normal. Axis 45° . Abnormal due to ST-T changes consistent with inferolateral ischemia. Since the previous ECG, there is less ST elevation.

Comment: While the ST segments have come down considerably, there is still some elevation. That is often the case after successful thrombolysis, but partial

resolution of ST elevation and relief of pain suggest successful myocardial salvage. The next step: A decade ago, many argued that medical therapy was adequate, reserving angiography for those with a positive stress test. Practice has now shifted in favor of early angiography and stenting because of the high risk of reocclusion. Think of this as the most unstable of acute coronary syndromes. You must “pacify the infarct artery.”

80. Interpretation: ST 120/min, PR .12, QRS .10, QT long for the rate with QTc .46. Axis 30°. Abnormal due to ST and acute inferior ischemia. Compared with the previous ECG, ST segment elevation in III and in aVF may be more prominent.

Comment: Well, they did not send him for angiography, and he probably has reoccluded. Now the choices are retreatment with rT-PA, emergency transfer for rescue angioplasty, or traditional measures for acute MI. I am not excited about further thrombolytic therapy; the ST segments are not dramatically higher than before, and the pain could be postinfarction pericarditis (with thrombolytic drugs, there may be a risk of bleeding into the pericardium). With early angiography after thrombolytic therapy, he probably would have avoided this uncertain and unstable situation. He had chest pain, but many with postinfarction reocclusion have silent—painless—ischemia. This is thought to be from ischemic injury to sensory nerves in the infarct zone.

81. Interpretation: NSR 65/min. PR .12, QRS .08, QT long for the rate with QTc .56. Axis indeterminant. Abnormal due to posterolateral MI with acute lateral ischemia.

Comment: The QRS is isoelectric in multiple limb leads; if anything, the QRS vector is pointed back toward lead aVR. The tall R in V₁ is considered the equivalent of a posterior wall Q wave (perhaps you would see a Q if you positioned a V lead on the patient’s back). Posterior or posterolateral MI may be caused by occlusion of the circumflex artery (see Fig 2.8). There appears to be active ischemia, with persistent ST elevation and chest pain. An additional finding is tall, peaked Ts in V₂ and V₃; these may be the hyperacute T waves of acute ischemia. Many with lateral wall MI have minimal ECG change, and minimal creatine kinase elevation indicates a small infarct. The extent of ECG changes in this case suggests a sizable lateral infarct.

The presence of Q waves does not mean that the MI is complete; continued pain and ST elevation just 3 hours from the onset of symptoms are indications for reperfusion therapy.

82. Interpretation: Probably nodal rhythm, 70/min (no P waves seen). QRS .08, QT normal. Axis 0°. Abnormal due to rhythm and NSST-TCs.

Comment: Regular rhythm with no Ps and a narrow QRS complex—probably nodal. Because of the rate, it could be called an accelerated nodal rhythm.

I agree that the regional T inversion in inferolateral leads could be non-Q MI. Because the T waves are not deeply and symmetrically inverted (the usual case with anterior non-Q MI), I am not making that diagnosis. It is a diagnosis the

clinician could make if the patient has ischemic chest pain and elevation of cardiac enzymes.

83. Interpretation: AF 130/min. QRS .08, QTc .38. Axis 65°. Abnormal due to AF with rapid ventricular response and NSST-TCs. Cannot exclude tachycardia-induced ischemia.

Comment: I did not comment on the QT interval; it is hard to measure with a variable R-R interval. With longer R-Rs, it does not seem long. The ST depression could be ischemic, precipitated by the rapid rate. It is not wrong to raise that possibility in the ECG report. But there are other possible causes of ST depression such as digoxin or LVH; tachycardia can aggravate ST depression from any cause. I prefer to call the ST-T changes nonspecific and leave the diagnosis to the clinician. Follow-up: This patient had a pulmonary embolus.

84. Interpretation: ST 120/min. PR .18, QRS .10, QT long for the rate (QTc = .50). Axis 30°. Abnormal due to acute inferior MI with reciprocal ST depression in anterolateral leads.

Comment: The ST elevation in the inferior leads is less prominent than the ST depression in anterolateral leads. Nevertheless, *ST elevation defines the location of the MI*. This patient had occlusion of a large right coronary artery, and the other vessels were normal. The presence of reciprocal ST depression identifies an inferior infarction as a large one. ST elevation and pain indicates transmural ischemia and infarction in progress, usually with (total) occlusion of the coronary artery.

85. Interpretation: NSR 80/min. PR .14, QRS .07, QT normal. Axis 0°. Probably normal ECG; small inferior Qs noted.

Comment: The Qs are not deep and wide enough to diagnose MI but are worth mention. Before he starts the new exercise program, he should have a stress test. With the flat STs in inferolateral leads, the chance of a false positive study may be higher. Combining the exercise ECG with a perfusion scan or echocardiogram would avoid this and provide additional reassurance about the inferior Qs. (The myocardial scar does not take up isotope, nor does it contract.) A baseline ST segment abnormality is one indication for combining the stress test with imaging.

86. Interpretation: NSR with PVCs, PR .18, QRS .10, QT normal. Axis 45°. Abnormal due to LAA. Small inferior Qs noted.

Comment: Can you be sure these are PVCs? I think so. There are glitches in the ectopic beats in II and III, and in aVL and aVF that are probably P waves; they come on time and have the same axis as the other Ps. As the ectopic beat does not reset the sinoatrial (SA) node pacemaker, there is a *compensatory pause* following the PVC. AV dissociation makes these PVCs, not PACs with aberrancy.

The P in V₁ is biphasic, and it is broad and notched in lead II. Even in the

absence of other abnormalities, LAA is an important finding in a patient with hypertension. It has been described as the earliest ECG evidence for hypertensive heart disease, appearing much sooner than other signs of LVH. I would be concerned about inadequate control of this patient's hypertension.

- 87. Interpretation: SB 50/min with a burst of wide-complex tachycardia at 150/min, probably VT. PR .36, QRS .20, QT normal. Axis 30°. Abnormal due to rhythm, 1° AV block, LBBB.**

Comment: Do not let the arrhythmia—a dramatic event admittedly—distract you from reading the rest of the ECG. The paroxysmal tachyarrhythmia looks like VT, but I may be wrong. Without AV dissociation, an atrial arrhythmia with aberrant conduction is always a possibility. In this case, the ventricular rate is 150/min, the typical rate of atrial flutter with 2:1 block. Look at V_2 ; in the fourth to sixth beats I think you may see flutter waves at 300/min. And in V_4 , the last beat is followed by a tiny P that is not conducted. But it still looks like VT to me. Get an echocardiogram; with VT you would expect to see depressed LV function.

- 88. Interpretation: NSR with ventricular pacing (AV sequential pacer), 95/min. QRS .16, QT long for the rate (QTc .48). Abnormal due to rhythm, RBBB + LAFB pattern in paced beats.**

Comment: Most pacers that are positioned at the apex of the right ventricle produce an LBBB complex (the RV is depolarized first, the LV last; see Fig 2.4). As this is the rule, I do not usually comment on the QRS morphology of paced beats, although doing so is not a mistake. This patient's RBBB + LAFB is an unusual finding. The wire is pacing the LV. There are a few causes of LV pacing: (1) an RV lead may erode through the septum to the LV; (2) the pacing electrode may have been positioned in the coronary sinus (which courses behind the LV); (3) an epicardial electrode could have been screwed into the surface of the LV (as opposed to a transvenous, intracardiac electrode). This can be sorted out with previous ECGs and a chest x-ray. Is there an infarct pattern? With the pacemaker as the origin of the QRS, I would be reluctant to call the inferior Q waves significant, even with the RBBB pattern.

- 89. Interpretation: Low atrial pacemaker 70/min. PR .16, QRS .09, QT normal. Axis 15°. Abnormal due to NSST-TCs. Consider inferior ischemia or non-Q MI. U wave noted, and there is QT-U prolongation.**

Comment: The P waves are negative in III and aVF (a low atrial pacemaker). Compare this with ECG No. 82. The T in lead III looks more like a non-Q MI in this tracing, so I raise that possibility. In the absence of Qs, the diagnosis of MI is rarely made from the ECG alone. It requires ECG, clinical history, and enzyme changes. She needs further evaluation. Start by finding a previous ECG for comparison. Don't let her go home until this is worked out, as this may be an acute coronary syndrome.

90. Interpretation: NSR 90/min. PR .14, QRS .09, QT normal. Axis 20°. Abnormal due to PRWP, and small inferior Qs.

Comment: I am not sure about the diagnosis of anterior MI. There appear to be small R waves in the precordial leads. The loss of R in V₅ is probably from lead position. You would expect V₅ to have an appearance somewhere between that of V₄ and V₆. It could be that the electrode for V₅ was placed an interspace too low on the chest wall. A repeat ECG, or a previous tracing, might show a larger R in V₅, confirming PRWP rather than anterior MI.

I have not included many comparisons with previous ECGs in this exercise because of space. Comparison with previous ECGs should always be a part of the ECG report.

91. Interpretation: NSR 60/min. PR .18, QRS .16, QT normal. Axis -60°. Abnormal due to RBBB + LAFB, and anterior MI of uncertain age.

Comment: The small initial R wave in inferior leads makes LAFB more likely than inferior MI. This is another example of our ability to diagnose MI in the presence of RBBB. There is distortion of P waves in precordial leads, an artifact.

92. Interpretation: NSR 90/min. PR .14, QRS .08, QT normal. Axis 15°. Abnormal due to NSST-TCs.

Comment: I see a bit of ST elevation in V₂. I doubt that it means anything, and I would not have called this an abnormal ECG if that was the only finding. In this case, there are T wave changes in inferolateral leads. As they are nondiagnostic, they are “nonspecific.”

93. Interpretation: ST 120/min. PR .16, QRS .09, QT normal. Axis 60°. No obvious abnormality, but there is marked baseline artifact; consider repeat ECG.

Comment: What a mess! Some would discard it as unreadable. But the ECG may have been done at an important time in this patient’s life, perhaps during chest pain. If you look carefully, you can make a number of observations (note my measurements). I am also confident that there are no Qs or major ST-T changes. This may be electrical artifact—a technical problem with the ECG machine. But it could also be caused by shivering or tremor.

94. Interpretation: NSR 60/min. PR .22, QRS .09, QT normal. Axis 0°. Abnormal due to 1° AV block, NSST changes and possible LAA. Small inferior Qs noted.

Comment: The minimal ST depression in V leads is a soft call. Look at how broad and notched the P waves are in leads II and V₂ and V₃, another soft finding, but worth noting with the history of hypertension. The inferior Qs are borderline. Another possible abnormality is the early transition in V₂. Posterior MI is one cause of this, but tall Rs are usually seen in V₁ as well. He was

referred because of the heart attack pattern on his ECG. To sort this out, my first step would be to obtain an echocardiogram (followed by stress perfusion imaging if this leaves uncertainty). I am expecting LVH to be the only abnormality.

95. Interpretation: NSR 70/min. PR .18, QRS .08, QT normal. Axis -30° . Abnormal due to LAD, inferior MI of uncertain age, and NSST-TCs.

Comment: Compare these Qs with the last patient's.

96. Interpretation: Accelerated junctional rhythm 90/min. QRS .10, QT normal for the rate. Axis 30° . Abnormal due to rhythm, probable acute inferolateral MI. Cannot exclude pericarditis. Clinical correlation needed.

Comment: There are no P waves, the rhythm is regular, and the QRS complexes are narrow. Acute MI may be complicated by a variety of supraventricular arrhythmias (most commonly ST, AF, and rapid nodal rhythms). Reciprocal ST depression would make the diagnosis of inferior MI more certain, but he does not have it.

Another possibility is that the diffuse inferolateral ST elevation is pericarditis. Pericarditis also may provoke supraventricular arrhythmias. In this age group acute pericarditis is uncommon. If the patient has typical ischemic pain—not pleuritic pain—that is all the clinical correlation the patient's doctor needs to treat him for acute MI. As the ECG reader, I am giving responsibility for the final diagnosis to the treating clinician.

97. Interpretation: SB 55/min. PR .18, QRS .09, QT-U long for the rate. Axis 80° . Borderline due to NSTWCs; U wave and tiny inferior Qs noted.

Comment: T inversion in aVL is abnormal, whereas isolated T inversion in III or V_1 is a normal finding. This is a minimal change, so I called this ECG borderline. The QT-U duration is just under half the R-R interval.

98. Interpretation: NSR 80/min. PR .18, QRS .08, QT normal. Axis 45° . Abnormal due to anterior MI of uncertain age.

Comment: It is possible that a repeat ECG would document a small initial R in V_2 and that the present findings are due to lead placement.

99. Interpretation: NSR 70/min. PR .16, QRS .09, QT normal. Axis 45° . Probably normal, IRBBB noted.

Comment: As an isolated finding, this is not enough to make the ECG abnormal; most cases of IRBBB are normal variants. But think of conditions that could cause RV volume overload when you see this pattern in one of your patients. It is unlikely that a 73-year-old has an asymptomatic ASD. In the absence of clinical evidence of RV overload, further diagnostic testing is not necessary.

100. Interpretation: Low atrial pacemaker, 70/min. PR .13, QRS .08, QT normal. Axis -20° . Borderline due to NSST-TCs.

Comment: The abnormal P axis indicates that the rhythm does not originate in the SA node; *NSR* is technically incorrect. It is probably a low atrial or coronary sinus pacemaker.

Other possibilities: (1) In some leads the PR looks short, raising the possibility of pre-excitation. But the PR is more than 0.12 second in the inferior leads, and there is no delta wave. (2) These could be retrograde Ps that originate in the upper part of the AV node. When such high nodal rhythms cause a P that precedes the QRS, the PR interval is usually shorter than it is in this case. Low atrial rhythms with negative Ps in the inferior leads are not considered clinically significant. They point to no structural heart disease and have no clinical consequences.

A potentially noteworthy finding is early transition of the R wave in precordial leads. Posterior MI can do this, but there are usually inferior Qs as well. RVH is another cause, but the tall R should be seen in V_1 , as well as an S in V_5 . Lead misplacement is a common cause of early transition.

101. Interpretation: NSR 70/min. PR .16, QRS .10, QT normal. Axis 60° . Normal ECG.

Comment: T wave inversion that is limited to V_1 or to III is not considered abnormal. Similarly, an isolated Q in III is not abnormal. I suppose that you could comment that tiny inferior Qs are noted while still calling it a normal ECG. But you do not have to, and you will not be doing him any favor with this insurance exam.

102. Interpretation: Blocked PAC.

Comment: Look carefully at the T wave that precedes the pause. It is different from the other Ts, and the distortion is the ectopic P wave. Blocked PACs are commonly responsible for pauses and are diagnosed when distortion of the preceding T wave is recognized.

103. Interpretation: The rhythm strip shows AV nodal Wenckebach (Mobitz I second-degree block).

Comment: There is progressive lengthening of the PR before the blocked beat, and the PR that follows the dropped beat is shorter (see Fig 1.6.). As the level of block is the AV node, pacemaker therapy will be unnecessary. Progression to complete heart block would be unusual.

104. Interpretation: NSR with ventricular bigeminy 90/min. PR .23, QRS .08, QT normal. Axis -40° . Abnormal due to rhythm, 1° AV block, LAD, probable inferior MI of uncertain age.

Comment: Features that support a diagnosis of PVCs: wide complexes, QRS axis opposite that of the T wave (i.e., upright QRS, inverted T), uniphasic QRS.

Features suggesting PACs with aberrancy: the initial vector of the ectopic beats is the same as that of normal beats, at least in the precordial leads. Because we cannot see P waves near the ectopic beats (looking for AV dissociation), we cannot be sure. But they look like PVCs to me. There is a small R in II, but Qs in 2 of 3 inferior leads probably indicates MI.

105. Interpretation: NSR 90/min. PR .16, QRS .14, QT normal. Axis -70° . Abnormal due to RBBB, LAFB, possible RVH.

Comment: The conduction abnormality adds uncertainty, but the tall R in V_1 and deep S in V_6 suggests RVH.

106. Interpretation: NSR 90/min. PR .16, QRS .09, QT normal. Axis 30° . Borderline ECG due to possible inferior MI of uncertain age. Early repolarization noted.

Comment: The Qs are borderline. Early repolarization is not considered an abnormality. It is a common finding in thin, young athletes (which this man is not). Roughly 20% of MIs are clinically silent. This patient needs further evaluation.

107. Interpretation: NSR 70/min. PR .14, QRS .08, QT long with QTc .50 Axis 70° . Abnormal due to anterior non-Q MI and long QT interval.

Comment: Ischemia is one cause of long QT interval, and patients who have it may have a greater risk of VT during acute MI. Thrombolytic therapy is not indicated in the absence of chest pain and ST segment elevation. But he should be anticoagulated (aspirin, clopidogrel, and heparin—then add a IIb/IIIa inhibitor if troponin is elevated), and should have angiography.

108. Interpretation: NSR 95/min. PR .19, QRS .08, QT borderline for the rate. Axis 10° . Abnormal due to acute inferior MI.

Comment: Yes; ST elevation indicating transmural infarction is the usual ECG indication for urgent reperfusion (angioplasty/stenting is the first choice, but it depends on your setting). The other ECG indication for reperfusion therapy—not present in this case—is new bundle branch block with acute MI. This is a big inferior MI, based on the amount of ST elevation in inferior leads plus reciprocal ST depression in lateral leads (see Fig 2.13).

109. Interpretation: Atrial flutter with 4:1 conduction, 75 beats/min QRS .09, QT long for the rate (QTc .50). Axis 80° . Abnormal due to the rhythm, long QT, and NSST-TCs. Small inferior Qs noted, cannot exclude anterior MI.

Comment: The voltage in V_5 suggests LVH; it just misses being high enough. Because she is on digoxin, the ST sagging counts less for LVH. It looks more like digitalis effect, though a bit deep. There is poor R wave progression in V_{1-3} then abrupt transition in V_4 ; this is probably due to lead placement. A case could be made for old anteroseptal MI with Qs in V_{1-2} .

110. Interpretation: NSR with Wenckebach (2° heart block, Mobitz I) and 3:2 conduction. QRS .16, QT normal. Axis -20° . Abnormal due to rhythm and LBBB.

Comment: A rhythm strip would help, but we can make a diagnosis from this tracing. Look at the P waves in aVF. The first complete cycle has a long PR, and the last beat has a much longer PR, then some distortion of the T wave (due to the P wave, which comes on time). There is a pause; the next beat (now we are into V_3 —this is a continuous tracing) has a short PR.

I have told you that you cannot diagnose acute MI in the presence of LBBB, but this may be an exception. The ST elevation in III and aVF is suggestive. Wenckebach is a common arrhythmia with inferior MI (see ECG No. 103), and the patient is having chest pain. New bundle branch block with acute MI is an indication for reperfusion therapy. She had immediate catheterization, which showed an occluded right coronary artery; it was opened with a balloon and stented.

111. Interpretation: SB 55/min. PR .14, QRS .14, QT normal. Axis -20° . Abnormal due to LBBB. Since the previous ECG, heart block and inferior ST elevation have resolved and there is new T inversion.

Comment: This follow-up tracing allows us to be sure that acute MI was the illness at presentation. Her doctor was right to apply reperfusion therapy. There was a subsequent, small rise in cardiac enzymes.

Conduction abnormalities caused by acute MI tend to resolve promptly with successful reperfusion therapy. That was the case with her AV nodal block. The fact that the LBBB did not resolve suggests that it was an old problem.

112. Interpretation: ST 100/min. PR .15, QRS .09, QT normal. Axis 0° . Abnormal due to LAA, and LVH with repolarization changes.

Comment: LVH: voltage in V_2 , LAA, and lateral ST-T changes. There is a tall P in II (in addition to the biphasic P in V_1), but it's not enough to also call RAA.

113. Interpretation: ST 100/min. PR .20, QRS .10, QT borderline (QTc .45). Axis -45° . Abnormal due to LAD, anterior and inferior MI of uncertain age.

Comment: I do not usually diagnose LAFB when there are inferior Qs; instead, I indicate left axis deviation. This patient has had two MIs. Neither was managed with reperfusion therapy, and he now has ischemic cardiomyopathy. Patients with this diagnosis usually have a history of MI and/or Q waves on the ECG. By contrast, those with idiopathic, dilated cardiomyopathy do not have Q waves or a clinical history of MI.

114. Interpretation: AF 160/min. QRS .07, QTc .47. Axis 70° . Abnormal due to AF and a rapid ventricular response, and NSST-TCs.

Comment: The ST-T changes probably are rate related, but I cannot exclude active ischemia. She probably has paroxysmal AF. Workup: rule out anemia and hyper-

thyroidism, and get an echocardiogram to assess left atrial size and LV function, and to screen for other structural abnormalities. She should be on warfarin.

115. Interpretation: ST with PACs, 120/min. PR .12, QRS .16, QTc .50. Axis 90°.

Abnormal due to long QT, RBBB, ST elevation consistent with acute anterior ischemia or MI.

Comment: She has the clinical syndrome of MI with two ECG indications for reperfusion therapy: possibly new bundle branch block and ST segment elevation. Multicenter trials have shown that reperfusion therapy improves the survival of elderly patients with MI.

116. Interpretation: NSR 80/min. PR .12, QRS .08, QTc .50. Axis 20°. Abnormal due to QT interval prolongation.

Comment: You have looked at a number of ECGs with borderline QT prolongation. This seems frequently the case when the underlying rhythm is fast. The QT prolongation on this ECG is the real thing. Both phenothiazines and tricyclic antidepressants may cause QT prolongation.

117. Interpretation: ST 120/min. PR .14, QRS .09, QT normal for the rate. Axis 120°. Abnormal due to RAD and RVH.

Comment: This young woman probably has Eisenmenger's syndrome. In addition to a murmur, I would expect to find clubbing of her fingers and a right ventricular heave. Lethargy may be due to polycythemia, and would be treated with phlebotomy.

118. Interpretation: NSR 75/min. PR .12, QRS .09, QT normal. Axis 60°. Abnormal due to biatrial abnormality and LVH with repolarization changes.

Comment: I count 6 points for LVH: LAA plus ST-T changes. Voltage just misses (see Table 2.1). This is the typical ECG pattern for aortic stenosis.

119. Interpretation: AF 60 to 70/min. QRS .10, QT normal. Axis 20°. Abnormal due to rhythm, NSST-TCs, and possible LVH.

Comment: There is high voltage (V_5), but no other criterion for LVH. This is a good example of J-point depression with upsloping STs (lead V_6). He has Marfan's syndrome and aortic regurgitation. An echocardiogram showed that the LV was dilated and thickened, but this did not cause the strain pattern that is common with aortic stenosis (see ECG No. 118).

120. Interpretation: Probable junctional bradycardia (no Ps seen). QRS .09, QT normal. Axis 45°. Abnormal due to rhythm, NSST-TCs and PRWP (cannot exclude anterior MI).

Comment: I cannot be sure about retrograde Ps, although they may account for the glitch at the end of the QRS in I, II, aVL, and V_2 - V_4 . Even without

retrograde Ps, nodal rhythm is the diagnosis when there are no Ps, the QRS is narrow, and the rhythm is regular. There is a tiny R wave in V_2 – V_4 so I am reluctant to make the diagnosis of anterior MI. But one of the causes of PRWP is anterior MI; mentioning that possibility is okay.

121. Interpretation: NSR 85/min. PR .20, QRS .14, QT normal. Axis -60° . Abnormal due to RBBB + LAFB, ST elevation indicating acute anterior ischemia, probably MI.

Comment: You can diagnose acute infarction in the presence of RBBB. It seems, at first glance, that ST elevation is limited to V_2 , but there probably is elevation in V_1 and V_3 as well. Reperfusion therapy is not too late 6 hours after the onset of MI; 12 hours or more is too late.

122. Interpretation: NSR 80/min. PR .14, QRS .14, QT long for the rate (QTc .50). Axis -60° . Abnormal due to LBBB.

Comment: Why not LVH? He has LAD, ST-T changes, possible LAA, and high voltage. But we are not able to make that diagnosis with certainty in this case (see ECG No.31 for diagnosing LVH when there is LBBB). The clinical issue is whether the patient has hypertensive heart disease. LBBB generally occurs in a setting of organic heart disease, and there is a history of hypertension. So hypertensive heart disease is likely. Get an echocardiogram to confirm LVH.

123. Interpretation: NSR 70/min. PR .20, QRS .11, QT normal. Axis -60° . Abnormal due to LAFB and PRWP.

Comment: There are small initial R waves in III and aVF; I do not think he has inferior Qs. This is a common cardiology consult. The issue can be settled with an echo or a perfusion scan. PRWP commonly accompanies LAFB.

124. Interpretation: NSR 65/min. PR .18, QRS .10, QT normal. Axis 70° . Abnormal due to acute inferior MI.

Comment: It is a small MI given the magnitude of ST elevation. On the other hand, there is reciprocal ST depression (V_2 and aVL). Should she be treated? It is a borderline case. I would probably not use thrombolytic therapy; her age increases the risk of intracranial bleeding, and this looks like a small (low-risk) MI. There are reasonable people in the business who would take her directly to the catheterization lab. A lot depends on other clinical circumstances and how she feels about treatment.

125. Interpretation: NSR 75/min. PR .20, QRS .10, QT long (QTc .54). Axis 45° . Abnormal due to long QT and NSST-TCs.

Comment: The QT interval is clearly longer than half the RR interval. She may be on thiazides (check electrolytes including magnesium). She may also be taking an antiarrhythmic agent that prolongs the QT, such as sotalol, which is used to treat paroxysmal AF (see Table 1.2). The shape of the STs in V leads suggest ditalis effect as well.

126. Interpretation: Multifocal atrial tachycardia (MAT), 130/min. PR variable. QRS .08, QT normal. Axis -30° . Abnormal due to rhythm, LAD, and low QRS voltage.

Comment: MAT most commonly occurs in patients with obstructive lung disease. Verapamil is the first choice for control of the ventricular rate. Digoxin may also be used, but beware of digitalis toxicity, as patients with obstructive lung disease seem especially sensitive to the drug.

127. Interpretation: Nodal bradycardia, 50/min. QRS .10, QT normal. Axis 20° . Abnormal due to the rhythm and inferior ST elevation; cannot exclude ischemia.

Comment: The sharp glitch just beyond the peak of the T wave in leads II, III, and aVF looks like a retrograde P wave. ST changes after heart surgery are difficult to interpret. They are usually caused by surgery-induced pericarditis; many patients have a pericardial friction rub during the few days after surgery. In this case, the isolated changes in inferior leads appear ischemic.

128. Interpretation: NSR 80/min. PR .16, QRS .08, QT normal. Axis 45° . Abnormal due to acute lateral MI.

Comment: ST elevation is limited to leads I and aVL and V_{4-6} , and there are reciprocal changes (ST depression) in inferior leads.

129. Interpretation: NSR 90/min with PVCs. PR .16, QRS .10, QT normal. Axis -50° . Abnormal due to LAA, LAFB, anterior MI of uncertain age.

Comment: There is a P wave at the end of the premature beat in I and II; the ectopic beat does not reset the atrial rhythm. AV dissociation identifies the ectopic beat as ventricular. LAA: in addition to the negative P in V_1 , the Ps are notched in inferior leads.

130. Interpretation: NSR with sinus arrhythmia, 80/min. PR .10, QRS .08, QT normal. Normal ECG; short PR interval noted.

Comment: This is a nice demonstration of sinus arrhythmia, a sign of good cardiac health. She also has a short PR interval but no delta wave. This is a variant of preexcitation known as the Lown-Ganong-Levine (LGL) syndrome. The LGL variant does not cause arrhythmias (Chapter 1). Isolated T inversion in III and/or V_1 is a normal finding.

131. Interpretation: ST 110/min. PR .18, QRS .08, QT normal (QTc .43). Axis -10° . Abnormal due to ST elevation in anterolateral leads and diffuse PR depression; probable pericarditis, but cannot exclude ischemia. Clinical correlation needed. Small inferior Qs noted.

Comment: The STs have a (normal) upwardly concave shape, and there is ST elevation in multiple vascular distributions. Furthermore, there may be PR segment depression in I, II and V_{2-5} ; compare the segment to the baseline before the P wave (see Fig 2.15). Pericarditis is likely. Take a careful history

and listen for a friction rub. Also, find an old ECG for comparison in case this is early repolarization (though it does not look like it to me—the STs are too high). If possible, get an emergency echocardiogram—normal anterior and lateral wall motion would exclude ischemia (acutely ischemic myocardium does not contract).

132. Interpretation: ST 110/min. PR .20, QRS .16, QT long for the rate. Axis 120°. Abnormal due to the rhythm, RBBB + LPFB, anterior MI of uncertain age.

Comment: The P waves are not obvious: I believe I see them in V₁. This is another example of MI diagnosis in the face of RBBB. Before the anatomy of the infranodal conduction system was understood, the fascicular blocks were called peri-infarction block. Most cases of fascicular block are not caused by MI, but this may be a case of true peri-infarction block.

Perhaps the worst prognostic finding on this ECG is sinus tachycardia. Recall that resting tachycardia may indicate poor LV function after MI. An anterior MI that injures enough of the interventricular septum to cause bifascicular block is probably a large one.

133. Interpretation: NSR 75/min. PR .16, QRS .09, QTc .60. Axis 60°. Abnormal due to long QT, deep, symmetrical T wave inversion consistent with anterolateral; non-Q MI.

Comment: The T wave changes are typical of non-Q wave infarction. Some patients with these findings do not have elevated cardiac enzymes. For this reason, I do not make the diagnosis of MI on the ECG report, but leave that to the clinician who is evaluating all the data. Q waves are different: with Qs you can make the diagnosis of MI.

This patient with neurological symptoms had an intracranial bleed, and these ECG changes are a relatively common complication of that illness. In addition to deep T inversion, marked prolongation of the QT is typical. The ECG changes come from the heart, not the head. The presumed mechanism is massive catecholamine discharge caused by the acute bleed, leading to severe vasoconstriction, and subendocardial ischemia. Pathologic studies have shown subendocardial myolysis and an absence of coronary obstructive disease.

134. Interpretation: ST, 110/min. AV sequential pacemaker with ventricular pacing.

Comment: This looks like LBBB. But pacer spikes are apparent in II, aVF, aVR, and V₄–V₆.

How can you have tachycardia with a pacemaker? Is this a runaway pacer? With VVI units (single chamber, ventricular sensing and pacing), the pacer is set to fire at a fixed rate, usually 70–75/min. But with the DDD pacer (dual chamber, with atrial and ventricular sensing and pacing), the pacemaker will follow the atrium's lead, and sinus tachycardia with ventricular pacing is possible. There is an upper rate limit, which is usually set at 120–130/min.

Dual-chamber pacing is particularly good for this elderly patient with heart failure. She is able to raise her heart rate with exercise, and atrial contraction is preserved. Loss of atrial contraction may cause cardiac output to fall 20% or more in a setting of poor LV function or LV hypertrophy.

135. Interpretation: NSR 80/min. PR .18, QRS .08, QT normal. Axis 85°. Abnormal due to low QRS voltage, inferolateral ischemia, probably acute MI. Cannot exclude previous septal MI.

Comment: As the ST elevation involves multiple vascular distributions (inferior and lateral), could this be pericarditis? There is no PR segment depression (see ECG No. 131 and Fig 2.15). The reciprocal ST depression in aVL, V₁, and V₂ makes ischemia the likely diagnosis (reciprocal changes are not seen with pericarditis; see Table 2.4).

Should he have thrombolytic therapy? The absolute magnitude of ST elevation is not that great, suggesting this is a small MI. But there is reciprocal ST depression, a marker of larger inferior MI. ST elevation in V₅ and V₆ suggests that this man's right coronary artery supplies a portion of the lateral as well as the inferior wall. On balance, I suspect this is a large MI. At age 56, he should have reperfusion therapy. If there is doubt about pericarditis, angioplasty would be safer than thrombolytic therapy.

136. Interpretation: NSR 95/min with PVCs. PR .18, QRS .10, QT long (QTc .48). Axis 20°. Abnormal due to long QT, LAA, and NSST-TCs.

Comment: As he was having chest pain at the time of the ECG, the ST-T changes could be ischemic (a clinical diagnosis). You can be more certain about ischemia by comparing this with an ECG taken later, after resolution of chest pain. He also was in pulmonary edema. After diuresis, the LAA resolved; these P wave changes may vary with left atrial pressure.

137. Interpretation: NSR 80/min. PR variable from .06 to .12, QRS variable from .06 to .10, QT normal. Axis variable. Abnormal due to intermittent pre-excitation.

Comment: I have mentioned that conduction across an accessory pathway may be intermittent. In this case it seems to vary with the respiratory cycle. Note the T wave changes that appear with the delta wave; it should be no surprise that changing the sequence of ventricular activation may also change the sequence of repolarization.

138. Interpretation: NSR 70/min with Mobitz I, 2° AV block (Wenckebach) and 4:3 conduction. PR variable, QRS .08, QT normal. Axis -10°. Abnormal due to rhythm, inferior MI, possibly acute.

Comment: If we had serial ECGs for comparison, we would call this inferior MI with evolutionary changes rather than acute MI. There is some residual ST

elevation and reciprocal ST depression, but Qs have developed. AV nodal block may persist for days or even a couple of weeks after the acute inferior infarction. The node usually recovers, either because of good collateral flow or because of relaxation of vagal tone.

139. Interpretation: ST 120/min. PR .08, QRS .08, QT normal. Axis 45°. Abnormal due to short PR, probable LGL syndrome, and NSST-TCs.

Comment: Some patients with pre-excitation do not have a delta wave. Presumably, their bypass tract is near the AV node, so that the sequence of ventricular activation is near normal. (This is the Lown-Ganong-Levine syndrome caused by pre-excitation through the paranodal James bundle. It does not cause PSVT. See ECG No. 130)

140. Interpretation: NSR 80/min. PR .08, QRS .10, QT long for the rate. Axis 10°. Abnormal due to pre-excitation (WPW) and NSST-TCs. Since the prior ECG, a delta wave and anterior T inversion have developed.

Comment: Patients with pre-excitation may have multiple accessory pathways; this patient has switched from one to another with the change in heart rate. There has been a change in the T wave and QT interval with the change in AV conduction.

141. Interpretation. I: NSR 90/min. PR .18, QRS .11, QT long (WTc .52). Axis 30°. Abnormal due to biatrial abnormality, IVCD, and long QTc.

142. Interpretation: Multifocal atrial tachycardia 120/min. PR variable, QRS .09, QT normal. Axis 110°. Abnormal due to MAT, RAD, and PRWP.

Comment: This much variability in the P waves and PR interval indicates either wandering atrial pacemaker (with heart rate <100; ECG No. 68) or MAT. The delay in R wave progression is consistent with her obstructive lung disease. With a deeper S wave in V₆, you could argue for RVH.

143. Interpretation: ST 110/min. PR .16, QRS .08, QT long (QTc .48). Axis 100°. Abnormal due to rhythm, acute inferolateral MI with reciprocal ST changes.

Comment: The ECG computer read this as possible anterior subendocardial ischemia, in addition to inferior MI (I find that I have to change the computer's interpretation in more than half of the ECGs I read). Multiple studies have tested the significance of reciprocal ST depression during inferior MI. The one thing that they agree on is that it is a marker of large infarction. Based on available evidence, I do not think reciprocal ST depression reliably points to multivessel coronary disease and ischemia in a second vascular distribution. Instead, it simply indicates that the infarct artery is a large one.

144. Interpretation: ST 120/min. PR .16, QRS .10, QT normal. Axis 90°. Abnormal due to LAA, acute anterolateral MI, and inferior MI of uncertain age.

Comment: This is his second MI, and it is a big one. With cardiogenic shock, the prognosis is poor unless reperfusion therapy can be accomplished quickly. For reperfusion therapy to work, the infarct artery should be opened within 6 hours of the onset of pain. Beyond that, there is much less chance for success. Move in the direction of the cardiac catheterization laboratory as soon as you make the diagnosis of cardiogenic shock. *Do not wait to see if thrombolytic therapy will work.* If there is no catheterization laboratory in your hospital, start rT-PA therapy and call the helicopter for emergency transfer.

145. Interpretation: NSR 90/min. PR .14, QRS .09, QT normal. Axis 20°. Abnormal due to diffuse ST elevation, probably pericarditis. Small inferior Qs noted.

Comment: ST elevation is seen in anterior, lateral, and inferior leads. The normal upward concavity of the STs is maintained. The PR segment in II may be slightly below the baseline (compared with the segment just before the P wave). This patient has the postpericardiotomy syndrome, acute pericarditis that occurs 1–4 weeks after heart surgery. He presents typically with fever, pleuropericardial pain, and flu-like symptoms. The illness is often mistaken for pneumonia, as patchy infiltrates are possible. The white cell count is usually normal. The key to the diagnosis is the sedimentation rate, which is usually above 100mm/hr. He responded to prednisone therapy.

146. Interpretation: ST 100/min, PR .16, QRS .07, QT normal. Axis 45°. Abnormal due to diffuse ST elevation, probably acute ischemia (both anterior and inferior MI).

Comment: The ST changes in the anterior leads have the “tombstone” appearance, a reliable sign of transmural ischemia. On the other hand, the ST elevation in inferior leads is impressive, and diffuse, multiregion ST elevation is one of the signs of pericarditis. Is this simultaneous anterior and inferior infarction? That would be an unusual coincidence. Lead aVL helps a bit, as there is a hint of reciprocal ST depression (a sign of ischemia). Her emergency angiogram showed acute occlusion of the left anterior descending artery (to the anterior wall). She had chronic, asymptomatic occlusion of the right coronary artery (to the inferior wall), and the distal vessel was supplied by collaterals from the left anterior descending. When that vessel closed, she thus lost flow to both the anterior and inferior walls (see ECG No. 30).

147. Interpretation: Nodal tachycardia, 105/min. QRS .10, QT long (QTc .48). Axis 90°. Abnormal due to rhythm, NSST-TCs, and long QT.

Comment: Retrograde P waves distort the T waves, so this is probably a nodal rhythm. However, the P waves are upright, suggesting an origin high in the atrium. I cannot explain this; retrograde Ps originate in the AV node, and therefore have negative voltage in leads II, III and aVF. I am still calling it a nodal rhythm.

148. Interpretation: Possibly accelerated idioventricular rhythm, although nodal rhythm is possible, 70/min. QRS duration is variable, QTc .48. Axis is variable. Abnormal due to the rhythm, and acute anterolateral MI.

Comment: The arrhythmia is not readily apparent. There are narrow QRS complexes with a normal axis in aVR, aVL and aVF that may be preceded by P wave. The wider complex beats with a leftward axis could be an accelerated idioventricular rhythm (also called slow VT). It is hard to be sure of this without a long rhythm strip. Regardless of the rhythm, this ECG identifies a huge anterior MI with “tombstone” ST segments.

149. Interpretation: Sinus arrest with junctional escape rhythm, 32/min. QRS .10, QT normal. Axis 70°, abnormal due to rhythm, acute inferior ischemia, probably MI.

Comment: Junctional or nodal rhythm implies that the SA rate has slowed below that of the AV nodal pacemaker, and the AV node has assumed control. In this case, the SA pacer has slowed too much, enough that I am calling it SA arrest. This patient required a temporary pacemaker. Because the QRS is narrow, we can be sure the takeover pacemaker is in or just below the AV node. The rate is usually faster with a nodal pacer. Perhaps AV node is not working normally because of its age.

150. Interpretation: NSR 65/ min. PR .16, QRS .08, QT normal. Axis uncertain. Probably normal ECG; suspect arm lead reversal.

Comment: This is a relatively common occurrence (we staged it for this purpose with one of the technicians). A relatively young person has a bizarre axis and lateral Q waves. The axis does not fit any specific syndrome (such as RVH). Lead misplacement is the logical explanation. If you (mentally) roll lead I and aVL around the baseline, the P, QRS, and T would be upright—the equivalent of correcting the placement of the right and left arm electrodes. Another common lead misplacement involves the V leads and bizarre R wave progression across the precordium (i.e., the R in V₄ is shorter than those in V₂ and V₃).

Index

Page numbers in *italics* refer to figures and those in **bold** to tables, but note that figures and tables are only indicated when they are separated from their text references.

- aberrant conduction 29
- ablation, catheter 21–2, 23, 26–7
- accessory pathways *see* bypass tracts
- acute coronary syndromes 55
- adenosine 21
- AF *see* atrial fibrillation
- A-H interval 16, 44
- amyloidosis, cardiac 49
- angina pectoris **50**
 - chronic stable 53, 55
 - postinfarction 60
 - previous myocardial infarction 78, 220
 - ST segment changes 51–2
 - unstable 55
 - vasospastic or Prinzmetal's 55
- angiography 54, 90, 223, 228
- angioplasty/stenting 141, 229, 236
 - cardiogenic shock 251
 - inferior myocardial infarction 243
 - Wenckebach block and 244
- ankle edema *see* edema, ankle
- anterior fascicle 43
- anterior leads 5
- antiarrhythmic drugs, QT prolongation 31, 246
- anticoagulation 125, 243
- antihistamines 106, 107, 228
- aortic regurgitation 182, 245
- aortic stenosis 181, 245
- arm lead reversal 213, 252
- arrhythmias
 - atrial 18–28
 - drugs/metabolic conditions causing **32**
 - sinus 11–12
 - ventricular 28–32
 - see also specific arrhythmias*
- athletes 11
- atria, depolarization 6, 7, 32–3
- atrial abnormalities 37–8
 - see also* biatrial abnormality; left atrial abnormality; right atrial abnormality
- atrial arrhythmias 18–28
- atrial fibrillation (AF) 22, 23
 - drugs/metabolic conditions causing **32**
 - isolated systolic hypertension 79, 220
 - Marfan syndrome 182, 245
 - multiple abnormalities and 114, 229–30
 - nonspecific ST-T changes and 75, 100, 219, 226
 - paroxysmal 177, 188, 244–5, 246
 - premature ventricular contractions and 74, 219
 - previous history 117, 136, 230, 235
 - with rapid ventricular response 23, 92, 146, 223, 238
 - with slow ventricular response 23, 130, 234
- atrial flutter 22–4
 - with 2:1 block 23, 124, 232
 - with 4:1 block 23, 172, 243
 - drugs/metabolic conditions causing **32**
 - or nodal rhythm 139, 236
 - ventricular pacemaker and 86, 222
- atrial premature beats (APBs) *see* premature atrial contractions
- atrial septal defect (ASD)
 - incomplete right bundle branch block 41, 104, 227
 - primum vs. secundum 105, 227
- atrial tachycardia, multifocal (MAT) 27–8, 189, 205, 247, 250
- atrioventricular (AV) block 12–17
 - first-degree (1°) 8, 13
 - bifascicular block with 72, 218–19
 - digitalis effect and 136, 235
 - digitalis toxicity and 127, 233
 - inferolateral myocardial infarction and 83, 221
 - infranodal block with 16, 44
 - memory loss and 73, 219
 - nonspecific ST-T wave changes and 97, 225
 - poor R wave progression and 128, 233
 - sinus bradycardia and 113, 150, 229, 239
 - ventricular bigeminy and 167, 242–3
 - second-degree 13–15
 - see also* Mobitz I (Wenckebach) block; Mobitz II block
 - third-degree (complete) 17
- atrioventricular (AV) dissociation 17
 - atrial fibrillation/flutter and 22, 24
 - complete heart block and 101, 226
 - ventricular tachycardia with 30, 31

- atrioventricular (AV) node 6, 7
- atrioventricular (AV) sequential pacemaker *see*
under pacemakers (therapeutic)
- automatic focus 29
- autonomic dysfunction, heart rate
variability 12
- autonomic nervous system 11–12, 13
- AV *see* atrioventricular
- axis 4, 32–5
 - deviation *see* left axis deviation; right axis
deviation
 - torsade de pointes 30–1
 - vertical 67, 216
- Bazett's formula 9
- biatrial abnormality
 - aortic stenosis 181, 245
 - intra-ventricular conduction defect and 204,
250
 - tricuspid regurgitation 84, 221–2
- bifascicular block 43–4
 - anterior and inferior myocardial infarction
with 93, 224
 - first-degree AV block with 72, 218–19
- borderline electrocardiograms
 - incomplete right bundle branch block 104,
227
 - left axis deviation 80, 220
 - low atrial pacemaker and 163, 242
 - nonspecific ST-T wave changes 76, 160, 219,
241
 - possible inferior myocardial infarction 169,
243
 - see also* normal electrocardiograms
- bradycardia 7, 11
 - junctional (nodal) 183, 190, 245–6, 247
 - sick sinus syndrome 27
 - sinus *see* sinus bradycardia
- brady-tachy syndrome 27
- bronchitis, chronic 205
- Brugada syndrome 115, 230
- bundle branch block *see* left bundle branch
block; right bundle branch block
- bundle of His *see* His bundle
- bypass tracts (accessory pathways)
 - catheter ablation 26–7
 - drugs slowing conduction 26
 - multiple 250
 - pre-excitation through 24, 25
- cardiac cycle 6, 7
- cardiac output 11
- cardiogenic shock 207, 251
- cardiomyopathy
 - dilated 116, 230
 - hypertrophic 62, 121, 231
 - ischemic *see* ischemic cardiomyopathy
 - ventricular tachycardia/fibrillation 108, 228
- cardioversion, atrial arrhythmias 21
- chest pain
 - 30-minute duration 141, 147, 236, 238
 - 45-minute episode 110, 228
 - 1-hour episode, previous day 140, 236
 - 90-minute duration 170, 243
 - 2-hour duration 137, 173, 187, 198, 244,
246, 249
 - 3-hour duration 144, 159, 237, 241
 - 5-hour duration 171, 178, 243, 245
 - 6-hour duration 184, 206, 246, 250
 - 9-hour duration 111, 229
 - 14-hour duration 201, 249–50
 - anterior and inferior myocardial
infarction 93, 209, 224, 251
 - atrial pacemaker and 134, 235
 - dizziness and 212
 - idioventricular rhythm and 211, 252
 - lateral myocardial infarction 61
 - pericarditis vs. ischemia 194, 247–8
 - postinfarction ischemia 143, 237
 - previous myocardial infarction and 68, 78,
217, 220
 - pulmonary edema and 199, 249
 - rales and 207
 - recurring after 2 hours 102
 - ST depression and 52
 - ST elevation 54–5
 - T wave inversion 52, 53, 90, 223
 - thrombolytic therapy and 97, 225
 - vague nonspecific 128, 191
- cholecystitis 66
- chronic obstructive pulmonary disease
(COPD) 168, 243
 - multifocal atrial tachycardia 189, 205, 247,
250
 - poor R wave progression 48
- cocaine 55
- confusion 127, 196, 233
- cor pulmonale 47, 232, 236
- coronary artery
 - anatomy 49
 - spasm 50, 55
- coronary bypass surgery
 - postpericardiotomy syndrome 208, 251
 - ST changes after 190, 247
- cough, chronic 139
- cyanosis 180

- delta wave 24, 25, 26, 95, 224–5
 intermittent pre-excitation 200, 249
 in later ECG 203, 250
 pre-excitation without 202, 250
 vs. left bundle branch block 129, 233–4
 vs. Q waves 61, 62
- depolarization, wave of 4–6, 7
- diabetes
 atrial fibrillation 92, 223
 poor R wave progression 112, 229
- digitalis effect
 atrial fibrillation 75, 100, 219, 226
 first-degree AV block and 136, 235
 paroxysmal atrial fibrillation 188, 246
 sinus bradycardia 113, 229
 small inferior Qs and 117, 230
- digitalis toxicity 15, 127, 223, 233
- digoxin
 atrial fibrillation and 74, 125, 219, 232
 atrial flutter and 172, 243
 nodal rhythm and long QTc 87, 222–3
 obstructive lung disease and 247
 wandering atrial pacemaker and 131, 234
- dilated cardiomyopathy 116, 230
- diuretics 132, 223, 234
- dizziness 109
 cardiomyopathy and 108, 228
 chest pain and 212
 not explained by ECG 81, 221
 one week history 130
 palpitations and 96, 150, 239
- drugs, causing ECG abnormalities **10, 32**
- dyspnea
 chest pain and 178, 245
 cough and ankle edema 139
 exertional 123
 pleurisy and 146, 238
- early repolarization
 borderline ECG 169, 243
 ST elevation 55, 69, 217
- ectopic beats 21, 29
see also premature atrial contractions;
 premature ventricular contractions
- edema
 ankle
 cough and dyspnea 139
 emphysema and 122, 231–2
 fatigue and 101, 226
 obstructive lung disease and 168, 243
 peripheral
 chronic lung disease and 47
 systolic murmur with 84
 pulmonary *see* pulmonary edema
- Eisenmenger syndrome 180, 245
- electrocardiogram (ECG) 35
 borderline *see* borderline electrocardiograms
 comparison with previous 240
 intervals 7–10
 normal *see* normal electrocardiograms
 protocol for reading 3, 4
 rate *see* heart rate
 rhythm *see* rhythm
 as voltmeter 4–6
- emphysema 85, 222
 ankle edema with 122, 231–2
see also chronic obstructive pulmonary
 disease
- erythromycin 106, 107, 228
- Estes scoring system, left ventricular
 hypertrophy **45, 46**
- exercise program, new 148, 238
- fascicles 43
- fascicular blocks 43–4
 left anterior *see* left anterior fascicular block
 left posterior 43, 195, 248
- fatigue 18, 89, 101, 123
- fever 86, 202, 205, 208
- fusion beat 24
- H spike 16
- heart block 12–18
 with acute myocardial infarction 18, 19
 complete (third-degree), AV dissociation
 and 101, 226
 drugs/metabolic conditions causing **32**
 fascicular 43
 first-degree 13
 His bundle recordings 16
 infranodal 12, 13, 15, 17–18
 nodal *see* atrioventricular block
 second-degree 13–15
 Mobitz I (Wenckebach) *see* Mobitz I block
 Mobitz II block *see* Mobitz II block
 third-degree (complete) 17–18
see also left bundle branch block;
 bundle branch block
- heart failure
 AV sequential pacemaker 197, 248–9
 congestive
 previous myocardial infarction and 192,
 247
 sinus tachycardia 11, 123, 232
 dilated cardiomyopathy 116, 230
 inferolateral myocardial infarction 83, 221

- ischemic cardiomyopathy 71, 176, 218, 244
 mitral regurgitation 87, 222
 multiple ECG abnormalities and 114, 229–30
- heart murmurs
- atrial septal defect with 105, 227
 - diastolic 182
 - Eisenmenger's syndrome 180, 245
 - idiopathic hypertrophic subaortic stenosis 121, 231
 - systolic 84, 87, 181
- heart rate 5, 6–7
- control 12–13
 - drugs/metabolic conditions affecting 32
- heart rate variability (HRV) 11–12
- heart sounds
- first (S₁), soft 14
 - second, splitting 41, 105, 227
- hemiblocks *see* fascicular blocks
- His bundle 6
- electrophysiology recordings 16, 44
- His-Purkinje system 12
- H-V interval 16, 44
- hydrochlorothiazide 234
- hyperkalemia 132, 234
- hypertension
- atrial fibrillation 75, 92, 219, 223
 - biatrial abnormality 204, 250
 - first degree AV and bifascicular block 72, 218–19
 - isolated systolic 79, 220
 - left atrial abnormality 38, 149, 157, 238–9, 240–1
 - left bundle branch block and 185, 246
 - left ventricular hypertrophy 94, 99, 224, 225–6
 - nonspecific ST-T wave changes 91, 157, 223, 240–1
 - paroxysmal atrial fibrillation and 188, 246
 - renal failure and 175
- hypertensive heart disease
- left atrial abnormality 38, 149, 238–9
 - left bundle branch block and 185, 246
- hypertrophic cardiomyopathy 62, 121, 231
- hypocalcemia 10
- hypokalemia 10, 223
- hypomagnesemia 31, 223
- idioventricular rhythm 17–18
- accelerated 211, 252
- incomplete right bundle branch block (IRBBB) 41
- isolated 104, 162, 227, 241
- left anterior fascicular block with 72, 105, 218–19, 227
- indigestion 89, 111, 152
- inferior leads 5
- infranodal heart block 12, 13, 15, 17–18
- intervals 7–10
- intracranial bleeding 54, 196, 248
- intraventricular conduction
- abnormalities 38–43
- intraventricular conduction defect (IVCD) 119, 231
- atrial fibrillation and 130, 234
 - biatrial abnormality and 204, 250
 - Brugada syndrome 115, 230
 - isolated systolic hypertension 79, 220
 - mild preoperative 135, 235
 - poor R wave progression and 128, 233
- intrinsicoid deflection 44, 45, 45
- ischemia
- after coronary bypass surgery 190, 247
 - anterior 48–9
 - deep T wave inversion 90, 223
 - long QT and ST elevation 178, 245
 - probable 140, 236
 - atrial fibrillation and 92, 223
 - global changes 50
 - inferior 49
 - low atrial pacemaker and 152, 239
 - postinfarction 143, 237
 - sinus arrest with junctional escape rhythm 212, 252
 - inferolateral
 - atrial pacemaker and 134, 235
 - low QRS voltage and 198, 249
 - lateral 49
 - posterolateral myocardial infarction and 144, 237
 - patterns 48–62
 - Q waves and 58–62
 - sequence of events 51, 53
 - ST depression 50–2, 53
 - ST elevation 54–7
 - subendocardial 50, 51, 52, 53, 53
 - T wave inversion 52–4
 - transmural 51, 53
 - vs.* pericarditis 60, 194, 198, 247–8, 249
- ischemic cardiomyopathy 71, 176, 218, 230, 244
- isoelectric, term 33, 50
- IVCD *see* intraventricular conduction defect
- J point
- depression 52, 53, 182, 245

- elevation 69, 82, 115, 217, 221, 230
- jugular venous distension 84
- junctional bradycardia *see* nodal bradycardia
- junctional rhythm *see* nodal rhythm
- LAA *see* left atrial abnormality
- LAD *see* left axis deviation
- LAFB *see* left anterior fascicular block
- lateral leads 5
- LBBB *see* left bundle branch block
- leads
 - misplaced 213, 252
 - polarity 39
 - spatial orientation 4, 5
- left anterior descending artery 49
- left anterior fascicular block (LAFB) 43
 - atrial septal defect 105, 227
 - congestive heart failure 192, 247
 - first-degree AV block with 72, 218–19
 - intraventricular conduction defect and 119, 231
 - left ventricular hypertrophy and 99, 225–6
 - multiple abnormalities and 114, 229–30
 - myocardial infarction and 154, 240
 - poor R wave progression and 128, 233
 - right ventricular hypertrophy 168, 243
 - silent myocardial infarction and 186, 246
 - ST elevation and 184, 246
 - supraventricular tachycardia with 70, 218
 - ventricular pacing and 151, 239
- left atrial abnormality (LAA) 37, 38
 - cardiogenic shock 207, 251
 - congestive heart failure 123, 192, 232, 247
 - intraventricular conduction defect and 119, 231
 - left ventricular hypertrophy 44, 45, 45, 175, 244
 - long QT interval and 77, 120, 220, 231
 - mitral regurgitation 87, 222
 - nonspecific ST-T wave changes and 157, 240–1
 - premature ventricular contractions and 149, 238–9
 - pulmonary edema and 199, 249
 - right ventricular hypertrophy and 122, 231–2
 - sinus bradycardia and 113, 229
- left axis deviation (LAD)
 - borderline ECG 80, 220
 - congestive heart failure 123, 232
 - dilated cardiomyopathy 116, 230
 - first-degree AV block with 97, 225
 - idiopathic hypertrophic subaortic stenosis 121, 231
 - inferior myocardial infarction and 158, 241
 - inferolateral myocardial infarction 83, 221
 - ischemic cardiomyopathy 176, 244
 - left anterior fascicular block 43
 - left atrial abnormality and 77, 220
 - left ventricular hypertrophy 44, 45, 185, 246
 - multifocal atrial tachycardia 189, 247
 - nonspecific ST-T wave changes with 65, 216
 - poor R wave progression and 112, 229
 - ventricular bigeminy and 167, 242–3
- left bundle branch 6, 43
- left bundle branch block (LBBB) 41–3
 - left ventricular hypertrophy 44, 94, 185, 224, 246
 - long QT interval and 120, 231
 - reperfusion therapy and 174, 244
 - sinus bradycardia and 150, 239
 - sinus tachycardia and 135, 235
 - vs.* intraventricular conduction defect 119, 231
 - vs.* pre-excitation 129, 233–4
 - Wenckebach block and 173, 244
 - wide-complex tachycardia and 133, 234–5
- left circumflex artery 49, 237
- left main (coronary) artery 49
- left posterior fascicular block (LPFB) 43, 195, 248
- left ventricle (LV)
 - aneurysm 89, 223
 - depolarization 6
 - strain pattern 44
- left ventricular (LV) dysfunction 30
 - after anterior myocardial infarction 89, 223
 - ventricular tachycardia/fibrillation 108, 228
- left ventricular hypertrophy (LVH) 44–6
 - aortic stenosis 181, 245
 - atrial fibrillation and 75, 92, 219, 223
 - Estes scoring system 45, 46
 - first degree AV and bifascicular block 72, 218–19
 - intraventricular conduction defect and 119, 231
 - isolated systolic hypertension 79, 220
 - left atrial abnormality 38, 77, 175, 220, 244
 - left bundle branch block and 44, 94, 185, 224, 246
 - Marfan syndrome 182, 245
 - mild hypertension 91, 223
 - mitral regurgitation 87, 222
 - poor R wave progression and 81, 221
 - right bundle branch block and 99, 225–6
- lethargy 180, 196

- limb leads 5
- long QT *see* QT interval prolongation
- low QRS voltage 47
 - atrial pacemaker and 134, 235
 - cardiac amyloidosis 49
 - inferolateral ischemia and 198, 249
 - multifocal atrial tachycardia 189, 247
 - right ventricular hypertrophy 139, 236
- Lown-Ganong-Levine (LGL) syndrome 193, 202, 247, 250
- LV *see* left ventricle
- LVH *see* left ventricular hypertrophy

- Marfan syndrome 182, 245
- MAT *see* multifocal atrial tachycardia
- memory loss 73, 219
- metabolic conditions, causing ECG abnormalities **10, 32**
- millivolt (mV) calibration marker 4, 5
- mitral regurgitation 87, 222
- Mobitz I (Wenckebach) block 14–15, 16
 - with 4:3 conduction 201, 249–50
 - after reperfusion therapy 174, 244
 - inferior myocardial infarction and 166, 173, 242, 244
- Mobitz II block 15, 16
- morphologic changes 37–62, 38–44
 - atrial abnormalities 37–8
 - delayed or poor R wave progression 47, 48
 - intraventricular conduction
 - abnormalities 38–44
 - low QRS voltage 47, 49
 - patterns of ischemia and infarction 48–62
 - ventricular hypertrophy 44–6
- multifocal atrial tachycardia (MAT) 27–8, 189, 205, 247, 250
- murmurs *see* heart murmurs
- myocardial infarction (MI) 48–62
 - anterior 48–9
 - atrial fibrillation and 100, 226
 - congestive heart failure and 123, 192, 232, 247
 - heart block with 18, 19
 - heart failure and 71, 218
 - inferior infarction with 93, 209, 224, 251
 - long QT and ST elevation 178, 245
 - peri-infarction block 195, 248
 - with persistent ST elevation 89, 223
 - right bundle branch block and 184, 246
 - ST elevation 57
 - supraventricular tachycardia and 70, 218
 - uncertain age 161, 241
 - vs.* septal 68, 217
 - anterolateral 49
 - accelerated idioventricular rhythm
 - and 211, 252
 - cardiogenic shock 207, 251
 - QT prolongation and 102, 226–7
 - right bundle branch block and 126, 232–3
 - tissue plasminogen activator therapy 103, 227
 - complete *vs.* incomplete 60
 - evolution 58–60
 - extension 60
 - heart block with 18, 19
 - inferior 49
 - anterior infarction with 93, 209, 224, 251
 - atrial fibrillation and 92, 223
 - borderline ECG 169, 243
 - first-degree AV block and 167, 242–3
 - heart block with 18, 19
 - nonspecific ST-T wave changes and 82, 158, 221, 241
 - poor R wave progression and 81, 137, 221, 235
 - reciprocal ST depression and 147, 238
 - reperfusion therapy 171, 243
 - sinus bradycardia and 141, 236
 - ST elevation 56
 - thrombolytic therapy 142, 187, 236–7, 246
 - of uncertain age 67, 216–17
 - Wenckebach block and 166, 173, 201, 242, 244, 249–50
- inferolateral 49
 - accelerated junctional rhythm 159, 241
 - atrial fibrillation and 130, 234
 - first degree AV block and 83, 221
 - idiopathic hypertrophic subaortic stenosis and 121, 231
 - reciprocal ST depression and 206, 250
 - ST elevation 56
- lateral wall 49, 60–1, 191, 247
 - possible 99, 225–6
- non-ST elevation (non-Q; subendocardial)
 - see* non-ST elevation myocardial infarction
- posterolateral, with acute lateral ischemia 144, 237
- previous
 - ischemic cardiomyopathy 176, 244
 - junctional bradycardia and 183, 245–6
 - large second infarction 207, 251
 - new ST depression after 68, 217
 - nonspecific ST-T wave changes 78, 117, 220, 230

- possible second infarction 153, 240
- premature ventricular contractions and 138, 236
- right bundle branch block and 154, 240
- ventricular pacing 151, 239
- pseudo 61–2
- reperfusion therapy *see* reperfusion therapy
- septal 68, 217
- silent 61–2, 186, 246
- sinus tachycardia and 11
- ST depression 50–2, 53
- ST elevation (Q wave; transmural) *see* ST elevation myocardial infarction
- T wave inversion 52–4
- vs.* pericarditis 233, 241
- myocardial ischemia *see* ischemia
- myocarditis 54

- narrow complex tachycardia 21, 24, 25
- nitroglycerine 225
- nodal (junctional) bradycardia
 - after coronary bypass surgery 190, 247
 - possible myocardial infarction and 183, 245–6
- nodal (junctional) rhythm 22
 - accelerated 159, 241
 - escape, sinus arrest with 212, 252
 - long QTc with 88, 222–3
 - nonspecific ST-T wave changes and 145, 237–8
 - or atrial flutter 139, 236
- nodal tachycardia 210, 251
- non-Q wave myocardial infarction *see* non-ST elevation myocardial infarction
- nonspecific ST-T wave changes (NSSTWCs) 52
 - anterior myocardial infarction and 71, 218
 - atrial fibrillation and 125, 146, 232, 238
 - atrial flutter and 172, 243
 - borderline ECGs 76, 160, 219, 241
 - digitalis effect 75, 100, 117, 136, 219, 226, 230, 235
 - digitalis toxicity 127, 233
 - dilated cardiomyopathy 116, 230
 - emphysema 85, 222
 - first-degree AV block with 97, 225
 - hypertension 91, 157, 223, 240–1
 - idiopathic hypertrophic subaortic stenosis 121, 231
 - inferior myocardial infarction and 82, 158, 221, 241
 - intraventricular conduction defect and 119, 231
 - isolated 155, 240
 - junctional bradycardia and 183, 245–6
 - left axis deviation with 65, 216
 - low atrial pacemaker and 152, 163, 239, 242
 - Marfan syndrome 182, 245
 - multiple abnormalities and 114, 229–30
 - nodal rhythm and 145, 237–8
 - nodal tachycardia and 210, 251
 - paroxysmal atrial fibrillation 177, 188, 244–5, 246
 - poor R wave progression and 112, 128, 229, 233
 - pre-excitation and 202, 203, 250
 - previous myocardial infarction 78, 220
 - pulmonary edema and 199, 249
 - sinus bradycardia and 113, 229
 - sinus tachycardia and 66, 216
 - U wave and 118, 231
 - wandering atrial pacemaker and 131, 234
- non-ST elevation (subendocardial or non-Q wave) myocardial infarction 50, 51, 53
 - long QT interval and 152, 170, 239, 243
 - low atrial pacemaker and 152, 239
 - possible 140, 236
 - sinus bradycardia with 110, 228
 - T wave inversion 52–3, 54, 90, 223
 - vs.* intracranial bleeding 196, 248
 - vs.* transmural infarction 54
- normal electrocardiograms 64, 164, 216, 242
 - isolated incomplete right bundle branch block 162, 241
 - lead misplacement 213, 252
 - Lown-Ganong-Levine syndrome 193, 247
 - small inferior Qs and 148, 238
 - see also* borderline electrocardiograms
- NSSTWCs *see* nonspecific ST-T wave changes

- obesity 92, 223
- obstructive lung disease *see* chronic obstructive pulmonary disease

- P mitrale 37
- P pulmonale 37
- P wave 6, 7
 - abnormalities 37–8
 - atrial flutter 22–3
 - axis 32–3
 - biphasic 33, 37, 38
 - broad notched 37, 38
 - premature atrial contractions and 19
 - retrograde (inverted), nodal rhythm 22
 - tall peaked 37, 39
 - ventricular tachycardia 30, 31

- wandering atrial pacemaker 27–8
- pacemaker (intrinsic cardiac) 6
 - auxiliary, in heart block 12–13, 17–18
 - low atrial 152, 163, 239, 242
- pacemakers (therapeutic)
 - atrial, with 100% capture 134, 235
 - AV sequential
 - with 100% capture 98, 225
 - and ventricular pacing 109, 151, 197, 228, 239, 248–9
 - bradyarrhythmias 27
 - Mobitz I block 166, 242
 - ventricular, atrial flutter 86, 222
- pacing spikes 98, 109, 225, 228
 - unipolar leads 134, 235
- PACs *see* premature atrial contractions
- palpitations 129, 167, 177
 - dizziness and 96, 150, 239
 - history of 200, 202
 - intermittent 95
- paper, ECG 5
 - dimensions 4, 6
 - “speed” 6
- paroxysmal supraventricular tachycardia (PSVT) 20–2
 - with aberrant infranodal conduction 29
 - vs.* ventricular tachycardia 24–6
 - Wolf-Parkinson-White syndrome 24, 26
- pauses 19, 20, 165, 242
- pericarditis
 - accelerated junctional rhythm 159, 241
 - after coronary bypass surgery 247
 - global ST segment and T wave changes 50, 54
 - postpericardiotomy syndrome 208, 251
 - ST segment elevation 55, 58
 - vs.* ischemia 60, 194, 198, 247–8, 249
 - vs.* myocardial infarction 233, 241
- peri-infarction block 195, 248
- phenothiazines 228, 245
- pleurisy 146, 198, 208, 238
- pneumonia 202, 203, 208
- poor R wave progression (PRWP) 47, 48
 - atrial fibrillation and 130, 234
 - atrial septal defect 105, 227
 - dilated cardiomyopathy 116, 230
 - emphysema 85, 222
 - inferior myocardial infarction and 81, 137, 221, 235
 - intraventricular conduction defect and 119, 231
 - junctional bradycardia and 183, 245–6
 - multiple abnormalities and 114, 229–30
 - nonspecific ST-T wave changes and 112, 128, 229, 233
 - obstructive lung disease 205, 250
 - previous myocardial infarction and 153, 240
 - QTU interval prolongation and 81, 221
 - silent myocardial infarction and 186, 246
 - tricuspid regurgitation 84, 221–2
- posterior fascicle 43
- postpericardiotomy syndrome 208, 251
- potassium supplements 132, 234
- PR interval 6, 7–8
 - depression, pericarditis 55, 58
 - drugs/metabolic conditions affecting 10
 - first-degree AV block 13
 - nodal and infranodal partitioning 16
 - prolonged 8, 10
 - second-degree AV block 14, 15
 - short 193, 202, 247, 250
 - soft first heart sound (S₁) and 14
 - Wolff-Parkinson-White syndrome 24, 25, 26
- precordial leads 5
- pre-excitation 24–7, 95, 224–5
 - intermittent 200, 249
 - Lown-Ganong-Levine variant 193, 202, 247, 250
 - with multiple accessory pathways 203, 250
 - pseudoinfarction pattern 61, 62
 - syndrome *see* Wolff-Parkinson-White syndrome
 - vs.* left bundle branch block 129, 233–4
- premature atrial contractions (PACs) 19–20
 - with aberrant conduction 29
 - anterior ischemia or infarction 178, 245
 - blocked 19, 20, 165, 242
- premature ventricular contractions (PVCs) 28–30
 - atrial fibrillation 74, 219
 - congestive heart failure 192, 247
 - first-degree AV block and 167, 242–3
 - left atrial abnormality and 149, 238–9
 - mitral regurgitation 87, 222
 - previous myocardial infarction and 138, 236
- Prinzmetal’s angina 55
- procainamide 26
- protocol, ECG reading 3, 4
- PRWP *see* poor R wave progression
- psychiatric patient 179, 245
- pulmonary edema
 - atrial fibrillation 92, 223
 - atrial flutter 124, 232
 - chest pain and 199, 249
 - left atrial abnormality 38

- pulmonary embolism
atrial fibrillation 146, 238
atrial flutter 23
- pulmonary hypertension 46
- pulse
irregular 125, 165, 193
rapid 70
- PVCs *see* premature ventricular contractions
- Q wave 8, 58–62
atrial flutter and 124, 232
borderline 169, 243
false positive 61, 62
inferior 43
insignificant 69, 217
small 148, 149, 238–9
myocardial infarction *see* ST elevation
myocardial infarction
normal ECG 164, 242
septal 41, 42, 119, 231
U wave and 118, 231
- QRS axis 33–5
fascicular blocks 43
- QRS complex 6, 8–9
complete heart block 17
drugs/metabolic conditions affecting 10
duration (interval) 8–9, 38
high voltage, supraventricular tachycardia 96, 225
isoelectric deflections 33, 47
left bundle branch block 41
left ventricular hypertrophy 44, 45
low voltage *see* low QRS voltage
Mobitz I block 14–15
Mobitz II block 15
nodal rhythm 22
paroxysmal supraventricular tachycardia 21
premature atrial contractions 19
premature ventricular contractions 28
right bundle branch block 39
torsade de pointes 30
transition from negative to positive 46, 47
Wolff-Parkinson-White syndrome 24, 25, 26
see also narrow complex tachycardia; wide complex tachycardia
- QT interval 9–10
corrected (QTc) 9
- QT interval prolongation 10
after thrombolytic therapy 103, 227
anterior ischemia or infarction 178, 245
anterolateral myocardial infarction 102, 226–7
antihistamine/erythromycin combination 106, 107, 228
atrial flutter and 172, 243
biatrial abnormality and 204, 250
digitalis effect 136, 235
drugs/metabolic conditions causing 10, 31
intracranial bleeding 196, 248
left atrial abnormality and 77, 220
left bundle branch block and 94, 120, 224, 231
nodal rhythm and 87, 222–3
nodal tachycardia and 210, 251
non-Q myocardial infarction and 152, 170, 239, 243
paroxysmal atrial fibrillation and 188, 246
psychiatric patient 179, 245
pulmonary edema and 199, 249
sinus bradycardia and 113, 229
torsade de pointes 31, 107, 228
- QTU interval prolongation 10
borderline ECG 160, 241
poor R wave progression and 81, 221
see also U wave
- R prime (R') 8
- R wave 8, 39
delayed or poor progression *see* poor R wave progression
- RAA *see* right atrial abnormality
- RAD *see* right axis deviation
- rales 207
- RBBB *see* right bundle branch block
- reentry 10, 20–2
premature ventricular contractions and 29
Wolff-Parkinson-White syndrome and 24, 25
- refractoriness 29
temporal dispersion of 10
- renal failure 175
- reperfusion therapy 60
6 hours after chest pain onset 184, 246
anterolateral myocardial infarction 102, 103, 226–7
cardiogenic shock 251
inferior myocardial infarction 221, 243
posterolateral myocardial infarction 237
small low-risk myocardial infarction 229
Wenckebach block and 173, 174, 244
see also angioplasty/stenting; thrombolytic therapy
- repolarization 6, 9–10
early *see* early repolarization
- rhythm 11–32
idioventricular 17–18, 211, 252

- nodal (or junctional) 22
- sinus 11, 64, 216
- see also* arrhythmias
- right atrial abnormality (RAA) 37, 39
- emphysema 85, 222
- right axis deviation (RAD)
 - anterior and inferior myocardial infarction 93, 224
 - Eisenmenger's syndrome 180, 245
 - left posterior fascicular block 43
 - obstructive lung disease 205, 250
 - right ventricular hypertrophy 46, 122, 139, 231–2, 236
- right bundle branch 6, 43
- right bundle branch block (RBBB) 38–41
 - anterior and inferior myocardial infarction and 93, 224
 - anterior ischemia/infarction and 178, 245
 - anterior myocardial infarction and 154, 195, 240, 248
 - anterolateral myocardial infarction and 126, 232–3
 - atrial flutter and 124, 232
 - bifascicular blocks 43
 - incomplete *see* incomplete right bundle branch block
 - left atrial abnormality and 77, 220
 - left ventricular hypertrophy and 99, 225–6
 - nodal rhythm and long QTc 87, 222–3
 - right ventricular hypertrophy 168, 243
 - ST elevation and 184, 246
 - ventricular pacing and 151, 239
- right coronary artery 49
- right ventricle (RV), strain pattern 46
- right ventricular hypertrophy (RVH) 46, **47**
 - atrial flutter or nodal rhythm 139, 236
 - chronic obstructive pulmonary disease 48, 168, 243
 - cor pulmonale 47
 - Eisenmenger's syndrome 180, 245
 - emphysema 122, 231–2
 - tricuspid regurgitation 84, 221–2
- RR interval 5, 7
 - variability 11–12
- RSR' pattern 39, 40
- RVH *see* right ventricular hypertrophy
- S wave 8, 39
- SB *see* sinus bradycardia
- sepsis 156, 240
- septal Q wave 41, 42, 119, 231
- sick sinus syndrome 27
- sinoatrial (SA) node 6, 7
 - testing of function 27
- sinus arrest, with junctional escape rhythm 212, 252
- sinus arrhythmia 11–12
 - Lown-Ganong-Levine syndrome 193, 247
- sinus bradycardia (SB) 11
 - after reperfusion therapy 174, 244
 - drugs/metabolic conditions causing **32**
 - inferior myocardial infarction and 141, 236
 - left bundle branch block and 150, 239
 - long QT and 113, 229
 - T wave inversion and 110, 228
- sinus rhythm 11, 64, 216
- sinus tachycardia (ST) 11
 - anterior ischemia or infarction and 178, 245
 - anterior myocardial infarction and 89, 223
 - AV sequential pacemaker 197, 248–9
 - baseline artifact with 156, 240
 - congestive heart failure 11, 123, 232
 - digitalis toxicity 127, 233
 - drugs/metabolic conditions causing **32**
 - Eisenmenger's syndrome 180, 245
 - emphysema 85, 222
 - hypertension 94, 224
 - inferior myocardial infarction and 147, 238
 - inferolateral myocardial infarction and 206, 250
 - ischemic cardiomyopathy 176, 244
 - left bundle branch block and 135, 235
 - left ventricular hypertrophy 175, 244
 - nonspecific ST-T wave changes with 66, 216
 - pericarditis vs. ischemia 194, 247–8
 - peri-infarction block and 195, 248
 - postinfarction ischemia 143, 237
- smoking 204, 236
- sotalol 246
- spironolactone 31, 234
- ST *see* sinus tachycardia
- ST depression 50–2, 53
 - after previous myocardial infarction 68, 217
 - left ventricular hypertrophy 44, **45**, 45
 - reciprocal 55, 56, 59
 - inferior myocardial infarction 147, 238
 - inferolateral myocardial infarction 206, 250
- ST elevation **50**, 54–7, 58
 - after coronary bypass surgery 190, 247
 - after thrombolytic therapy 103, 142, 227, 236–7
 - anterior and inferior myocardial infarction 209, 251
 - anterior ischemia or infarction 178, 245
 - anterolateral myocardial infarction 102, 226–7

- Brugada syndrome 115, 230
- early repolarization 55, 69, 217
- inferolateral ischemia or infarction 111, 229
- nonischemic causes 55
- pericarditis *vs.* ischemia 194, 247–8
- persisting after myocardial infarction 57, 89, 223
- right bundle branch block and 184, 246
- ST elevation (transmural or Q wave) myocardial infarction 50, 51, 54–7
 - borderline 56
 - evolution 58–60
 - Q waves 58–62
 - reperfusion therapy and 60
 - silent 61–2
 - small, low-risk 111, 229
 - thrombolytic therapy 142, 236–7
 - vs.* subendocardial infarction 54
- ST segment 6, 50
 - changes 48–57
 - global changes 50, 54
 - nonspecific changes *see* nonspecific ST-T wave changes
 - sagging *see* digitalis effect
- stenting *see* angioplasty/stenting
- strain pattern 44, 46
- stress test 238
 - positive 128, 233
 - ST depression 51, 52
- subaortic stenosis, idiopathic hypertrophic 121, 231
- subendocardial infarction *see* non-ST elevation myocardial infarction
- subendocardial ischemia 50, 51, 52, 53, 53
- sudden cardiac death 30, 108, 228
- supraventricular tachycardia (SVT) 96, 225
 - with aberrant conduction 29
 - left anterior fascicular block with 70, 218
 - paroxysmal *see* paroxysmal supraventricular tachycardia
 - sick sinus syndrome 27
 - vs.* ventricular tachycardia 24–6, 30
- SVT *see* supraventricular tachycardia
- syncope
 - antihistamine/erythromycin therapy 106, 228
 - Brugada syndrome 115, 230
 - complete heart block 13, 18
 - first degree AV and bifascicular block 72, 218–19
 - sick sinus syndrome 27
- T wave 6, 9–10
 - axis 35
 - global changes 50, 54
 - left ventricular hypertrophy 44, 45, 45
 - nonspecific changes *see* nonspecific ST-T wave changes
 - premature atrial contractions and 165, 242
 - tall peaked (hyperacute) 57, 58, 132, 234
- T wave inversion 50, 52–4
 - after reperfusion therapy 174, 244
 - Brugada syndrome 115, 230
 - inferolateral 145, 237–8
 - intracranial bleeding 196, 248
 - ischemia or non-Q myocardial infarction 90, 223
 - normal ECG 164, 193, 242, 247
 - sinus bradycardia and 110, 228
- tachycardia 7, 11
 - multifocal atrial *see* multifocal atrial tachycardia
 - narrow complex 21, 24, 25
 - nodal 210, 251
 - sinus *see* sinus tachycardia
 - supraventricular *see* supraventricular tachycardia
 - ventricular *see* ventricular tachycardia
 - wide complex *see* wide complex tachycardia
- temporal dispersion of refractoriness 10
- thiazide diuretics 223, 246
- thrombolytic therapy
 - anterolateral myocardial infarction 103, 227
 - cardiogenic shock 251
 - chest pain 78, 97, 220, 225
 - elderly patients 178, 187, 245, 246
 - exclusion of pericarditis and 194, 247–8
 - inferior myocardial infarction 142, 171, 236–7, 243
 - non-Q myocardial infarction 170, 243
 - postinfarction ischemia 143, 237
 - small low-risk myocardial infarction 229
 - see also* reperfusion therapy
- tissue plasminogen activator 103, 227
- torsade de pointes 30–1
 - antihistamine/erythromycin therapy 107, 228
 - drug-induced 31, 32
- transmural infarction *see* ST elevation myocardial infarction
- transmural ischemia 51, 53
- tricuspid regurgitation 84, 221–2
- tricyclic antidepressants 245
- U wave 10
 - borderline ECG 160, 241
 - poor R wave progression and 81, 221

- small inferior Qs and 118, 231
- urinary tract infection 210
- vagus nerve, heart rate variability and 11, 12
- vasovagal attacks 11
- vectorcardiogram 4
- ventricles
 - depolarization 6, 8–9, 33
 - repolarization 6, 9–10
- ventricular arrhythmias 28–32
- ventricular bigeminy 167, 242–3
- ventricular escape rhythm, complete heart block with 101, 226
- ventricular fibrillation (VF) 29, 30
 - cardiomyopathy 108, 228
 - drugs/metabolic conditions causing **32**
- ventricular hypertrophy 44–6
 - see also* left ventricular hypertrophy; right ventricular hypertrophy
- ventricular pacing
 - AV sequential pacemaker 109, 151, 228, 239
 - sinus tachycardia and 197, 248–9
- ventricular premature beats *see* premature ventricular contractions
- ventricular tachycardia (VT) 29, 30
 - with AV dissociation 30, 31
 - cardiomyopathy 108, 228
 - drugs/metabolic conditions causing **32**
 - paroxysmal 150, 239
 - polymorphic, torsade de pointes 107, 228
 - possible 133, 234–5
 - slow 211, 252
 - vs.* supraventricular tachycardia 24–6, 30
- ventricular triplets 29
- verapamil 247
- vision, blurred 127, 233
- voltage 4
- VT *see* ventricular tachycardia
- wandering atrial pacemaker 27–8, 131, 234
- warfarin 125, 245
- Wenckebach block *see* Mobitz I block
- Wenckebach phenomenon 14
- wide complex tachycardia 133, 234–5
 - paroxysmal 150, 239
 - ventricular *vs.* supraventricular 24–6, 30
 - Wolff-Parkinson-White syndrome 24, 25, 26
- Wolff-Parkinson-White (WPW) syndrome
 - 24–7, 95, 224–5
 - with multiple accessory pathways 203, 250
 - pseudoinfarction pattern 61, 62
 - vs.* left bundle branch block 129, 233–4

Notes