

CLINICAL PRACTICE

Acute Pulmonary Edema

Lorraine B. Ware, M.D., and Michael A. Matthay, M.D.

This Journal feature begins with a case vignette highlighting a common clinical problem. Evidence supporting various strategies is then presented, followed by a review of formal guidelines, when they exist. The article ends with the authors' clinical recommendations.

A 62-year-old man presents with a three-day history of progressive dyspnea, nonproductive cough, and low-grade fever. He had been hospitalized two years earlier for congestive heart failure. His blood pressure is 95/55 mm Hg, his heart rate 110 beats per minute, his temperature 37.9°C, and his oxygen saturation while breathing ambient air 86 percent. Chest auscultation reveals rales and rhonchi bilaterally. A chest radiograph shows bilateral pulmonary infiltrates consistent with pulmonary edema and borderline enlargement of the cardiac silhouette. How should this patient be evaluated to establish the cause of the acute pulmonary edema and to determine appropriate therapy?

THE CLINICAL PROBLEM

From the Division of Allergy, Pulmonary and Critical Care Medicine, Department of Medicine, Vanderbilt University School of Medicine, Nashville (L.B.W.); and the Departments of Medicine and Anesthesia and the Cardiovascular Research Institute, University of California, San Francisco, San Francisco (M.A.M.). Address reprint requests to Dr. Ware at the Division of Allergy, Pulmonary and Critical Care Medicine, Vanderbilt University School of Medicine, 1161 21st Ave. S., T1218 MCN, Nashville, TN 37232-2650.

N Engl J Med 2005;353:2788-96.
Copyright © 2005 Massachusetts Medical Society.

The following two fundamentally different types of pulmonary edema occur in humans: cardiogenic pulmonary edema (also termed hydrostatic or hemodynamic edema) and noncardiogenic pulmonary edema (also known as increased-permeability pulmonary edema, acute lung injury, or acute respiratory distress syndrome). Although they have distinct causes, cardiogenic and noncardiogenic pulmonary edema may be difficult to distinguish because of their similar clinical manifestations.

Knowledge of the cause of acute pulmonary edema has important implications for treatment. Patients with cardiogenic pulmonary edema typically are treated with diuretics and afterload reduction, although the underlying cause may require other treatment, including coronary revascularization.¹ Patients with noncardiogenic pulmonary edema who require mechanical ventilation should be ventilated with a low tidal volume (6 ml per kilogram of predicted body weight) and a plateau airway pressure less than 30 cm of water. This lung-protective strategy of ventilation reduces mortality in patients with acute lung injury.^{2,3} In addition, for patients with severe sepsis, recombinant activated protein C⁴ and low-dose hydrocortisone⁵ should be considered. Prompt diagnosis of the cause of acute pulmonary edema with the use of noninvasive methods, supplemented by catheterization of the pulmonary artery when there is diagnostic uncertainty, facilitates timely and appropriate treatment.

Accurate diagnosis of acute pulmonary edema requires an understanding of microvascular fluid exchange in the lung (Fig. 1). In the normal lung (Fig. 1A), fluid and protein leakage is thought to occur primarily through small gaps between capillary endothelial cells. Fluid and solutes that are filtered from the circulation into the alveolar interstitial space normally do not enter the alveoli because the alveolar epithelium is composed of very tight junctions. Rather, once the filtered fluid enters the alveolar interstitial space, it moves proximally into the peribronchovascular space. Under normal conditions the lymphatics remove most of this filtered fluid from the interstitium and return it to the systemic circulation. Movement of larger plasma proteins is restricted. The hydrostatic force for fluid filtration across the

lung microcirculation is approximately equal to the hydrostatic pressure in the pulmonary capillaries (Fig. 1A), which is partially offset by a protein osmotic pressure gradient.

A rapid increase in hydrostatic pressure in the pulmonary capillaries leading to increased transvascular fluid filtration is the hallmark of acute cardiogenic or volume-overload edema (Fig. 1B). Increased hydrostatic pressure in the pulmonary capillaries is usually due to elevated pulmonary venous pressure from increased left ventricular end-diastolic pressure and left atrial pressure. Mild elevations of left atrial pressure (18 to 25 mm Hg) cause edema in the perimicrovascular and peribronchovascular interstitial spaces.⁷ As left atrial pressure rises further (>25 mm Hg), edema fluid breaks through the lung epithelium, flooding the alveoli with protein-poor fluid⁷ (Fig. 1B).

By contrast, noncardiogenic pulmonary edema is caused by an increase in the vascular permeability of the lung, resulting in an increased flux of fluid and protein into the lung interstitium and air spaces (Fig. 1C). Noncardiogenic pulmonary edema has a high protein content because the vascular membrane is more permeable to the outward movement of plasma proteins. The net quantity of accumulated pulmonary edema is determined by the balance between the rate at which fluid is filtered into the lung⁷ and the rate at which fluid is removed from the air spaces and lung interstitium.⁶

STRATEGIES AND EVIDENCE

EVALUATION

History and Physical Examination

The presenting features of acute cardiogenic and noncardiogenic pulmonary edema are similar. Interstitial edema causes dyspnea and tachypnea. Alveolar flooding leads to arterial hypoxemia and may be associated with cough and expectoration of frothy edema fluid. The history should focus on determining the underlying clinical disorder that has led to pulmonary edema.⁸ Common causes of cardiogenic pulmonary edema include ischemia with or without myocardial infarction, exacerbation of chronic systolic or diastolic heart failure, and dysfunction of the mitral or aortic valve. Volume overload should also be considered. A typical history of paroxysmal nocturnal dyspnea or orthopnea suggests cardiogenic pulmonary edema. However, a silent myocardial infarction or occult

diastolic dysfunction may also manifest as acute pulmonary edema, with few clues provided by the history.⁹

In contrast, noncardiogenic pulmonary edema is associated primarily with other clinical disorders, including pneumonia, sepsis, aspiration of gastric contents, and major trauma associated with the administration of multiple blood-product transfusions.³ The history should focus on signs and symptoms of infection, a decrease in the level of consciousness associated with vomiting, trauma, and details of medications and ingestions. Unfortunately, the history is not always reliable in distinguishing cardiogenic from noncardiogenic pulmonary edema. For example, an acute myocardial infarction (suggesting cardiogenic edema) may be complicated by syncope or cardiac arrest with aspiration of gastric contents and noncardiogenic edema. Conversely, in patients with severe trauma or infection (suggesting noncardiogenic edema), fluid resuscitation may lead to volume overload and pulmonary edema from an increase in lung vascular hydrostatic pressure.

Patients with cardiogenic pulmonary edema often have an abnormal cardiac examination. Auscultation of an S₃ gallop is relatively specific for elevated left ventricular end-diastolic pressure and left ventricular dysfunction¹⁰⁻¹³ and suggests cardiogenic pulmonary edema.¹⁰⁻¹² The specificity of this finding is high (90 to 97 percent), but its sensitivity is low (9 to 51 percent).¹⁰⁻¹³ The wide range of sensitivity probably reflects the difficulty in clearly identifying an S₃ gallop on physical examination, a particular challenge in a critically ill patient in whom intrathoracic sounds created by mechanical ventilation interfere with auscultation.

Data are lacking on the sensitivity and specificity of other findings on examination for cardiogenic edema. A murmur consistent with valvular stenosis or regurgitation should raise suspicion for the diagnosis of cardiogenic edema. Elevated neck veins, an enlarged and tender liver, and peripheral edema suggest elevated central venous pressure. However, assessment of central venous pressure by physical examination in a critically ill patient can be difficult. Also, peripheral edema is not specific for left heart failure and may be associated with hepatic or renal insufficiency, right heart failure, or systemic infection. The lung examination is not helpful, since alveolar flooding from any cause will manifest as inspiratory crackles and often rhonchi. The abdominal, pelvic, and

rectal examinations are important. An intraabdominal crisis such as perforation of a viscus can cause acute lung injury with noncardiogenic edema, and patients who are mechanically ventilated may be unable to provide a history of abdominal symptoms. Patients with noncardiogenic edema often have warm extremities, even in the absence of sepsis, whereas patients with cardiogenic edema and poor cardiac output usually have cool extremities.

Laboratory Testing

Electrocardiographic findings may suggest myocardial ischemia or infarction. Elevated troponin levels may indicate damage to myocytes. However, elevated troponin levels can occur in patients with severe sepsis in the absence of evidence for an acute coronary syndrome.¹⁴⁻¹⁷ In a patient who is obtunded and has pulmonary edema of an unknown cause, measurement of electrolytes, the serum osmolality, and a toxicology screen may lead to the diagnosis of an unsuspected ingestion. Elevated levels of serum amylase and lipase suggest acute pancreatitis.

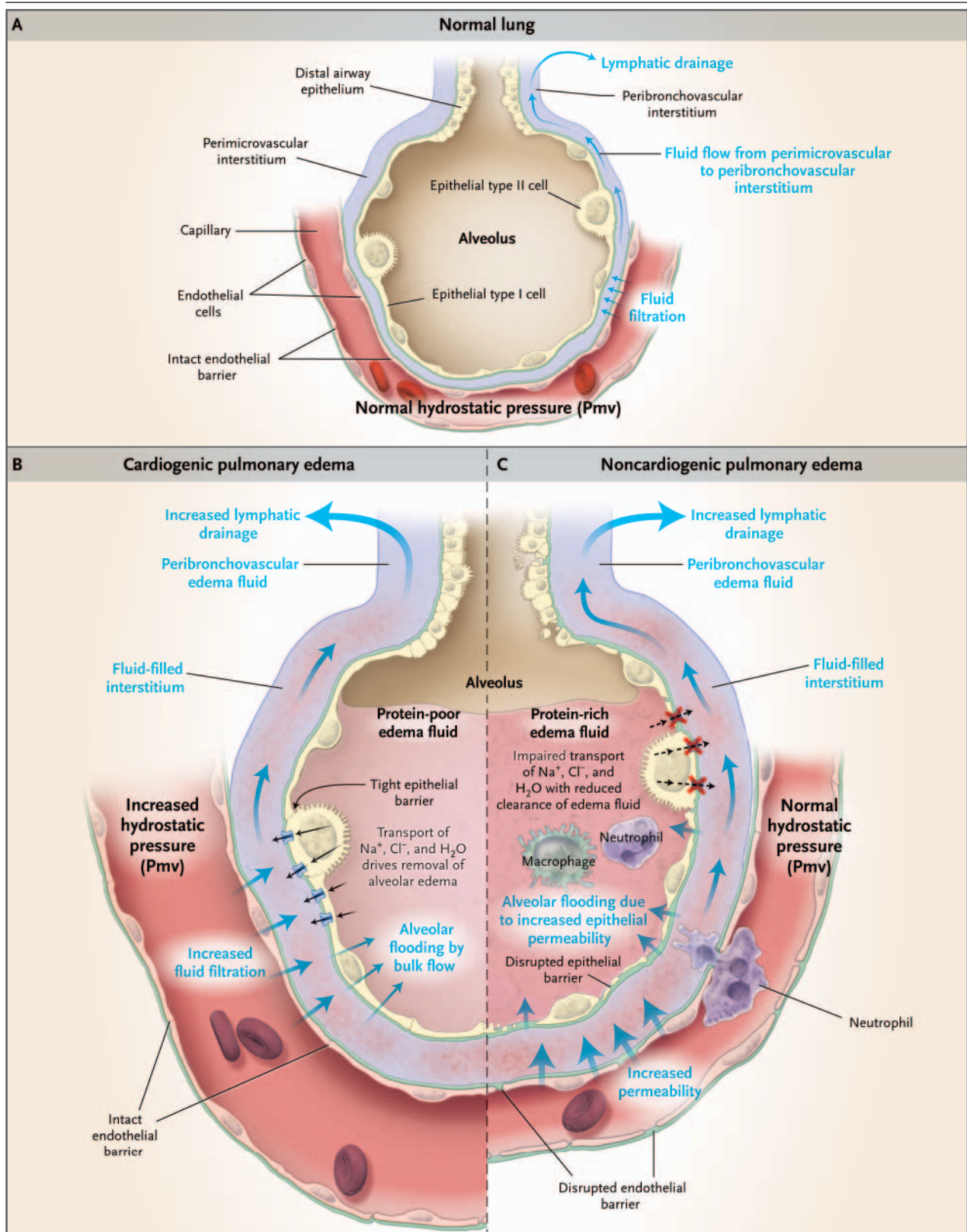
Plasma levels of brain natriuretic peptide (BNP) are often used in the evaluation of pulmonary edema. BNP is secreted predominantly by the cardiac ventricles in response to wall stretch or increased intracardiac pressures. In patients with congestive heart failure, plasma BNP levels correlate with left ventricular end-diastolic pressure¹⁸⁻²¹ and pulmonary-artery occlusion pressure.²² According to a consensus panel, a BNP level below 100 pg per milliliter indicates that heart failure is unlikely (negative predictive value, >90 percent), whereas a BNP level greater than 500 pg per milliliter indicates that heart failure is likely (positive predictive value, >90 percent).²³ However, BNP levels between 100 and 500 pg per milliliter provide inadequate diagnostic discrimination.

BNP levels must be interpreted with caution in critically ill patients, since the predictive value of BNP levels is uncertain in this group. Some reports indicate that BNP levels can be elevated in critically ill patients even in the absence of heart failure.^{24,25} Levels between 100 and 500 pg per milliliter are common in these patients.²⁶ In one report, all eight patients with sepsis with normal left ventricular function had BNP levels above 500 pg per milliliter.²⁷ Thus, measuring BNP is most useful in critically ill patients if the level is below 100 pg per milliliter. BNP levels are also higher in

Figure 1 (facing page). Physiology of Microvascular Fluid Exchange in the Lung.

In the normal lung (Panel A), fluid moves continuously outward from the vascular to the interstitial space according to the net difference between hydrostatic and protein osmotic pressures, as well as to the permeability of the capillary membrane. The following Starling equation for filtration of fluid across a semipermeable membrane describes the factors that determine the amount of fluid leaving the vascular space: $Q = K[(P_{mv} - P_{pmv}) - (\pi_{mv} - \pi_{pmv})]$, where Q is the net transvascular flow of fluid, K is the membrane permeability, P_{mv} is the hydrostatic pressure in the microvessels, P_{pmv} is the hydrostatic pressure in the perimicrovascular interstitium, π_{mv} is the plasma protein osmotic pressure in the circulation, and π_{pmv} is the protein osmotic pressure in the perimicrovascular interstitium. When hydrostatic pressure increases in the microcirculation, the rate of transvascular fluid filtration rises (Panel B). When lung interstitial pressure exceeds pleural pressure, fluid moves across the visceral pleura, creating pleural effusions. Since the permeability of the capillary endothelium remains normal, the filtered edema fluid leaving the circulation has a low protein content. The removal of edema fluid from the air spaces of the lung depends on active transport of sodium and chloride across the alveolar epithelial barrier. The primary sites of sodium and chloride reabsorption are the epithelial ion channels located on the apical membrane of alveolar epithelial type I and II cells and distal airway epithelia. Sodium is actively extruded into the interstitial space by means of the Na^+/K^+ -ATPase located on the basolateral membrane of type II cells. Water follows passively, probably through aquaporins, which are water channels that are found predominantly on alveolar epithelial type I cells.⁶ Noncardiogenic pulmonary edema (Panel C) occurs when the permeability of the microvascular membrane increases because of direct or indirect lung injury (including the acute respiratory distress syndrome), resulting in a marked increase in the amount of fluid and protein leaving the vascular space. Noncardiogenic pulmonary edema has a high protein content because the more permeable microvascular membrane has a reduced capacity to restrict the outward movement of larger molecules such as plasma proteins. The degree of alveolar flooding depends on the extent of interstitial edema, the presence or absence of injury to the alveolar epithelium, and the capacity of the alveolar epithelium to actively remove alveolar edema fluid. In edema due to acute lung injury, alveolar epithelial injury commonly causes a decrease in the capacity for the removal of alveolar fluid, delaying the resolution of pulmonary edema.⁶

patients with renal failure independent of heart failure, and a cutoff of below 200 pg per milliliter has been suggested to exclude heart failure when the estimated glomerular filtration rate is below 60 ml per minute.²³ BNP can also be secreted by



the right ventricle, and moderate elevations have been reported in patients with acute pulmonary embolism, cor pulmonale, and pulmonary hypertension.²³

Chest Radiography

The distinct mechanisms of cardiogenic and noncardiogenic pulmonary edema result in some moderately distinguishing findings on a posteroanterior or portable anteroposterior chest radiograph²⁸⁻³⁰ (Fig. 2). In a study of 45 patients with pulmonary edema in whom the cause was determined clinically and with the use of sampling of pulmonary edema fluid,³¹ a composite score based on the radiographic features in Table 1 correctly identified 87 percent of the patients who had cardiogenic edema and 60 percent of those who had noncardiogenic edema. A measurement of the width of the vascular pedicle may improve the diagnostic accuracy of the chest radiograph, but its utility in distinguishing cardiogenic from noncardiogenic edema needs further evaluation.³²

There are several explanations for the limited diagnostic accuracy of the chest radiograph. Edema may not be visible until the amount of lung water increases by 30 percent.³³ Also, any radiolucent material that fills the air spaces (such as alveolar hemorrhage, pus, and bronchoalveolar carcinoma) will produce a radiographic image similar to that of pulmonary edema. Technical issues can also reduce the sensitivity and specificity of the chest radiograph, including rotation, inspiration, positive-pressure ventilation, position of the patient, and underpenetration or overpenetration of the film. There is also substantial interobserver variability in the interpretation of radiographs.^{34,35}

Echocardiography

Bedside transthoracic echocardiography can evaluate myocardial and valvular function and can help identify the cause of pulmonary edema.³⁶ Among 49 critically ill patients with unexplained pulmonary edema or hypotension, evaluation of left ventricular function with the use of two-dimensional transthoracic echocardiography and data generated from a pulmonary-artery catheter were in agreement in 86 percent of patients.³⁷ These data, combined with other data from critically ill patients,³⁸ suggest that transthoracic echocardiography should be the first approach to assessing left ventricular and valvular function in patients in whom the history, physical and laboratory ex-

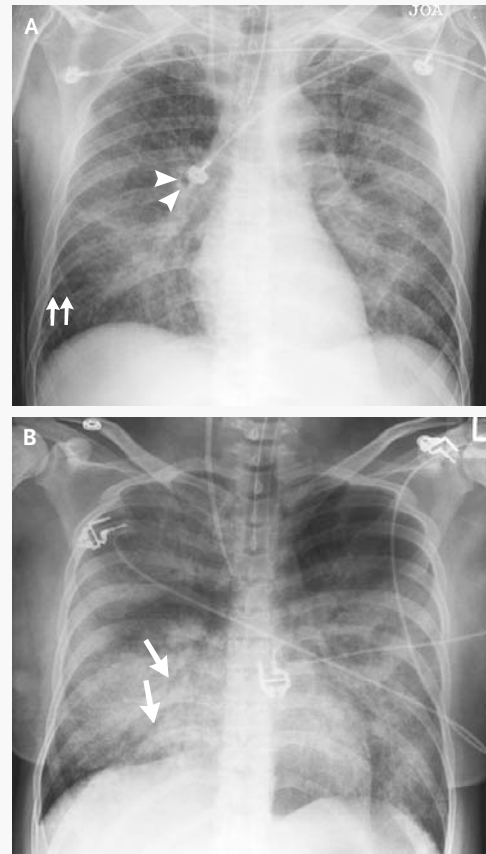


Figure 2. Representative Chest Radiographs from Patients with Cardiogenic and Noncardiogenic Pulmonary Edema.

Panel A shows an anteroposterior chest radiograph from a 51-year-old man who presented with acute anterior myocardial infarction and acute cardiogenic pulmonary edema. Note the enlargement of the peribronchovascular spaces (arrowheads) and the prominent septal lines (Kerley's B lines) (arrows) as well as acinar areas of increased opacity that coalesce into frank consolidations. The periphery is relatively spared, a common finding in cardiogenic edema.³¹ Panel B shows an anteroposterior chest radiograph from a 22-year-old woman whose blood culture was positive for *Streptococcus pneumoniae*, causing pneumonia complicated by septic shock and acute respiratory distress syndrome. Diffuse alveolar infiltrates appear patchy and bilateral with air bronchograms (arrows), findings that are characteristic of, but not specific for, noncardiogenic edema and acute lung injury.³¹ Although involved, the left upper lobe is relatively spared. There is no evidence of vascular engorgement or redistribution of pulmonary blood flow.

Table 1. Radiographic Features That May Help to Differentiate Cardiogenic from Noncardiogenic Pulmonary Edema.*

Radiographic Feature	Cardiogenic Edema	Noncardiogenic Edema
Heart size	Normal or greater than normal	Usually normal
Width of the vascular pedicle†	Normal or greater than normal	Usually normal or less than normal
Vascular distribution	Balanced or inverted	Normal or balanced
Distribution of edema	Even or central	Patchy or peripheral
Pleural effusions	Present	Not usually present
Peribronchial cuffing	Present	Not usually present
Septal lines	Present	Not usually present
Air bronchograms	Not usually present	Usually present

* Data are from Milne et al.²⁸ and Aberle et al.³¹

† The width of the vascular pedicle is determined by dropping a perpendicular line from the point at which the left subclavian artery exits the aortic arch and measuring across to the point at which the superior vena cava crosses the right mainstem bronchus. A vascular-pedicle width greater than 70 mm on a portable digital anteroposterior radiograph of the chest when the patient is supine is optimal for differentiating high from normal-to-low intravascular volume.³²

aminations, and the chest radiograph do not establish the cause of pulmonary edema. In some critically ill patients the transthoracic echocardiogram may not be sufficiently informative.³⁹ Alternatively, transesophageal echocardiography may be useful,⁴⁰ with rates of adverse events such as oropharyngeal bleeding, hypotension related to sedation, arrhythmias, and dislodgment of feeding tubes reported to be 1 percent to 5 percent in critically ill patients.⁴¹

Although echocardiography is effective in identifying left ventricular systolic dysfunction and valvular dysfunction, it is less sensitive in identifying diastolic dysfunction.⁴² Thus, a normal echocardiogram by standard methods does not rule out cardiogenic pulmonary edema. Newer echocardiographic techniques such as tissue Doppler imaging of the mitral-valve annulus may be used to determine left ventricular end-diastolic pressure and to assess diastolic dysfunction.⁴³

Pulmonary-Artery Catheterization

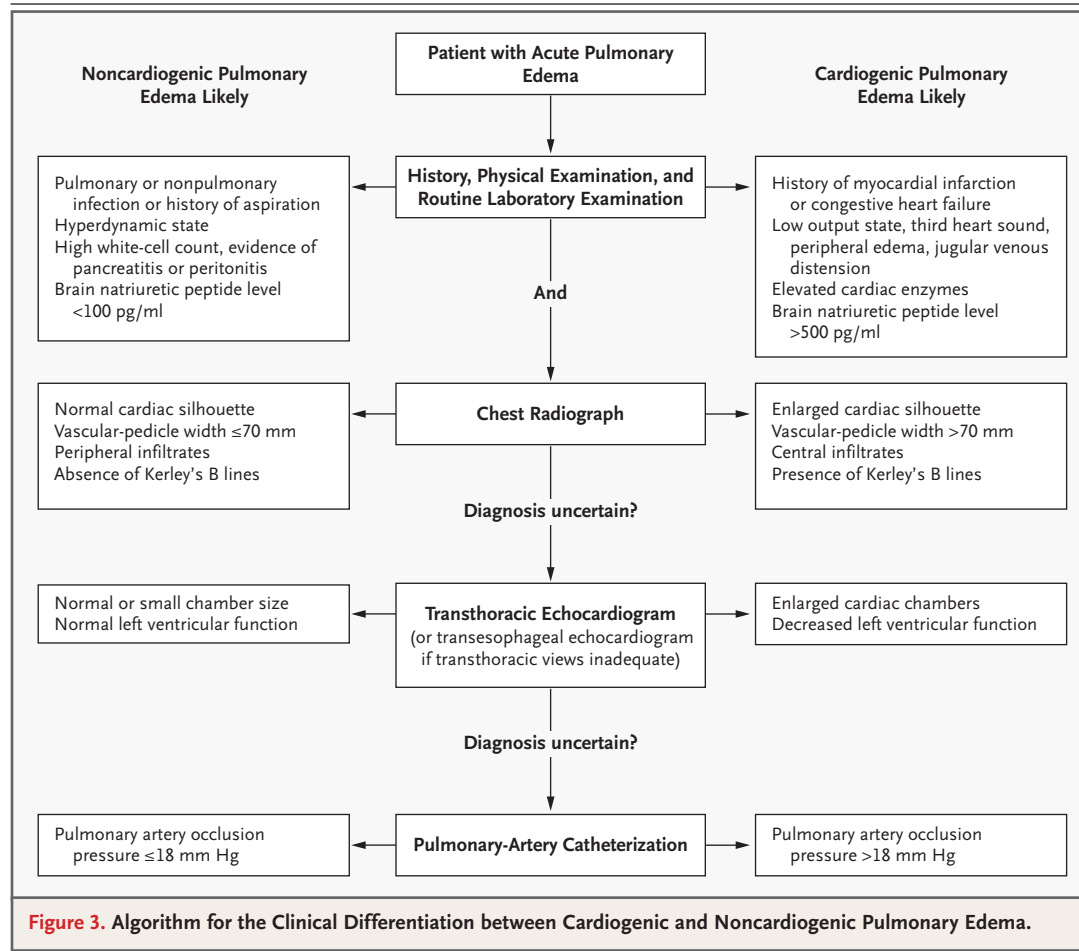
Pulmonary-artery catheterization, used to assess the pulmonary-artery occlusion pressure, is considered the gold standard for determining the cause of acute pulmonary edema.⁴⁴ Pulmonary-artery catheterization also permits monitoring of cardiac filling pressures, cardiac output, and systemic vascular resistance during treatment.

A pulmonary-artery occlusion pressure above 18 mm Hg indicates cardiogenic pulmonary edema or pulmonary edema due to volume overload.

In two recent, large, randomized trials of pulmonary-artery catheterization for the management of heart failure or critical illness, the rate of adverse events was 4.5 to 9.5 percent.^{45,46} Common complications included hematoma at the insertion site, arterial puncture, bleeding, arrhythmias, and bloodstream infection; there were no fatalities. Measurement of central venous pressure should not be considered a valid substitute for pulmonary-artery catheterization, since available data suggest that there is often a poor correlation between the two.⁴⁴ Elevated central venous pressure may reflect acute or chronic pulmonary arterial hypertension and right ventricular overload in the absence of any increase in left atrial pressure.

STEPWISE APPROACH

Our algorithm for the diagnostic approach to the patient with pulmonary edema (Fig. 3) has not been validated but instead is based on our clinical experience and on data regarding the value of various clinical and laboratory findings for distinguishing the cause of pulmonary edema. Because the noninvasive approaches for diagnosis will inevitably lead to the misclassification of some patients, repeated and ongoing assessment is necessary. Although the presentation of the algorithm is stepwise, providing care to the critically ill patient is a dynamic process, often requiring simultaneous diagnosis and treatment. Thus, some treatments (such as diuretic therapy for suspected cardiogenic edema, in the absence of a contrain-



dication) may be initiated empirically before testing (e.g., echocardiography) takes place. In addition, perhaps 10 percent of patients with acute pulmonary edema have multiple causes of edema.^{47,48} For example, a patient with septic shock and acute lung injury may have volume overload due to aggressive fluid resuscitation or myocardial dysfunction, and a patient with acute exacerbation of congestive heart failure may have pneumonia and associated acute lung injury.⁴⁹ In patients with an uncertain cause or possible multiple causes of edema, insertion of a pulmonary-artery catheter may be necessary.

AREAS OF UNCERTAINTY

We know of no prospective clinical studies that have assessed the relative contribution of the diagnostic methods currently in use for determining the cause of pulmonary edema. In one study that compared pulmonary-artery catheterization

with clinical assessment by physicians, catheterization was superior for determining the cause of acute pulmonary edema.⁵⁰ However, that study predated the routine use of BNP and echocardiography, both of which are likely to increase the sensitivity and specificity of the noninvasive determination of the cause of pulmonary edema.

GUIDELINES

There are currently no published guidelines from professional societies for the differentiation between cardiogenic and noncardiogenic pulmonary edema.

CONCLUSIONS AND RECOMMENDATIONS

For patients presenting with acute pulmonary edema, such as the one described in the vignette, evaluation should begin with a careful history and

physical examination. Special attention should be paid to signs and symptoms of acute or chronic cardiac disease, as well as evidence for a primary pulmonary process such as pneumonia or a non-pulmonary source of infection such as peritonitis. An electrocardiogram should be obtained to rule out ischemic changes, although such changes alone would not establish that the pulmonary edema was cardiogenic. Measurement of plasma BNP is warranted and is most useful if the value is below 100 pg per milliliter, a level at which congestive heart failure is unlikely. The chest radiograph should be reviewed with attention to features suggesting cardiogenic edema (e.g., increased heart size and central distribution of edema) as opposed to noncardiogenic edema. If the diagnosis remains uncertain, a transthoracic echocardiogram can evaluate left ventricular systolic function and aortic- and mitral-valve function.

With the use of the stepwise approach in the

diagnostic algorithm, the majority of patients with acute pulmonary edema will be diagnosed non-invasively, and treatment can be provided while the diagnostic steps are taken. For example, if infection is suspected, antibiotic therapy should be initiated after obtaining appropriate cultures. Similarly, if the patient requires mechanical ventilation, and there is uncertainty about the cause of the pulmonary edema, then a lung-protective strategy of ventilation with a low tidal volume is recommended. In some patients, particularly those in whom shock complicates the pulmonary edema, insertion of a pulmonary-artery catheter is needed to identify the cause of the pulmonary edema and target therapy appropriately.

Supported by grants from the National Heart, Lung, and Blood Institute (NHLBI HL51856 and HL74005, to Dr. Matthay; and NHLBI 70521 and 081332, to Dr. Ware).

No potential conflict of interest relevant to this article was reported.

REFERENCES

- Jessup M, Brozena S. Heart failure. *N Engl J Med* 2003;348:2007-18.
- The Acute Respiratory Distress Syndrome Network. Ventilation with lower tidal volumes as compared with traditional tidal volumes for acute lung injury and the acute respiratory distress syndrome. *N Engl J Med* 2000;342:1301-8.
- Ware LB, Matthay MA. The acute respiratory distress syndrome. *N Engl J Med* 2000;342:1334-49.
- Bernard GR, Vincent J-L, Laterre P-F, et al. Efficacy and safety of recombinant human activated protein C for severe sepsis. *N Engl J Med* 2001;344:699-709.
- Anname D, Sebillé V, Charpentier C, et al. Effect of treatment with low doses of hydrocortisone and fludrocortisone on mortality in patients with septic shock. *JAMA* 2002;288:862-71.
- Matthay MA, Folkesson HG, Clerici C. Lung epithelial fluid transport and the resolution of pulmonary edema. *Physiol Rev* 2002;82:569-600.
- Staub NC. Pulmonary edema. *Physiol Rev* 1974;54:678-811.
- Sibbald WJ, Cunningham DR, Chin DN. Non-cardiac or cardiac pulmonary edema? A practical approach to clinical differentiation in critically ill patients. *Chest* 1983;84:452-61.
- Graham SP, Vetrovec GW. Comparison of angiographic findings and demographic variables in patients with coronary artery disease presenting with acute pulmonary edema versus those presenting with chest pain. *Am J Cardiol* 1991;68:1614-8.
- Shah PM, Gramiak R, Kramer DH, Yu PN. Determinants of atrial (S4) and ventricular (S3) gallop sounds in primary myocardial disease. *N Engl J Med* 1968;278:753-8.
- Patel R, Bushnell DL, Sobotka PA. Implications of an audible third heart sound in evaluating cardiac function. *West J Med* 1993;158:606-9.
- Rihal CS, Davis KB, Kennedy JW, Gersh BJ. The utility of clinical, electrocardiographic, and roentgenographic variables in the prediction of left ventricular function. *Am J Cardiol* 1995;75:220-3.
- Marcus GM, Gerber IL, McKeown BH, et al. Association between phonocardiographic third and fourth heart sounds and objective measures of left ventricular function. *JAMA* 2005;293:2238-44.
- Ammann P, Fehr T, Minder EI, Gunter C, Bertel O. Elevation of troponin I in sepsis and septic shock. *Intensive Care Med* 2001;27:965-9.
- ver Elst KM, Spapen HD, Nguyen DN, Garbar C, Huyghens LP, Gorus FK. Cardiac troponins I and T are biological markers of left ventricular dysfunction in septic shock. *Clin Chem* 2000;46:650-7.
- Arlati S, Brenna S, Prencipe L, et al. Myocardial necrosis in ICU patients with acute non-cardiac disease: a prospective study. *Intensive Care Med* 2000;26:31-7.
- Spies C, Haude V, Fitzner R, et al. Serum cardiac troponin T as a prognostic marker in early sepsis. *Chest* 1998;113:1055-63.
- Maisel AS, Krishnaswamy P, Nowak RM, et al. Rapid measurement of B-type natriuretic peptide in the emergency diagnosis of heart failure. *N Engl J Med* 2002;347:161-7.
- Maisel AS, Koon J, Krishnaswamy P, et al. Utility of B-natriuretic peptide as a rapid, point-of-care test for screening patients undergoing echocardiography to determine left ventricular dysfunction. *Am Heart J* 2001;141:367-74.
- Omland T, Aakvaag A, Bonarjee VV, et al. Plasma brain natriuretic peptide as an indicator of left ventricular systolic function and long-term survival after acute myocardial infarction: comparison with plasma atrial natriuretic peptide and N-terminal proatrial natriuretic peptide. *Circulation* 1996;93:1963-9.
- Krishnaswamy P, Lubien E, Clopton P, et al. Utility of B-natriuretic peptide levels in identifying patients with left ventricular systolic or diastolic dysfunction. *Am J Med* 2001;111:274-9.
- Kazanegra R, Cheng V, Garcia A, et al. A rapid test for B-type natriuretic peptide correlates with falling wedge pressures in patients treated for decompensated heart failure: a pilot study. *J Card Fail* 2001;7:21-9.
- Silver MA, Maisel A, Yancy CW, et al. BNP Consensus Panel 2004: a clinical approach for the diagnostic, prognostic, screening, treatment monitoring, and therapeutic roles of natriuretic peptides in cardiovascular diseases. *Congest Heart Fail* 2004;10:Suppl 3:1-30.
- Tung RH, Garcia C, Morss AM, et al. Utility of B-type natriuretic peptide for the evaluation of intensive care unit shock. *Crit Care Med* 2004;32:1643-7.
- Maeder M, Ammann P, Rickli H, Diethelm M. Elevation of B-type natriuretic peptide levels in acute respiratory distress syndrome. *Swiss Med Wkly* 2003;133:515-8.
- Jefic D, Lee JW, Jefic D, Savoy-Moore

- RT, Rosman HS. Utility of B-type natriuretic peptide and N-terminal pro B-type natriuretic peptide in evaluation of respiratory failure in critically ill patients. *Chest* 2005;128:288-95.
27. Maeder M, Ammann P, Kiowski W, Rickli H. B-type natriuretic peptide in patients with sepsis and preserved left ventricular ejection fraction. *Eur J Heart Fail* (in press).
28. Milne EN, Pistolesi M, Miniati M, Guntini C. The radiologic distinction of cardiogenic and noncardiogenic edema. *AJR Am J Roentgenol* 1985;144:879-94.
29. Miniati M, Pistolesi M, Paoletti P, et al. Objective radiographic criteria to differentiate cardiac, renal, and injury lung edema. *Invest Radiol* 1988;23:433-40.
30. Pistolesi M, Miniati M, Milne EN, Guntini C. The chest roentgenogram in pulmonary edema. *Clin Chest Med* 1985;6:315-44.
31. Aberle DR, Wiener-Kronish JP, Webb WR, Matthay MA. Hydrostatic versus increased permeability pulmonary edema: diagnosis based on radiographic criteria in critically ill patients. *Radiology* 1988;168:73-9.
32. Ely EW, Haponik EF. Using the chest radiograph to determine intravascular volume status: the role of vascular pedicle width. *Chest* 2002;121:942-50.
33. Pistolesi M, Guntini C. Assessment of extravascular lung water. *Radiol Clin North Am* 1978;16:551-74.
34. Rubenfeld GD, Caldwell E, Granton J, Hudson LD, Matthay MA. Interobserver variability in applying a radiographic definition for ARDS. *Chest* 1999;116:1347-53.
35. Meade MO, Cook RJ, Guyatt GH, et al. Interobserver variation in interpreting chest radiographs for the diagnosis of acute respiratory distress syndrome. *Am J Respir Crit Care Med* 2000;161:85-90.
36. Duane PG, Colice GL. Impact of non-invasive studies to distinguish volume overload from ARDS in acutely ill patients with pulmonary edema: analysis of the medical literature from 1966 to 1998. *Chest* 2000;118:1709-17.
37. Kaul S, Stratienko AA, Pollock SG, Marieb MA, Keller MW, Sabia PJ. Value of two-dimensional echocardiography for determining the basis of hemodynamic compromise in critically ill patients: a prospective study. *J Am Soc Echocardiogr* 1994;7:598-606.
38. Cheitlin MD, Armstrong WF, Aurigemma GP, et al. ACC/AHA/ASE 2003 guideline update for the clinical application of echocardiography: a report of the American College of Cardiology/American Heart Association Task Force on Practice Guidelines. (Accessed December 5, 2005, at <http://www.acc.org/clinical/guidelines/echo/index.pdf>.)
39. Cook CH, Praba AC, Beery PR, Martin LC. Transthoracic echocardiography is not cost-effective in critically ill surgical patients. *J Trauma* 2002;52:280-4.
40. Poelaert JI, Trouerbach J, De Buyzere M, Everaert J, Colardyn FA. Evaluation of transesophageal echocardiography as a diagnostic and therapeutic aid in a critical care setting. *Chest* 1995;107:774-9.
41. Huttemann E, Schelenz C, Kara F, Chatzinikolaou K, Reinhart K. The use and safety of transoesophageal echocardiography in the general ICU — a minireview. *Acta Anaesthesiol Scand* 2004;48:827-36.
42. Aurigemma GP, Gaasch WH. Diastolic heart failure. *N Engl J Med* 2004;351:1097-105.
43. Nagueh SF, Kopelen HA, Zoghbi WA. Feasibility and accuracy of Doppler echocardiographic estimation of pulmonary artery occlusive pressure in the intensive care unit. *Am J Cardiol* 1995;75:1256-62.
44. Swan HJ, Ganz W, Forrester J, Marcus H, Diamond G, Chonette D. Catheterization of the heart in man with use of a flow-directed balloon-tipped catheter. *N Engl J Med* 1970;283:447-51.
45. Binanay C, Califf RM, Hasselblad V, et al. Evaluation study of congestive heart failure and pulmonary artery catheterization effectiveness: the ESCAPE trial. *JAMA* 2005;294:1625-33.
46. Harvey S, Harrison DA, Singer M, et al. Assessment of the clinical effectiveness of pulmonary artery catheters in management of patients in intensive care (PAC-Man): a randomised controlled trial. *Lancet* 2005;366:472-7.
47. Neff M, Rubenfeld G, Caldwell E, et al. Exclusion of patients with elevated pulmonary capillary wedge pressure from acute respiratory distress syndrome. *Am J Respir Crit Care Med* 1999;159:A716. abstract.
48. Ratnoff WD, Matthay MA, Wong MY, et al. Sulfidopeptide-leukotriene peptidases in pulmonary edema fluid from patients with the adult respiratory distress syndrome. *J Clin Immunol* 1988;8:250-8.
49. Zimmerman GA, Morris AH, Cengiz M. Cardiovascular alterations in the adult respiratory distress syndrome. *Am J Med* 1982;73:25-34.
50. Fein AM, Goldberg SK, Walkenstein MD, Dershaw B, Braitman L, Lippmann ML. Is pulmonary artery catheterization necessary for the diagnosis of pulmonary edema? *Am Rev Respir Dis* 1984;129:1006-9.

Copyright © 2005 Massachusetts Medical Society.

JOURNAL INDEX

The index to volume 353 of the *Journal* will be available on February 23, 2006. At that time, it can be downloaded free in PDF format from www.nejm.org.